



Life-threatening haemorrhage from a right superior phrenic artery pseudoaneurysm in a peritoneal dialysis patient

Hemorragia potencialmente mortal por pseudoaneurisma de la arteria frénica superior derecha en un paciente con diálisis peritoneal

Dear Editor,

Bleeding through a peritoneal catheter, although uncommon, can be quite dramatic and striking. The aetiology may vary from menstruation to more significant abdominal pathology such as sclerosing encapsulating peritonitis.¹ Moreover, hepatic intracystic bleeds in patients with Autosomal Dominant Polycystic Kidney Disease (ADPKD) are rarely life-threatening.²

We report a case of a 53 year old gentleman with ADPKD who presented to the Emergency Department in hypovolaemic shock with right shoulder pain and torrential bleeding through his peritoneal catheter. He had been on continuous ambulatory peritoneal dialysis (CAPD) for 30 months and was known to have multiple large cysts in both kidneys and the liver.

A contrast-enhanced CT scan showed a dense fluid area 25 mm in diameter, suggestive of a haematoma, around the

The patient required admission to a High Dependence Unit, received multiple red cell transfusions and empiric intraperitoneal antibiotics. He was initially managed conservatively. In fact, he was discharged back home, still on peritoneal dialysis, after ten days.

A few weeks later, the patient represented to the Emergency Department with haemorrhage through his peritoneal catheter once again. He was switched to haemodialysis via a right jugular tunnelled haemodialysis line.

A dedicated CT scan of the liver showed new haematomas forming around the liver, and a 1.5 cm pseudoaneurysm at the subdiaphragmatic surface of segment VII of the liver (Fig. 1).

A subsequent angiogram done via a right femoral approach confirmed the presence of this pseudoaneurysm which was being supplied by the superior branch of the right phrenic artery. Embolisation coils were placed in the pseudoaneurysm sac and in its feeding artery (Fig. 2).

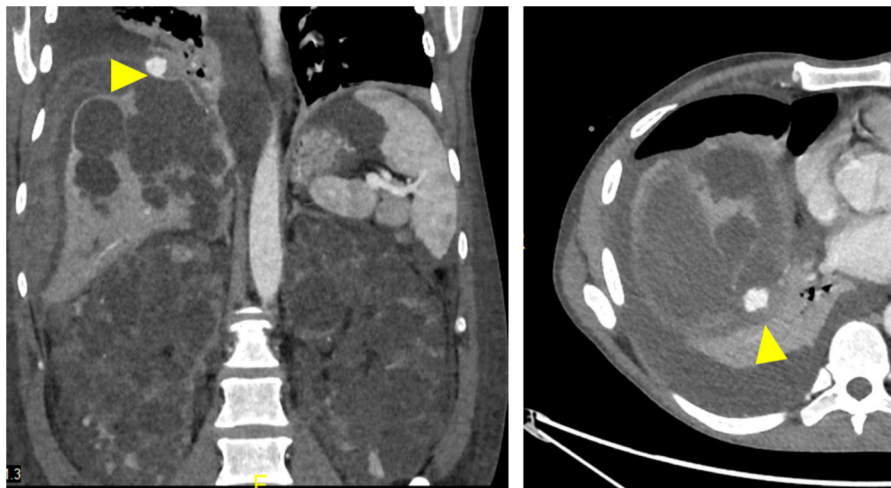


Fig. 1 – Coronal (left image) and axial (right image) CT angiography showing a large subcapsular pseudoaneurysm (yellow arrowhead) in the right lobe, posterior to the bare area of the liver. Note is made of enlarged polycystic kidneys, with significant hepatic involvement.

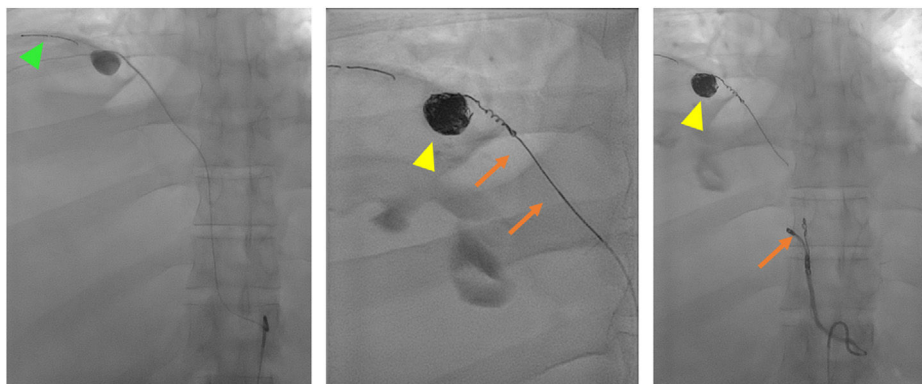


Fig. 2 – The microcatheter was advanced in the artery beyond the pseudoaneurysm sac using pushable coils (green arrowhead). Coils were deployed in the pseudoaneurysm sac (yellow arrowheads) and in the superior branch of the right phrenic artery (orange arrows).

Three days later, the peritoneal catheter was removed laparoscopically and a washout of the peritoneum, especially around the liver's surface, was done.

To our knowledge, this is the first reported case of a severe, life-threatening hepatic bleed resulting from a spontaneously formed pseudoaneurysm in the superior branch of the right phrenic artery. Hepatic artery aneurysms in ADPKD have been previously reported but not in the superior phrenic artery.³

The heavy bleeding through the peritoneal catheter and the fact that this happened in a patient with multiple, large cysts in the liver makes this clinical presentation even more unique.

The shoulder pain can be attributed to referred pain from the bleeding site, especially since the superior phrenic artery also supplies the diaphragm.

Twelve months have since passed from the initial presentation and the patient remains established on haemodialysis. No episodes of bleeding or abdominal and shoulder pains have been reported.

Authors' contributions

Julian Delicata was responsible for the conception and design of this write-up. Emanuel Farrugia was the lead clinician of this case. Elena Farrugia and Julian Delicata contributed to the patient's care as part of the nephrology team. Reuben Formosa and Elena Farrugia contributed to the literature review and write-up. Kelvin Cortis was the interventional radiologist involved in this case and provided the images found in this report.

All authors were involved in the final approval of this manuscript.

Funding

No funding was received.

Conflicts of interest

The authors have no conflicts of interest to declare.

BIBLIOGRAFÍA

1. Greenberg A, Bernardini J, Piraino BM, Johnston JR, Perlmutter JA. Hemoperitoneum complicating chronic peritoneal dialysis: single-center experience and literature review. *Am J Kidney Dis.* 1992;19:252-6.
2. Aussilhou B, Dokmak S, Dondero F, Joly D, Durand F, Soubrane O, et al. Treatment of polycystic liver disease. Update on the management. *J Visc Surg.* 2018;155:471-81.
3. Umetsu M, Akamatsu D, Goto H, Hashimoto M, Serizawa B, Tajima Y, et al. Successful treatment of giant common and proper hepatic artery aneurysm complicating autosomal dominant polycystic kidney disease. *Ann Vasc Surg.* 2022;83, 379.e1-e5.

Julian Delicata^{a,*}, Elena Farrugia^a, Reuben Formosa^b, Kelvin Cortis^c, Emanuel Farrugia^a

^a Department of Medicine, Nephrology Division, Mater Dei Hospital, Malta

^b Renal Unit, Mater Dei Hospital, Malta

^c Department of Radiology, Mater Dei Hospital, Malta

* Corresponding author.

E-mail addresses: julian.delicata@gov.mt, julian.delicata@gmail.com (J. Delicata).

0211-6995/© 2024 Sociedad Española de Nefrología. Published by Elsevier España, S.L.U. This is an open access article under the CC BY-NC-ND license (<http://creativecommons.org/licenses/by-nc-nd/4.0/>).

<https://doi.org/10.1016/j.nefro.2024.09.008>