

## Conflict of interest

All the authors of this article declare no conflict of interest.

## REFERENCES

1. Tarrass F, Benjelloun O, Meryem B. Towards zero liquid discharge in hemodialysis. Possible issues. *Nefrologia (Engl Ed)*. 2021. S0211 6995(21)00036-9.
2. Handbook for reusing or recycling reverse osmosis reject water from haemodialysis in healthcare facilities. <https://waterportal.com.au/swf/images/swf-files/62r-2056-handbook.pdf>.
3. Bendine G, Autin F, Fabre B, Bardin O, Rabasco F, Cabanel JM, et al. Haemodialysis therapy and sustainable growth: a corporate experience in France. *Nephrol Dial Transplant*. 2020;35:2154–60.

4. Barraclough KA, Agar JWM. Green nephrology. *Nat Rev Nephrol*. 2020;16:257–68.
5. Wieliczko M, Zawierucha J, Covic A, Prystacki T, Marcinkowski W, Małyszko J. Eco-dialysis: fashion or necessity. *Int Urol Nephrol*. 2020;52:519–23.

Mohammed Asserraji\*, Merouane Belarbi, Ahmed Amine Jawhar, Omar Maoujoud, Nadir Zemraoui

Nephrology Unit, Avicenne Military Hospital and Faculty of Medicine, Cadi Ayyad University, Marrakech 40000, Morocco

\*Corresponding author.

E-mail address: [asserrajimed@hotmail.com](mailto:asserrajimed@hotmail.com) (M. Asserraji).

2013-2514/© 2022 Published by Elsevier España, S.L.U. on behalf of Sociedad Española de Nefrología. This is an open access article under the CC BY-NC-ND license (<http://creativecommons.org/licenses/by-nc-nd/4.0/>). <https://doi.org/10.1016/j.nefro.2021.06.006>

# Fibrillary glomerulonephritis simulating glomerular basal antimembrane antibody disease with associated thrombotic microangiopathy and ANCAp

## Glomerulonefritis con depósitos fibrilares simulando enfermedad por anticuerpos antimembrana basal glomerular con microangiopatía trombótica asociada y ANCAp

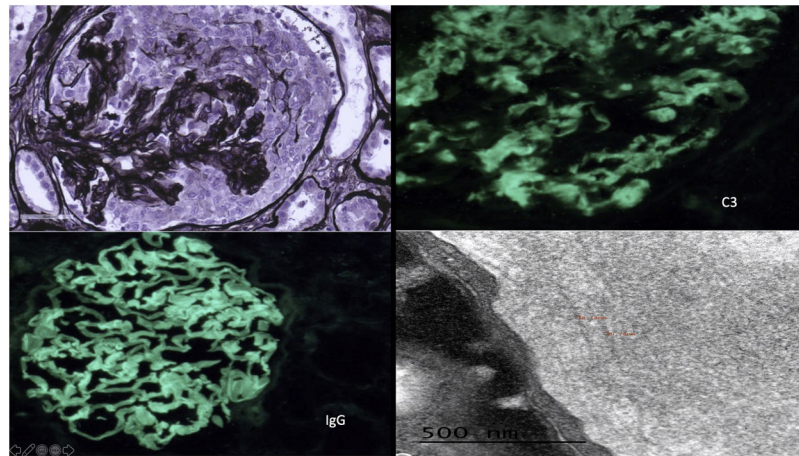
Mr. Director:

Fibrillary glomerulonephritis (FGN) is a glomerular disease with organized deposits of immunoglobulins, negative Congo red staining and 16–24 nm fibrils visible in electron microscopy (EM). The clinical syndrome in these patients is variable: nephritic or nephrotic syndrome, microhematuria, hypertension, renal failure and, rarely, rapidly progressive glomerulonephritis (RPG), pulmonary hemorrhage or thrombotic microangiopathy (TMA).<sup>1–6</sup> We describe a FGN, with RPG, pulmonary hemorrhage, and positive ANCAp and TMA.

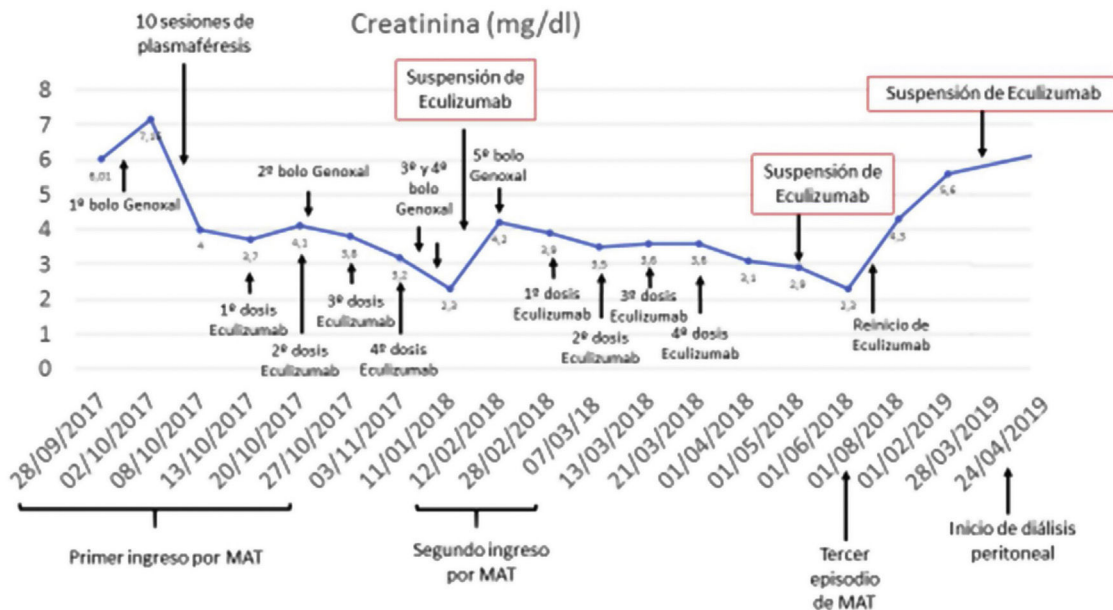
Female, 51 years old, with no relevant medical history, consults for dyspnea and edema. On examination, blood pressure 170/100 mmHg, sinus rhythm, crackles in both lung bases and edema. Hemogram and blood chemistry: normocytic normochromic anemia, without microangiopathic hemolytic anemia (MHA), creatinine 6 mg/dl, nephrotic proteinuria with normal serum albumin and microhematuria. Chest X-ray: bilateral interstitial infiltrate, with diagnosis of pulmonary hemorrhage with immunological study with ANCAp positive

1/320, rest normal/negative, including anti-glomerular basement membrane antibodies. Plasmapheresis, corticosteroids and intravenous cyclophosphamide were started. One week after admission, MHA with smear showing schistocytes and undetectable haptoglobin, with negative stool culture, normal ADAMTS13, we decided to start eculizumab treatment, with normal genetic follow-up Renal biopsy: 49 glomeruli, 10 sclerosed, 29 with epithelial crescents, some with segmental necrosis, PAS and Jones silver positive. No signs of TMA. Direct immunofluorescence was strongly positive for IgG with linear pattern, kappa and lambda positive, weak C3 with parietal and mesangial granular pattern, IgG4 positive (Fig. 1).

At hospital discharge, the patient presented remission of pulmonary hemorrhage and resolution of MHA, creatinine of 3.8 mg/dl, proteinuria and microhematuria, and continued treatment with cyclophosphamide, corticosteroids and eculizumab up to 2 months after resolution of MHA. Thirty days after discontinuation of eculizumab, she presented a new episode of probable TMA and the ME result was received: dense deposits, in glomerular basement membrane (GBM) and mesangium, consisting of random fibrils, with an average thickness of 18.41 nm, compatible with fibrillary glomerulopathy, with linear IgG deposits (Fig. 1).



**Fig. 1** – Upper left: glomerulus with circumferential epithelial crescent with disruption of the basement membrane and positive staining of the basals and mesangium. Jones silver  $\times 40$ . Upper right: mesangial granular and pseudolinear 2+ de C3 positivity. IFD C3  $\times 40$ . Lower left: linear/pseudolinear 3+ parietal IgG positivity. IFD IgG  $\times 40$ . Lower right: by EM, dense, banded and continuous deposits, linear in appearance, are observed along the lamina densa of the glomerular basement membranes and in the mesangium constituted by randomly arranged fibrils, whose mean thickness was 18.41 nm.



**Fig. 2**

DNAJB9 testing by immunohistochemistry was positive, and we restarted eculizumab, with suspicion of secondary TMA. After 6 months of cyclophosphamide, we maintained treatment with azathioprine. For 2.5 months, she presented clinical and renal function stability, with no MHA data; treatment with eculizumab was maintained for 3 months and subsequently renal function improved with no MHA data. Three months after discontinuation, the patient presented deterioration of renal function, and eculizumab was reinitiated until her inclusion in chronic treatment with peritoneal dialysis, 9 months later (Fig. 2).

Fibrillary glomerulonephritis rarely presents as it did in this case, with acute renal failure and pulmonary hemorrhage. Different authors suggest the possibility of a circulating

factor in GF, which may be responsible for the existence of fibrillar material at pulmonary level, triggering pulmonary hemorrhage.<sup>5</sup> For the diagnosis of FGN, EM is necessary, or DNAJB9 by immunohistochemistry if EM is not available. In our case, despite diagnosis made by EM, we tested for DNAJB9 with a positive result.<sup>7-9</sup> The linear/pseudolinear IgG deposits described in FGN and in our patient resembles a GBM antibody disease, which makes us rule out FGN when present or suggest coexistence.<sup>1,2</sup> The presence of RPG and TMA is rare, but may occur in FGN, even in association with GBMD.<sup>1,2,4,7</sup> In fact, Bircan et al. explain that the concurrence of these entities may be due to endothelial injury produced by vasculitis in patients with susceptibility due to FGN with factor H deficiency, triggering TMA in patient with vasculitis and FGN. In

our patient we ruled out susceptibility due to absence of factor H deficiency, but the 3 conditions coexisted: FGN, vasculitis, and TMA.<sup>10</sup> FGN probably associated with GBMD with ANCAp+ and TMA has not been previously described in the literature, to our knowledge.

## REFERENCES

- Nasr SH, Valeri AMFC, Fervenza FC. Fibrillary glomerulonephritis: a report of 66 cases from a single institution. *Clin J Am Soc Nephrol*. 2011;6:775–84.
- Husseini A, Aycinena JC, George B, Jennings S, Cornea V, Sawaya BP. Fibrillary glomerulonephritis masquerading as rapidly progressive glomerulonephritis with pseudo-linear glomerular basement membrane staining. *Clin Nephrol*. 2015;84:231–5.
- Cheungpasitporn W, Zacharek CC, Fervenza FC, Cornell LD, Sanjeev Sethi S, Herrera Hernández LP, et al. Rapidly progressive glomerulonephritis due to coexistent anti-glomerular basement membrane disease and fibrillary glomerulonephritis. *Clin Kid J*. 2016;9:97–101.
- Momose A, Nakajima T, Chiba S, Kumakawa K, Shiraiwa Y, Sasaki N, et al. A case of fibrillary glomerulonephritis associated with thrombotic microangiopathy and anti-glomerular basement membrane antibody. *Nephron Extra*. 2015;5:30–8.
- Masson RG, Rennke HG, Gottlieb MN. Pulmonary hemorrhage in a patient with fibrillary glomerulonephritis. *N Engl J Med*. 1992;326:36–9.
- Tsui C, Dokouhaki P, Prasad B. Fibrillary glomerulonephritis with crescentic and necrotizing glomerulonephritis and concurrent thrombotic microangiopathy. *Case Rep Nephrol Dial*. 2018;8:182–91.
- Nasr SH, Fogo AB. New developments in the diagnosis of fibrillary glomerulonephritis. *Kidney Int*. 2019;96:581–92.
- Nasr SH, Dasari S, Lieske JC, Benson LM, Vanderboom PM, Holtz-Heppelmann CJ, et al. Serum levels of DNAJB9 are elevated in fibrillary glomerulonephritis patients. *Kidney Int*. 2019;95:1269–72.
- Nasr SH, Vrana JA, Dasari S, Bridoux F, Fidler ME, Kaaki S, et al. DNAJB9 is a specific immunohistochemical marker for fibrillary glomerulonephritis. *Kidney Int Rep*. 2017;3:56–64.
- Bircan Z, Toprak D, Kilicaslan I, Solakoglu S, Uysal V, Ponard D, et al. Factor H deficiency and fibrillary glomerulopathy. *Nephrol Dial Transplant*. 2004;19:727–30.

M. Dolores Sánchez de la Nieta García<sup>a,\*</sup>,  
Lucía González López<sup>b</sup>, Paz Castro Fernández<sup>c</sup>,  
Minerva Arambarri Segura<sup>a</sup>, Alberto Martínez-Calero<sup>a</sup>,  
Marina Alonso Riaño<sup>d</sup>, Ana Sánchez-Fructuoso<sup>a</sup>

<sup>a</sup> Servicio de Nefrología, Hospital Universitario Clínico San Carlos, Madrid, Spain

<sup>b</sup> Servicio de Anatomía Patológica, Hospital General Universitario de Ciudad Real, Ciudad Real, Spain

<sup>c</sup> Servicio de Nefrología, Hospital General Universitario de Ciudad Real, Ciudad Real, Spain

<sup>d</sup> Servicio de Anatomía Patológica, Hospital Universitario 12 de Octubre, Madrid, Spain

\*Corresponding author.

E-mail address: [sanchezdelanieta@senefro.org](mailto:sanchezdelanieta@senefro.org)  
(M.D. Sánchez de la Nieta García).

2013-2514/© 2021 Sociedad Española de Nefrología. Published by Elsevier España, S.L.U. This is an open access article under the CC BY-NC-ND license (<http://creativecommons.org/licenses/by-nc-nd/4.0/>).  
<https://doi.org/10.1016/j.nefro.2023.05.015>

## Bilateral hip osteonecrosis and cholelithiasis after eculizumab discontinuation in atypical haemolytic uraemic syndrome

### Osteonecrosis bilateral de cadera y colelitiasis tras la interrupción de eculizumab en síndrome hemolítico uremico atípico

Dear Editor,

We describe the course of a boy with atypical haemolytic uraemic syndrome (aHUS) with no mutation in the complement system, who presented with two unusual extrarenal complications; osteonecrosis of both femoral heads and

cholelithiasis, resulting from a relapse of aHUS caused after suspending eculizumab treatment.

The case is an 8-year-old boy with a neonatal onset of aHUS with severe and multisystemic disease. By administering eculizumab, it was achieved full haematological and renal recovery.<sup>1</sup> He continued the treatment with eculizumab from the neonatal period to the age of three years and six months, and the disease was maintained in complete remission.

Exhaustive testing of all the known genes that could cause aHUS was carried out and no mutations were found. There-