

REFERENCES

1. Caccio SM, Chalmers R. Human cryptosporidiosis in Europe. *Clin Microbiol Infect.* 2016;22:471–80.
2. Zeier MG. A dance teacher with kidney–pancreas transplant and diarrhoea: what is the cause? *Nephrol Dial Transplant.* 2005;20:1759–61.
3. Weisnburger WR, Hutcheon OF, Yardey JH, Roche JC, Hillis WD, Charache P, et al. Cryptosporidiosis in an immunosuppressed renal-transplant recipient with IgA deficiency. *Am J Clin Pathol.* 1979;72:473–8.
4. Aulagnon F, Scemla A, DeWolf S, Legendre C, Zuber J. Diarrhea after kidney transplantation: a new look at frequent symptom. *Transplantation.* 2014;98:806–16.
5. Franco A, Rocamora N, Merino E, Paya A. Criptosporidiosis: una infección rara en el trasplante renal. *Nefrología.* 2006;26:753–4.
6. Krause I, Amir J, Dagan A, Behor J, Samra Z, Davidovits M. Cryptosporidiosis in children following solid organ transplantation. *Pediatr Infect Dis J.* 2012;31:1135–8.

Raquel Castellano Carrasco*, M. José Torres Sánchez, Francisco Javier de Teresa Alguacil, Antonio Osuna Ortega

Servicio de Nefrología, Hospital Universitario Virgen de las Nieves, Complejo Hospitalario Universitario de Granada, Granada, Spain

*Corresponding author.

E-mail address: raquelcc1987@gmail.com

(R. Castellano Carrasco).

2013-2514/© 2016 Sociedad Española de Nefrología. Published by Elsevier España, S.L.U. This is an open access article under the CC BY-NC-ND license (<http://creativecommons.org/licenses/by-nc-nd/4.0/>).

<http://dx.doi.org/10.1016/j.nefro.2017.05.004>

Cortical necrosis: An uncommon cause of acute renal failure with a very poor outcome[☆]

La necrosis cortical: una causa infrecuente de fracaso renal agudo pero con un pésimo pronóstico

Renal cortical necrosis (RCN) was first described in 1883 by Friedlander. It is an extremely rare cause of acute kidney injury and usually is irreversible.¹ It is more prevalent in developing countries with deficient health systems. Usually there is extensive involvement of the cortex, but sometimes it is localized affecting focal areas. Renal cortical necrosis is observed in 2 peaks of age; first is in early childhood due to perinatal factors, and the second in women of reproductive age due to obstetric causes. Of the non-obstetric causes in the adult population, the most frequent etiology is septic shock.²

Here we present a case of a female, 21 y.o. from Venezuela with no previous relevant medical history who came to the emergency room for a 24 h history of fever, headache, blurred vision and photophobia. Physical examination showed neck stiffness and petechia in upper extremities and abdomen. Cranial CT scan without relevant findings. Spinal tap showed biochemical changes compatible with bacterial meningitis. The severity of the clinical symptoms prompted admission to ICU. She developed a Waterhouse–Friedrichsen syndrome

with multiorgan involvement. Blood cultures demonstrate the presence of *Neisseria meningitidis* group B.

The patient developed acute renal failure that required renal replacement therapy with hemofiltration. At that time a possible cause of the acute renal failure was immune allergic interstitial nephritis because eosinophilia was present that may have been related with the antibiotic therapy; therefore, steroid were given but without response. It was observed that the urine sediment had a large number of dysmorphic red blood cells, red cell casts, proteinuria of 0.9 g/day and low circulating levels of complement (C3 50.9 mg/dl and C4 11.6 mg/dl). Blood tests of autoimmunity and serology were negatives. During ICU admission the patient had low urine output and required RRT.

After clinical improvement the patient was transferred to the nephrology ward and a renal biopsy was obtained; there were 20 glomeruli all of them obsolete with multiple foci of cortical necrosis of ischemic origin that did not involve the subcapsular area and did not extend to the deeper areas of the kidney (Fig. 1A). Furthermore. There

[☆] Please cite this article as: Rodríguez PM, Morales E, Sánchez Á., Milla M, Martínez MA, Praga M. La necrosis cortical: una causa infrecuente de fracaso renal agudo pero con un pésimo pronóstico. *Nefrología.* 2017;37:339–341.

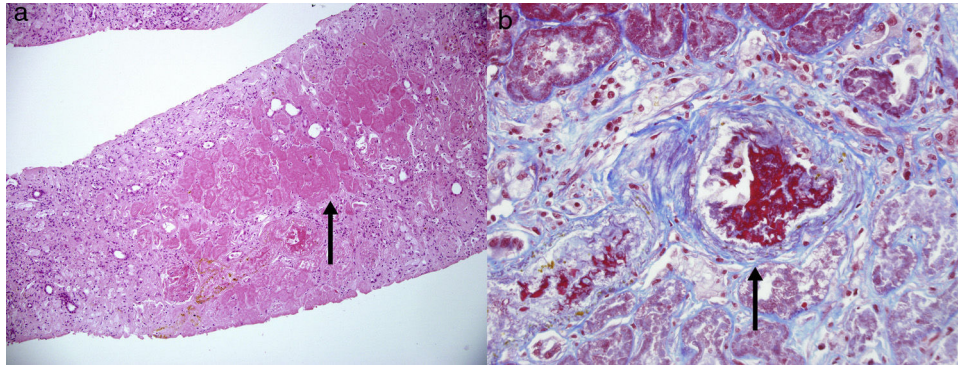


Fig. 1 Renal biopsy. (a) – Multiple cortical foci of ischemic necrosis that did not involve the subcapsular area and did not extend to the deeper areas of the kidney (arrow). (b) Arterial thrombi at different stages of organization with onion like growth of the intima of the arterial wall suggesting thrombotic microangiopathy (arrow).

were many arterial thrombi at different stages of organization with onion like growth of the arterial wall suggesting thrombotic microangiopathy (Fig. 1B). A doppler ultrasound confirmed the diagnosis of cortical necrosis. The patient did not recover renal function and remained on regular dialysis (Fig. 2).

Renal cortical necrosis is caused by the injury of that small arteries that supply blood to renal cortex. This arterial injury can be triggered by an endothelial lesion in a situation of severe renal ischemia or disseminated intravascular coagulation (DIC).³ In 1991, Chervu et al. reported the first two cases of meningococcal sepsis with renal cortical necrosis. Meningococcal sepsis is more frequent in young adults and it is associated to a high mortality. To improve the prognosis it is important to make the diagnosis soon so

treatment with antibiotics can be started early. The meningococcus, like other gram-bacteria, stimulates the release of cytokines that mediate vasodilatation, reduction of cardiac output, platelet aggregation and disseminated intravascular coagulation (DIC).

Waterhouse–Friderichsen Syndrome is an acute hemorrhagic necrosis of the suprarenal glands that in most cases is secondary to meningococcal sepsis. More than 75% of these patients develop a petechial rash. The treatment includes antibiotics and steroids. Plasma exchange has been used to remove bacterial endotoxin and cytokines such as TNF-alpha and interleukin-1. Agraharkar et al.⁴ reported a case of a 20 y.o. patient with meningococcal sepsis that received plasmapheresis during the first 24 h producing DIC improved and less requirement of vasopressors drugs.

In summary, renal cortical necrosis is not a frequent cause of acute kidney injury but it has a very bad outcome. The early diagnosis, with image and histology, may change the prognosis of the disease.

REFERENCES

1. Chervu I, Koss M, Campese VM. Bilateral renal cortical necrosis in two patients with *Neisseria meningitidis* sepsis. *Am J Nephrol.* 1991;11:411–5.
2. Prakash J, Vohra R, Wani IA, Murthy AS, Srivastva PK, Tripathi K, et al. Decreasing incidence of renal cortical necrosis in patients with acute renal failure in developing countries: a single-centre experience of 22 years from Eastern India. *Nephrol Dial Transplant.* 2007;22:1213–7.
3. Kennedy C, Khilji S, Dorman A, Walshe J. Bilateral renal cortical necrosis in meningococcal meningitis. *Case Rep Nephrol.* 2011;2011:1–3.
4. Agraharkar M, Fahlen M, Siddiqui M, Rajaraman S. Waterhouse-Friederichsen syndrome and bilateral renal cortical necrosis in meningococcal sepsis. *Am J Kidney Dis.* 2000;36:396–400.

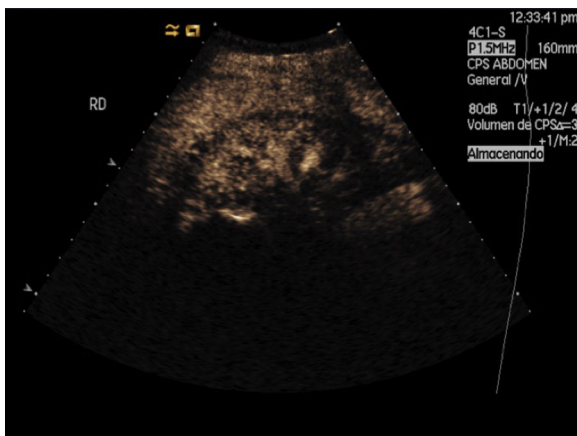


Fig. 2 – Doppler Ultrasound showing a 2–3 mm thick hypoecogenic halo diffuse and concentric marking the cortical; the rest including medullary pyramids and renal sinus is preserved.

Paola María Rodríguez, Enrique Morales*, Ángel Sánchez, Mónica Milla, Miguel Angel Martínez, Manuel Praga

Servicio de Nefrología, Hospital 12 de Octubre, Madrid, Spain

* Corresponding author.

E-mail address: emoralesr@senefro.org (E. Morales).

2013-2514/© 2016 Sociedad Española de Nefrología. Published by Elsevier España, S.L.U. This is an open access article under the CC BY-NC-ND license (<http://creativecommons.org/licenses/by-nc-nd/4.0/>).
<http://dx.doi.org/10.1016/j.nefro.2017.05.005>

Spontaneous tendon ruptures in chronic renal failure[☆]

Roturas tendinosas espontáneas en la insuficiencia renal crónica

Dear Editor,

Spontaneous rupture of tendons (STR) is not frequent. The pathogenesis is unclear but there are a number risk factors involved: secondary hyperparathyroidism (HPTH), diabetes mellitus, obesity, rheumatoid arthritis, gout, statins, steroids, fluorquinolones and the presence of B and/or C hepatitis virus. In patients with chronic renal failure (CKD) the most frequent cause of tendon rupture is secondary hyperparathyroidism, which is present in most of these patients.^{1,2}

There is no consensus about the treatment. Thus the objective of this study is to analyze the clinical features, risk factors, treatment and clinical evolution of STR in CKD patients.

The study includes end stage renal disease patients on renal replacement therapy that had STR during the years 1994 to 2013. Patients had a complete clinical history and they had a least one-year of follow up. Patient with tendon rupture caused by trauma or those with of the lost follow up were excluded.

There were six patients (0.23%) with STR. Mean age was 46.6 ± 11.8 years, 4 were males (66.7%). Before the episode of STR all patients had been on hemodialysis for an average of 9.1 ± 4.2 years. In 4 cases (66.7%) the STR affected the extremity of one body side and in 2 cases (33.3) they were bilateral.

In six patients there was a rupture of the femoral quadriceps tendon and in 2 cases the patellar tendon was affected. All patients had SHPT and one patient (16.6%) also receive statins to treat hypercholesterolemia (Table 1).

All patients underwent urgent (within 5 days) surgical intervention to repair the tendon fracture. In five cases the tendon was detached with respect to the patella and it was reinserted using nonabsorbable suture through transosseous tunnels in the patella. In 3 cases there was a rupture of the tendon and it had to be repaired by end-to-end suture with a

material that is not absorbable. Thereafter, the knee had to be immobilized for 8 weeks followed by a rehabilitation period of up to six months after surgery

With respect to the SHPT, all patients had bone pain and one patient (16.6%) complained of pruritus that was refractory to treatment. Mean serum concentration of PTH was 968 ± 308.2 pg/ml, the CaxP was 69.6 ± 17.6 and the mean value of alkaline phosphatase was 518.3 ± 334.4 UI/l. All patients underwent total parathyroidectomy after a mean period of 3.6 ± 1.7 months.

After 12.5 ± 5 year of follow up there was no further evidence of STR or SHPT and 4 patients (66.7%) underwent renal transplantation (Table 2).

The feature of a CKD patient with STR is a relatively young patient on hemodialysis for more that 5 years that may be malnourished, with insufficient dose of dialysis, amyloidosis, chronic acidosis and also SHPT which is the most important pathogenic factor for STR.¹⁻⁵ The pathophysiology is not totally clear; it has been proposed that the increased subperiosteal resorption together with elastosis of the connective tissue due to chronic acidosis may debilitate the osteotendinous junction favoring the STR.⁶⁻⁸

STR affecting extensor knee required urgent or immediate surgery, it has to be done within the first few days after rupture, so fibrosis and retraction of tendon and muscle are avoided. Optimal results require immobilization and 4–6 months of rehabilitation.⁹

In addition to the treatment of STR, it is necessary to control risk factors to prevent new STR. Therefore SHPT should be treated, the use of calcimimetics have markedly reduced the need for parathyroidectomy. In patients with STR and persistent hyperparathyroidism, parathyroidectomy is recommended.¹⁰

[☆] Please cite this article as: Ruiz J, Ríos A, Rodríguez JM, Llorente S. Roturas tendinosas espontáneas en la insuficiencia renal crónica. Nefrología. 2017;37:341–343.