



## Letters to the Editor

# Sustained severe intestinal edema after nafamostat mesilate-associated anaphylactic reaction during hemodialysis

## Edema intestinal grave y prolongado después de reacción anafiláctica relacionada con nafamostat mesilato durante la hemodiálisis

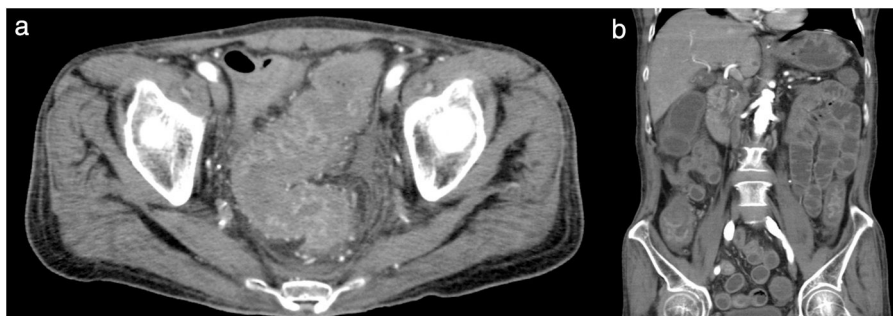
Dear Editor,

Anticoagulant use is essential to safe hemodialysis (HD) therapy because it prevents thrombosis in the extracorporeal circuit. For HD therapy in Japan, nafamostat mesilate (NM) is usually used during HD in patients with a tendency to bleed because of its short half-life.<sup>1</sup> However, NM use is reportedly associated with adverse effects, including hyperkalemia,<sup>2,3</sup> agranulocytosis,<sup>4</sup> and anaphylactic reaction.<sup>5,6</sup> A recent report indicated the development of anaphylactic shock in HD patients who received NM.<sup>6</sup> Here, we report a case of NM-associated anaphylactic reaction in a patient on HD, followed by severe intestinal edema.

A 64-year-old man with diabetes mellitus and a 5-year history of HD was admitted to our hospital for body-fluid status evaluation because of a recent episode of intradialytic hypotension at his dialysis facility. The intradialytic hypotension was suspected to be associated with ultrafiltration-induced hypovolemia during HD before admission. NM was used several times instead of heparin sodium for retinal bleeding complicated by diabetes mellitus in his dialysis facility. At our dialysis center, HD was performed in the same manner using NM. We carefully monitored for the occurrence of ultrafiltration-induced intradialytic hypotension. His blood pressure (BP) was 195/90 mmHg before HD but rapidly decreased to 114/56 mmHg. The arterial oxygen saturation measured by pulse oximetry (SpO<sub>2</sub>) was 88% with dyspnea and deterioration of consciousness shortly after the HD initiation. Based on the clinical course from before admission to this episode, intradialytic hypotension with NM-associated anaphylactic reaction was diagnosed. At a later date, specific immunoglobulin E (IgE) antibodies to NM were detected in his blood. The HD therapy was discontinued to avoid

further worsening of his systemic circulation. Although his BP recovered and his symptoms disappeared after HD was discontinued, he suffered from mild abdominal tenderness after the anaphylactic reaction; therefore, contrast computed tomography of the abdomen and pelvis was performed, which revealed remarkable mucosal edema at a circumference of the sigmoid colon (Fig. 1a) and along the entire intestine on a coronal view (Fig. 1b). During the next HD session using low-molecular-weight heparin, the intradialytic hypotension completely disappeared; thereafter, HD was safely performed. However, because the intestinal edema persisted on lower gastrointestinal endoscopy 2 weeks after the reaction, total parenteral nutrition instead of solid and liquid foods was necessary for approximately 3 weeks. Thereafter, he ate normally without worsening of the intestinal edema and fully recovered after 1 month of treatment.

An anaphylactic reaction usually occurs by an IgE-dependent immunologic mechanism and is commonly triggered by foods, stinging insect venom, and medications through acute onset within minutes to several hours. Furthermore, its reaction frequently increases vascular permeability, which increases the risk of death due to fluid extravasation with resultant sequential decreases in circulating blood volume, venous return, and BP.<sup>7</sup> Interestingly, the increase in vascular permeability induced by the anaphylactic reaction differs among systemic organs, and the extent of vascular permeability changes vary considerably among tissues: vascular permeability increases markedly in the trachea, moderately in the mesentery and intestines, and slightly in the other organs.<sup>8</sup> In this case, the whole-intestine edema associated with increased vascular permeability was surprisingly remarkable compared to other systemic organs in the NM-associated anaphylactic reaction, although the



**Fig. 1 – (a) Pelvic computed tomography scan at the level of the sigmoid colon. Remarkable mucosal edema was confirmed in the circumference of the sigmoid colon. (b) Abdominal and pelvic computed tomography scan (coronal view) showing severe whole-intestine edema.**

presence of tracheal edema might be suspected because of his respiratory distress and the SpO<sub>2</sub> decrease at the reaction's onset. In addition to the intestinal edema, it was interesting that improvement of the intestinal edema and dysfunction took several weeks. The reason for the difference between the rapid improvement of the circulating status and respiratory distress and the sustained gastrointestinal symptoms, including intestinal edema, in this case remains unclear. However, reports to date of the association between NM-associated anaphylactic reactions and remarkable intestinal edema are scarce. Therefore, this case report is relevant and showed that we should carefully monitor the systemic vascular permeability increase caused by the anaphylactic reaction, particularly in the intestine, in patients in whom NM is used during HD.

In Japan, the use of NM as an anticoagulant during blood purification is recommended in patients with various hemorrhagic complications as it has a lower risk of hemorrhage.<sup>1</sup> However, in patients with a history of NM-induced allergic reactions, low-molecular-weight heparin is usually administered instead of NM.<sup>5</sup> In this case, HD was performed without worsening of the retinal bleeding after switching to low-molecular-weight heparin. Furthermore, rinsing the dialysis circuit with heparin and albumin<sup>9</sup> and introducing a regional citrate infusion into the circuit<sup>10</sup> have recently shown good survival of the extra corporeal circuit without increasing the bleeding risk. Therefore, HD may have been better performed using these methods to avoid the occurrence of the NM-associated anaphylactic reaction.

In conclusion, our experience described here suggests that patients administered NM during HD because of hemorrhagic complications should be carefully observed for anaphylactic reaction including BP reduction, respiratory distress, and intestinal edema via increased vascular permeability.

### Conflicts of interest

The authors have no conflicts of interest to declare.

### Acknowledgement

We thank our hospital's dialysis staff members.

### REFERENCES

- Hirakata H, Nitta K, Inaba M, Shoji T, Fujii H, Kobayashi S, et al. Japanese Society for Dialysis therapy guidelines for management of cardiovascular diseases in patients on chronic hemodialysis. *Ther Apher Dial.* 2012;16:387–435.
- Muto S, Imai M, Asano Y. Mechanisms of hyperkalemia caused by nafamostat mesilate. *Gen Pharmacol.* 1995;26:1627–32.
- Ookawara S, Tabei K, Sakurai T, Sakairi Y, Furuya H, Asano Y. Additional mechanisms of nafamostat mesilate-associated hyperkalemia. *Eur J Clin Pharmacol.* 1995;51:149–51.
- Okada H, Suzuki H, Deguchi N, Saruta T, et al. Agranulocytosis in a haemodialysed patient induced by a proteinase inhibitor, nafamostat mesilate. *Nephrol Dial Transplant.* 1992;7:980.
- Higuchi N, Yamazaki H, Kikuchi H, Gejyo F. Anaphylactoid reaction induced by a proteinase inhibitor, nafamostat mesilate, following nine administrations in a hemodialysis patient. *Nephron.* 2000;86:400–1.
- Kim HS, Lee KE, Oh JH, Jung CS, Choi D, Kim Y, et al. Cardiac arrest caused by nafamostat mesilate. *Kidney Res Clin Pract.* 2016;35:187–9.
- Alvarez-Perea A, Tanno LK, Baeza ML. How to manage anaphylaxis in primary care. *Clin Trans Allergy.* 2017;7:45.
- Yang W, Shibamoto T, Kuda Y, Zhang T, Tanida M, Kurata Y.  $\beta_2$ -Adrenoceptor blockade deteriorates systemic anaphylaxis by enhancing hyperpermeability in anesthetized mice. *Allergy Asthma Immunol Res.* 2018;10:52–61.
- Kyrk T, Bechara A, Skagerlind M, Stegmayr B. Heparin and albumin as part of the priming solution limits exposure to anticoagulation during hemodialysis: in vitro studies. *Int J Artif Organs.* 2014;37:734–40.
- Singer RF, Williams O, Mercado C, Chen B, Talaulikar G, Walters G, et al. Regional citrate anticoagulation in hemodialysis: an observational study of safety, efficacy, and

effect on calcium balance during routine care. *Can J Kidney Health Dis.* 2016;3:22.

Mitsutoshi Shindo, Susumu Ookawara\*, Taisuke Kitano, Hiroki Ishii, Haruhisa Miyazawa, Kiyonori Ito, Yuichiro Ueda, Keiji Hirai, Taro Hoshino, Yoshiyuki Morishita

Division of Nephrology, First Department of Integrated Medicine, Saitama Medical Center, Jichi Medical University, Saitama, Japan

\* Corresponding author.

E-mail address: [su-ooka@hb.tp1.jp](mailto:su-ooka@hb.tp1.jp) (S. Ookawara).

0211-6995/© 2018 Sociedad Española de Nefrología. Published by Elsevier España, S.L.U. This is an open access article under the CC BY-NC-ND license (<http://creativecommons.org/licenses/by-nc-nd/4.0/>).

<https://doi.org/10.1016/j.nefro.2018.05.012>

## Prevalencia de fragilidad y factores asociados en pacientes en programa de hemodiálisis

### Frailty prevalence and associated factors in hemodialysis patients

Sr. Director:

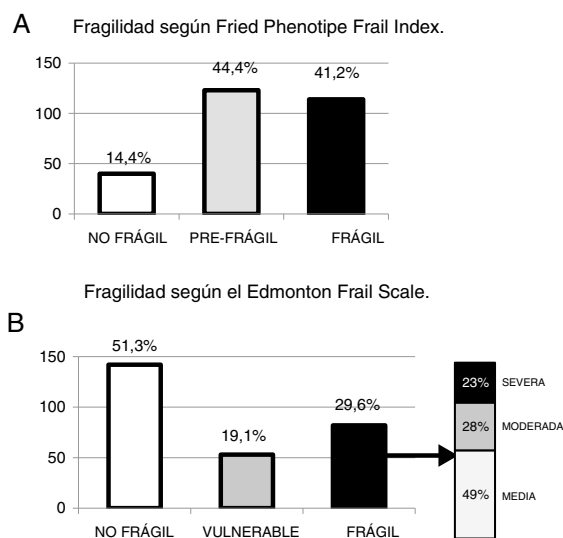
La fragilidad ha sido definida como un síndrome o estado de deterioro y aumento de la vulnerabilidad a situaciones de estrés que se produce con el envejecimiento. Se caracteriza por debilidad y descenso de las reservas funcionales biológicas, lo que lleva a un riesgo aumentado de evolución desfavorable hacia la discapacidad, la hospitalización y el fallecimiento<sup>1,2</sup>. La fragilidad es un concepto diferente a la discapacidad y a la comorbilidad; aunque los 3 conceptos están muy relacionados y se influyen unos a otros, no siempre coexisten<sup>3</sup>.

A pesar de que la fragilidad se ha definido generalmente asociada a la edad avanzada y al envejecimiento, existen condiciones y enfermedades que provocan cambios semejantes al envejecimiento y pueden derivar en un estado de fragilidad en edades más jóvenes; una de estas situaciones es la enfermedad renal crónica<sup>4-6</sup>. Así, algunos estudios han estimado la prevalencia de fragilidad en pacientes en hemodiálisis en un 26 a un 73%<sup>7,8</sup>. Esta gran variabilidad se puede explicar por las diferencias en las poblaciones estudiadas y las distintas herramientas empleadas en la valoración de la fragilidad<sup>9,10</sup>. En nuestro país, hasta el momento actual no se han publicado estudios sobre prevalencia de fragilidad en pacientes en hemodiálisis.

Nuestro objetivo fue estimar la prevalencia de fragilidad en los pacientes en hemodiálisis en el área sanitaria sur de Gran Canaria y estudiar algunos factores demográficos, clínicos y analíticos asociados a la misma. Para ello se diseñó un estudio transversal de 277 pacientes en hemodiálisis estimando la fragilidad mediante el Fried Phenotype Frail Index (FPFI) y la Edmonton Frail Scale (EFS). El FPFI evalúa de forma estandarizada 5 ítems que miden debilidad, lentitud, agotamiento, baja actividad física y pérdida de peso. La EFS evalúa 11 ítems que miden además otras esferas de la fragilidad, como la cognitiva, la psicológica o la social. Se recogieron datos demográficos y clínicos, el índice de comorbilidad de

Charlson y parámetros analíticos. Posteriormente se realizó un seguimiento a un año para valorar la mortalidad según la fragilidad.

La prevalencia de pacientes frágiles con el FPFI fue del 41,2% y con la EFS, del 29,6%. La *figura 1* muestra en gráficos las prevalencias encontradas con ambos test. Hallamos una falta de concordancia entre los resultados; de los pacientes frágiles con EFS un 83% eran frágiles con FPFI y un 17% pre-frágiles, y de los pacientes frágiles con FPFI un 60% eran frágiles con EFS y un 40% vulnerables o no frágiles. El EFS clasificaba un mayor número de pacientes como no frágiles, mientras que el FPFI clasificaba un mayor número como prefrágiles. Es difícil valorar en un estudio transversal la razón y las implicaciones pronósticas de esta discordancia.



**Figura 1** – Prevalencia de fragilidad según el Fried Phenotype Frail Index (A) y la Edmonton Frail Scale (B).