

toxicidad no renal debida a las modificaciones farmacocinéticas de antineoplásicos y de prevenir también la eliminación temprana de fármaco en proceso de diálisis sin alterar su eficacia terapéutica. Creemos que este tema es importante y aún hay mucho que debatir: algoritmos terapéuticos, el tipo de diálisis que indicar, la eficacia y toxicidad de los antineoplásicos, lo cual tendrá un impacto en la sobrevida de nuestros pacientes.

Conflicto de intereses

Los autores declaran no tener conflicto de intereses.

BIBLIOGRAFÍA

1. Registro español de enfermos renales. Informe Actualización 2015. España. Disponible en: <https://goo.gl/RwnfDV>.
2. Janus N, Launay-Vacher V, Thyss A, Boulanger H, Moranne O, Islam MS, et al. Management of anticancer treatment in patients under chronic dialysis: Results of the multicentric CANDY (CANcer and DialYsis) study. *Ann Oncol*. 2013;24:501-7.
3. Sociedad Española de Oncología Médica (SEOM). Las cifras del cáncer en España. 2018. Disponible en: <https://goo.gl/Zp6169>.
4. Funakoshi T, Horimatsu T, Nakamura M, Shiroshita K, Suyama K, Mukoyama M, et al. Chemotherapy in cancer patients undergoing haemodialysis: A nationwide study in Japan. *ESMO Open*. 2018;3:e000301.
5. Maisonneuve P, Agodoa L, Gellert R, Stewart JH, Buccianti G, Lowenfels AB, et al. Cancer in patients on dialysis for end-stage renal disease: An international collaborative study. *Lancet*. 1999;354:93-9.
6. Uchida K, Shoda J, Sugahara S, Ikeda N, Kobayashi K, Kanno Y, et al. Comparison and survival of patients receiving

- hemodialysis and peritoneal dialysis in a single center. *Adv Perit Dial*. 2007;23:144-9.
7. Mandayam S, Shahinian VB. Are chronic dialysis patients at increased risk for cancer? *J Nephrol*. 2008;21:166-74.
 8. Kitai Y, Matsubara T, Yanagita M. Onco-nephrology: Current concepts and future perspectives. *Jap J Clin Oncol*. 2015;45:617-28.
 9. Ettlerson M, Bongers K, Vitale K, Perissinotti AJ, Phillips T, Marini BL. Successful use of cytarabine and bendamustine in a patient with mantle cell lymphoma and acute renal failure using intermittent hemodialysis: A case report. *J Oncol Pharm Pract*. 2018, 1078155217754244.
 10. Hann A, Nosalski E, Hermann PC, Egger J, Seufferlein T, Keller F. Chemotherapeutic agents eligible for prior dosing in pancreatic cancer patients requiring hemodialysis: a systematic review. *Clin Nephrol*. 2018.

Carolt Arana Aliaga^{a,*}
y Jorge Luna-Abanto^{b,c}

^a Fundació Puigvert, Barcelona, España

^b Instituto Nacional de Enfermedades Neoplásicas, Lima, Perú

^c Escuela de Posgrado, Universidad Peruana Cayetano Heredia, Lima, Perú

* Autor para correspondencia.

Correo electrónico: aranacar0100891@gmail.com (C. Arana Aliaga).

0211-6995/© 2019 Sociedad Española de Nefrología. Publicado por Elsevier España, S.L.U. Este es un artículo Open Access bajo la licencia CC BY-NC-ND (<http://creativecommons.org/licenses/by-nc-nd/4.0/>).
<https://doi.org/10.1016/j.nefro.2018.10.003>

Facial crusted scabies on renal transplant patient

Sarna costrosa facial en paciente con trasplante renal

Dear Editor,

Crusted Scabies (Norwegian Scabies) is a rare and severe presentation of the skin infestation caused by the mite *Sarcoptes scabiei* (*var. hominis*) in patients with cellular immunity compromised. Affected patients may present thousands of parasites on the skin surface. Due to impaired immune response, manifestations may occur in a atypical pattern and pruritus may be mild or absent, which can lead to late diagnosis and worse prognosis.¹⁻⁴

A female 47-year-old renal transplant recipient (transplant 16 years ago), with chronic graft nephropathy was admitted in our hospital with asymptomatic lesions on face for one year. She was taking cyclosporine, mycophenolate and prednisone and was hospitalized due to acute respiratory infection and decompensation of baseline nephropathy.

On dermatological examination, she presented erythematous-scaly plaques with greyish-yellow crusts on malar regions, ears, dorsum nasi and supralabial region (Fig. 1a and b). She denied itchiness or lesions on other areas. Considering chronicity of lesions and absence of specific findings on dermoscopy, we decided on performing a skin biopsy. Histopathology revealed pink spiral structures adhered to the stratum corneum, besides multiple mites identified as *S. scabiei*, and a diffuse infiltrate of eosinophils in the reticular dermis (Fig. 2). She was then treated with salicylate 3% mineral oil and permethrin 5% cream as topical therapy, and oral ivermectin (12 mg, repeated 7 days later). She showed complete improvement of lesions.

Crusted Scabies (CS), also known as "Norwegian Scabies" a rare and severe presentation of the skin infestation caused by the mite *S. scabiei* (*var. hominis*) that can occur in patients

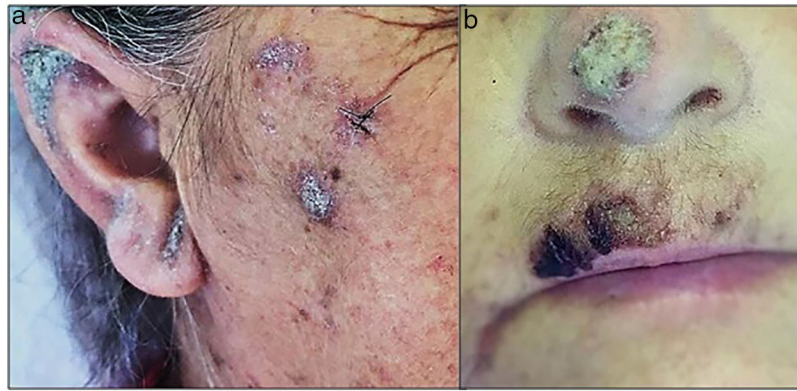

Fig. 1 – Lesions in the face: erythematous-scaly plaques (a and b).

with cellular immunity compromised, including those with graft-versus-host disease, HIV-AIDS, and those ones taking corticosteroids or other immunosuppressants.^{1,2} In this particular presentation, mites reproduce more effectively so that affected patients may carry thousands of parasites over the skin surface. It is highly contagious and minimal contact may be enough to lead to infection. Due to impaired cellular immune response, those patients may present atypical manifestations and pruritus may be mild or even absent, so that diagnosis can be challenging.¹⁻⁴

CS differs from classic Scabies; it manifests as hyperkeratosis, especially on acral sites, but may be disseminated. It may also presents as crusts with erythematous base and lamellar scaling in areas such as scalp, face and neck.^{5,6} Secondary bacterial infection may occur, which increases the risk of bacteremia and sepsis.⁷ Besides the suggestive clinic, diagnosis of CS can be assisted by dermoscopy and microscopy, which allow the direct visualization *in vivo* of mites and eggs.⁸ Skin biopsy may confirm the diagnosis if it contains mites or eggs. However, clinical diagnosis may be challenging due to atypical presentation added up with mild or absent pruritus.⁶ In this case, our patient had long-term lesions, with exclusive facial involvement and complete absence of pruritus. On dermoscopic examination, features were not suggestive of scabies,

so histopathology ended up confirming the diagnosis. Treatment of immunosuppressed patients with CS should combine topical permethrin with systemic ivermectin (repeated in 7–15 days). In addition, patient isolation and behavioural measures are necessary to prevent dissemination.^{1,2}

Early diagnosis and treatment reduce the risk of transmission, outbreaks and severe evolution with associated bacterial infection.⁷ The main differential diagnosis must be done with crusted demodicidosis.⁹

Thus, atypical manifestations of scabies, especially in immunocompromised patients, should be considered, and direct microscopy and/or histopathology may be the key for the right diagnosis.

Declarations

Informed consent to publish individual data was obtained from the patient.

BIBLIOGRAFÍA

- Salavastru C, Chosidow O, Boffa M, Janier M, Tiplica G. European guideline for the management of scabies. *J Eur Acad Dermatol Venereol.* 2017;31:1248–53, <http://dx.doi.org/10.1111/jdv.14351>.
- Sunderkötter C, Feldmeier H, Fölster-Holst R, Geisel B, Klinke-Rehbein S, Nast A, et al. S1 guidelines on the diagnosis and treatment of scabies – short version JDDG. *J Dtsch Dermatol Ges.* 2016;14:1155–67, <http://dx.doi.org/10.1111/ddg.13130>.
- Chosidow O. Scabies. *N Engl J Med.* 2006;354:1718–27, <http://dx.doi.org/10.1056/NEJMcp052784>.
- Heukelbach J, Feldmeier H. Scabies. *Lancet.* 2006;367:1767–74, [http://dx.doi.org/10.1016/S0140-6736\(06\)68772-2](http://dx.doi.org/10.1016/S0140-6736(06)68772-2).
- Elosua-González M, García-Zamora E. Crusted scabies. *N Engl J Med.* 2017;377:476, <http://dx.doi.org/10.1056/NEJMicm1616169>.
- Ebrahim K, Alves J, Tomé L, Moraes C, Gaspar A, Franck K, et al. Norwegian scabies – rare case of atypical manifestation. *An Bras Dermatol.* 2016;91:826–8, <http://dx.doi.org/10.1590/abd1806-4841.20164811>.
- Sampathkumar K, Mahaldar A, Ramakrishnan M, Prabakar S. Norwegian scabies in a renal transplant patient. *Indian J Nephrol.* 2010;20:89, <http://dx.doi.org/10.4103/0971-4065.65302>.

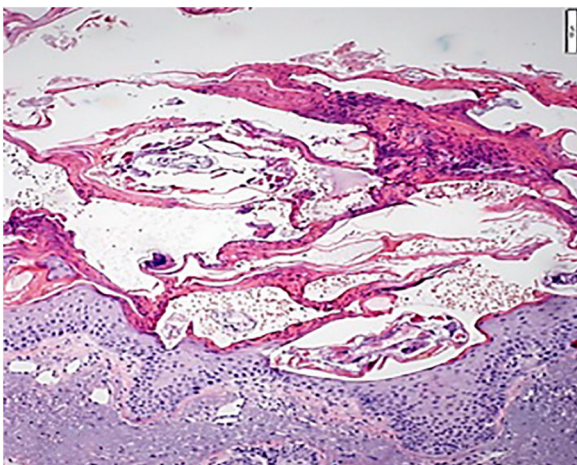


Fig. 2 – Histopathology: *Sarcoptes scabiei* multiple mites (H-E).

8. Towersey L, Cunha M, Feldman C, Castro C, Berger T. Dermoscopia da sarna crostosa associada à síndrome da imunodeficiência adquirida. *An Bras Dermatol*. 2010;85:221-3, <http://dx.doi.org/10.1590/S0365-05962010000200013>.
9. Brutti C, Artus G, Luzzatto L, Bonamigo R, Balconi S, Vettorato R. Crusted rosacea-like demodicidosis in an HIV-positive female. *J Am Acad Dermatol*. 2011;65:e131-2, <http://dx.doi.org/10.1016/j.jaad.2011.05.037>.

Fernanda Poy Dondonis*,
Daniel Martins Costa Jappur, Gabriel Challub Pires,
André da Silva Cartell, Renan Rangel Bonamigo

Dermatology Service of Hospital de Clínicas de Porto Alegre/Federal University of Rio Grande do Sul, Porto Alegre, RS, Brazil

* *Corresponding author.*

E-mail address: fdondonis@hcpa.edu.br (F.P. Dondonis).

0211-6995/© 2019 Sociedad Española de Nefrología. Published by Elsevier España, S.L.U. This is an open access article under the CC BY-NC-ND license (<http://creativecommons.org/licenses/by-nc-nd/4.0/>).

<https://doi.org/10.1016/j.nefro.2018.09.007>