

recommended if compressive symptoms or distal embolisation are present.<sup>8</sup> First-line treatment is usually aneurysmal resection, maintaining arterial continuity by direct suture if possible. If revascularisation is required, the use of autologous grafts is preferred; if these are unavailable, prosthetic grafts or allografts would be used.<sup>3,8-10</sup> In a systematic review published in 2015, with 12 selectable articles and 23 cases described in total, the mean permeability was 12 months (1-38 months) after autografting and 6 months (1-48 months) after PTFE interposition.<sup>10</sup>

Although systematic monitoring by ultrasound in patients with an AVF is not recommended, probably because it is not cost-effective; however it would be reasonable to perform a physical examination of the AVF at follow-up visits or at haemodialysis sessions.<sup>9</sup> If aneurysmal degeneration is suspected it would be advisable to request a ultrasound to make early diagnosis and avoid possible thromboembolic and/or compressive complications.

## REFERENCES

- Schunn CD, Sullivan TM. Brachial arteriomegaly and true aneurysmal degeneration: case report and literature review. *Vasc Med.* 2002;7:25-7.
- Gray RJ, Stone WM, Fowl RJ, Cherry KJ, Bower TC. Management of true aneurysms distal to the axillary artery. *J Vasc Surg.* 1998;28:606-10.
- Chemla E, Nortley M, Morsy M. Brachial artery aneurysms associated with arteriovenous access for hemodialysis. *Semin Dial.* 2010;23:440-4.
- Eugster T, Wigger P, Bölter S, Bock A, Hodel K, Stierli P. Brachial artery dilatation after arteriovenous fistulae in patients after renal transplantation. A 10-year follow-up ultrasound scan. *J Vasc Surg.* 2003;37:564-7.
- Dammers R, Tordoir JH, Welten RJ, Kitslaar PJ, Hoeks AG. The effect of chronic flow changes on brachial artery diameter and shear stress in arteriovenous fistulas for hemodialysis. *Int J Artif Organs.* 2002;25:124-8.
- Reilly JM, Savage EB, Brophy CM, Tilson MD. Hydrocortisone rapidly induces aortic rupture in a genetically susceptible mouse. *Arch Surg.* 1990;125:707-9.
- Sato O, Takagi A, Miyata T, Takayama Y. Aortic aneurysms in patients with autoimmune disorders treated with corticosteroids. *Eur J Vasc Endovasc Surg.* 1995;10:366-9.
- Marzelle J, Gashi V, Nguyen HD, Mouton A, Becquemin JP, Bourquelot P. Aneurysmal degeneration of the donor artery after vascular access. *J Vasc Surg.* 2012;55:1052-7.
- Mestres G, Fontserè N, Yugueros X, Tarazona M, Ortiz I, Riambau V. Aneurysmal degeneration of the inflow artery after arteriovenous access for hemodialysis. *Eur J Vasc Endovasc Surg.* 2014;48:592-6.
- Kordzadeh A, Espiney Barbara R, Ahmad A, Hanif M, Panayiotopoulos Y. Donor artery aneurysm formation following the ligation of haemodialysis arteriovenous fistula: a systematic review and case reports. *J Vasc Access.* 2015;16:5-12.

Carlota Fernández Prendes\*,  
Ahmad Amer Zanabali Al-Sibbai, Mario González Gay,  
Jose Antonio Carreño Morrondo, Manuel Alonso Pérez

Servicio de Angiología y Cirugía Vascular, Hospital Universitario Central de Asturias, Oviedo, Asturias, Spain

\* Corresponding author.

E-mail address: [carlota.f.prendes@gmail.com](mailto:carlota.f.prendes@gmail.com)  
(C. Fernández Prendes).

<http://dx.doi.org/10.1016/j.nefro.2017.01.024>

2013-2514/© 2016 Sociedad Española de Nefrología. Published by Elsevier España, S.L.U. This is an open access article under the CC BY-NC-ND license (<http://creativecommons.org/licenses/by-nc-nd/4.0/>).

## New microorganism in catheter-related bacteremia?☆

### ¿Nuevo microorganismo en la bacteriemia asociada a catéter?

Dear Editor,

In recent years, there is an increased prevalence of patients with advanced chronic kidney disease (ACKD) carrying tunneled central venous catheters (CVC) for haemodialysis.<sup>1,2</sup>

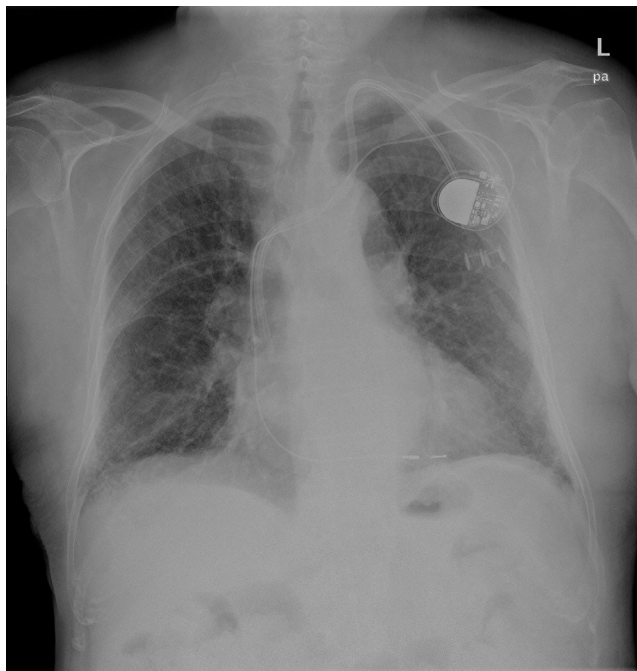
Catheter-related bacteraemia (CRB) is one of the major causes of morbidity and mortality in these patients.<sup>2</sup>

The microorganisms responsible for two-thirds of these bacteraemias are gram-positive bacteria,<sup>2</sup> not forgetting the other microorganisms.

*Ochrobactrum anthropi* is a gram-negative, non-fermenting, aerobic, mobile, oxidase- and urease-positive bacillus.<sup>3</sup> It is ubiquitous in nature and can be found in hospital environments. Several cases of bacteraemia associated with this microorganism have been described in immunocompromised patients, although some cases have also occurred in immunocompetent patients.<sup>4,5</sup> Its isolation as the cause of CRB is rare.

Two cases of bacteraemia due to this microorganism in recent months are described below in patients with a CVC for haemodialysis.

☆ Please cite this article as: Torres Aguilera E, Verde Moreno E, Muñoz P, Valerio M, Luño J. ¿Nuevo microorganismo en la bacteriemia asociada a catéter? *Nefrologia.* 2017;37:98-100.



**Fig. 1 – Pacemaker cable wound around the central venous catheter.**

An 84-year-old male patient with pacemaker diagnosed with ACKD secondary to diabetic nephropathy in a haemodialysis program through tunneled jugular CVC, who was admitted with a diagnosis of CRB due to *Ochrobactrum anthropi*. Treatment was started with post-dialysis gentamicin and CVC sealing with ciprofloxacin, initially discarding replacement of the CVC because of the high risk of vessel tear and moving of the pacemaker cable that was wound around the catheter (Fig. 1). After 4 weeks of antibiotic therapy, given the absence of an infectious condition and the negativisation of blood cultures, treatment was discontinued.

Three months later he had a new episode of CRB due to *Ochrobactrum anthropi*, and was treated with meropenem and trimethoprim/sulfamethoxazole by antibiogram. A transoesophageal echocardiogram was performed, ruling out the presence of endocarditis. Finally, in view of the persistence of the condition, it was decided to remove the pacemaker and the CVC and implant a new epicardial pacemaker and femoral CVC, which resolved the condition without subsequent recurrences.

The second case is a 88-year-old diabetic and hypertensive woman with significant vasculopathy, diagnosed with ACKD secondary to diabetic nephropathy, on haemodialysis through a femoral CVC, who was admitted due to septic shock of uncertain origin. Empirical antibiotic therapy was started with vancomycin and meropenem, confirming the diagnosis of CRB due to *Ochrobactrum anthropi*. Despite significant clinical improvement, in view of the persistence of fever and given the history of the previous case, it was decided to remove the CVC and complete treatment with ciprofloxacin. Implanting a new CVC resolved the condition and there were no new infectious complications.

CRB due to *Ochrobactrum anthropi* is a very rare condition in our setting. This microorganism is a gram-negative bacillus, ubiquitous in nature, belonging to the *Brucellaceae* family, within the *Alphaproteobacteria* class.<sup>3</sup> In recent years its importance has increased as an emergent pathogen in immunocompromised patients, especially in hospital settings,<sup>6</sup> and the most commonly described infection is CRB, due to this bacteria's easy adherence to synthetic hospital materials, a characteristic similar to those of the genus *Staphylococcus*.<sup>5</sup>

Although most cases of infection from this microorganism have been described in immunocompromised patients, some cases have been described in immunocompetent patients.<sup>4,5</sup>

To date, there are few published cases of bacteraemia in patients on haemodialysis,<sup>5,7-9</sup> none of them in Spain.

Endophthalmitis, meningitis, endocarditis, osteochondritis, pancreatic abscess and pelvic abscess conditions have been described.

In most of these, the strains of *Ochrobactrum anthropi* were resistant to beta-lactams and groups of antibiotics such as penicillins, cephalosporins and aztreonam, but were sensitive to aminoglycosides, fluoroquinolones, carbapenems, tetracyclines and trimethoprim/sulfamethoxazole. Resistance is mediated in part by the presence of inducible type AmpC  $\beta$ -lactamases.<sup>10</sup> Our cases matched this pattern of sensitivity and resistance.

It should finally be noted that, as in other published cases, we did not see any local signs of infection at the catheter insertion site, with scant clinical expressiveness of the condition, except for the presence of fever. In the second case, the severity of the general condition of the patient was noteworthy, with no focal point of infection data, improving rapidly after starting antibiotic therapy. All this presents the need for high clinical suspicion with early diagnosis and treatment.

In conclusion, it is important to highlight the emergent role of *Ochrobactrum anthropi* as a pathogen responsible for CRB tunneled for haemodialysis. We also consider that early intravenous antibiotic treatment is important, and if no response is obtained within 48-72 h of starting, early withdrawal of the dialysis catheter should be performed to definitively eradicate the microorganism.

## REFERENCES

1. Roca Tey R. El acceso vascular para hemodiálisis: la asignatura pendiente. *Nefrología*. 2010;30:280-7.
2. Aguinaga A, del Pozo JL. Infección asociada a catéter en hemodiálisis: diagnóstico, tratamiento y prevención. *NefroPlus*. 2011;4:1-10.
3. Bruckner D, Colonna P. Nomenclature for aerobic and facultative bacteria. *Clin Infect Dis*. 1993;16:598-605.
4. Javaid MM, Rumjon A, Cubbon M. *Ochrobactrum anthropi* bacteremia in a non-diabetic, immunocompetent hemodialysis patient. *Dial Transplant*. 2008;37:452-3.
5. Nicolás Obando M, Marta Badilla S. Bacteriemia por *Ochrobactrum anthropi* en paciente en hemodiálisis por catéter tunelizado permanente: Caso clínico. *Rev Med Chile*. 2011;139:1344-6.
6. Yu WL, Lin CW, Wang DY. Clinical and microbiologic characteristics of *Ochrobactrum anthropi* bacteriemia. *J Formos Med Assoc*. 1998;97:106-12.

7. Daxboek F, Zitta S, Assadian O, Krause R, Wenish C. *Ochrobactrum anthropi* bloodstream infection complicating hemodialysis. *Am J Kidney Dis.* 2002;40:e17.1-4.
8. Chertow G. *Ochrobactrum anthropi* bacteremia in a patient on hemodialysis. *Am J Kidney Dis.* 2000;35:e30.1-2.
9. Soloaga R, Carrión N, Pidone J, Guelfand L, Margari A, Altieri R. Bacteriemia relacionada a catéter por *Ochrobactrum anthropi*. *Medicina (B Aires).* 2009;69:655-7.
10. Ospina S, Atehortúa Muñoz S, Zapata J. Bacteriemia por *Ochrobactrum anthropi* en paciente con obstrucción de la vía biliar. *Infect.* 2009;13:293-5.

Esther Torres Aguilera<sup>a,\*</sup>, Eduardo Verde Moreno<sup>a</sup>,  
Patricia Muñoz<sup>b</sup>, Maricela Valerio<sup>b</sup>, Jose Luño<sup>a</sup>

<sup>a</sup> Servicio de Nefrología, Hospital General Universitario Gregorio Marañón, Madrid, Spain

<sup>b</sup> Servicio de Microbiología, Hospital General Universitario Gregorio Marañón, Madrid, Spain

\* Corresponding author.

E-mail address: [estertor.ag@gmail.com](mailto:estertor.ag@gmail.com) (E. Torres Aguilera).

<http://dx.doi.org/10.1016/j.nefro.2017.01.019>

2013-2514/© 2016 Sociedad Española de Nefrología. Published by Elsevier España, S.L.U. This is an open access article under the CC BY-NC-ND license (<http://creativecommons.org/licenses/by-nc-nd/4.0/>).

## Hypercalcemia and hypophosphatemia in a 11 years old girl with ovarian tumour<sup>☆</sup>

### Hipercalcemia e hipofosforemia en niña con tumour ovárico

Dear Editor,

The most common cause of hypercalcaemia in patients with non-metastatic solid tumours is the secretion of parathyroid hormone-related (PTHr) protein.<sup>1</sup>

The patient is an 11-year-old female with no history of interest, to be evaluated for an abdominal mass. Upon arrival the patient showed high serum creatinine, hypercalcaemia and hypophosphatemia (Table 1). The baseline renal function test also showed hypercalciuria and hyperphosphaturia. CT scan showed a large intra-abdominal mass. A complete resection of the tumour was

performed. An anatomopathological study revealed the presence of an ovarian granulosa cell tumour.

Clinical course was favourable. In the follow-up, one week after removal of the tumour, blood calcium levels normalised but urinary calcium remained high. The hypophosphataemia persisted, despite greater renal reabsorption of phosphate. After one month, all blood and urine biochemical parameters were within the normal range (Table 1).

Hypercalcaemia due to hypersecretion of PTHr by malignant tumours is an exceptional finding at paediatric age.<sup>2,3</sup> Parathyroid hormone (PTH) and PTHr have shown similar effects in the renal handling of calcium and phosphate.<sup>4-7</sup>

**Table 1 – Biochemical blood and urine values prior to tumour removal and at days 6, 30 and 60 after surgery.**

	Pre-operative	Six days after surgery	Thirty days after surgery	Sixty days after surgery
Blood creatinine (mg/dl)	1.13	0.75	0.66	0.64
Blood-ionised calcium (mMol/l)	1.66	1.18	1.27	1.22
Blood phosphate (mg/dl)	2.6 mgr/dl	2.8 mgr/dl	5.2	5.4
PTH intact (pg/ml)	2.7	44	–	–
PTHr <sup>a</sup> (pmol/l)	10.8	<1.1	–	–
Vitamin D (ng/ml)	30	–	–	–
Calcitonin (pg/ml)	10.4	–	–	–
Urine Ca/Cr ratio	1.4	0.46	0.09	0.07
CEI <sup>a</sup>	1.59	0.34	0.06	0.05
Calciuria (mg/kg/24 h)	15	7.43	1.61	1.26
TRP <sup>a</sup>	32	96	94	90
TP/GFR <sup>a</sup>	0.85	2.71	4.88	4.82
Phosphaturia (mg/24 h/1.73 m <sup>2</sup> )	954	110	427	880

CEI: calcium excretion index; PTHr: parathyroid hormone-related protein; TP/GFR: phosphate per 100 ml of glomerular filtration rate; TRP: tubular reabsorption of phosphate.

<sup>a</sup> Source: Santos and García-Nieto.<sup>9</sup>

DOI of original article:

<http://dx.doi.org/10.1016/j.nefro.2016.09.008>.

<sup>☆</sup> Please cite this article as: Ubetagoyena Arrieta M, Martínez Sainz de Jubera J, García de Andoin Barandiaran N, Úriz Monaut JJ, López Cuesta S, Domínguez Castells A. Hipercalcemia e hipofosforemia en niña con tumour ovárico. *Nefrologia.* 2017;37:100-101.