

Letters to the Editor

Enterococcus gallinarum and Chilaiditi syndrome in peritoneal dialysis[☆]

Enterococcus gallinarum y síndrome de Chilaiditi en diálisis peritoneal

Dear Editor,

Peritonitis due to *Enterococcus gallinarum* is a rare entity, very few cases have been reported and all of them in patients with hepatic cirrhosis.^{1,2}

We hereby present the case of a fifty-three-year old patient on peritoneal dialysis (PD) and a personal history of psychomotor retardation, chronic obstructive pulmonary disease (COPD) with home oxygen therapy and chronic renal failure on hemodialysis and with multiple vascular complications.

Back in December 2012 it was decided to implant a catheter for the PD due to the impossibility of performing an arteriovenous fistula.

The patient was a nasal carrier of *Staphylococcus aureus* that even though it was eradicated through therapy presented a first episode of peritonitis due to this same germ that resolved with antibiotic treatment five months after starting therapy. One year later the patient had a new episode due to *Streptococcus epidermidis* and later on an episode due to *Streptococcus mitis*.

In January 2015 the patient came to the emergency room complaining of abdominal discomfort and turbid fluid (2590 cells/ μ l, 90 per cent polymorphonuclear [PMN], and 10 per cent monomorphonuclear [MNM]). This clinical presentation was interpreted as a probable relapse of peritonitis caused by *S. mitis* and treatment was initiated with IP ampicillin and gentamicin. Twenty-four hours later the presence of *E. gallinarum* in peritoneal fluid (PF) was confirmed and therapy was changed to IP daptomycin and gentamicin and oral fluconazole, with rapid response. Therapy was maintained for another three (3) weeks with a control culture that resulted to be negative.

Forty days after finishing treatment there was slightly turbid fluid (leucocyte recount 355 cells/ μ l, PMN 66 per cent, MNM

34 per cent) and *E. gallinarum* was isolated; the same treatment was initiated with identical response from was observed.

One week later there was presence of peritonitis due to *Candida parapsilosis*. After catheter removal and performance of an antifungal sensitivity test the patient received therapy with fluconazole that resulted in clinical resolution.

A permanent left jugular catheter was implanted and hemodialysis was initiated.

Three months later the patient had clinical manifestations of nausea, vomiting, and weight loss (C-reactive protein [CRP]: 9 mg/dl).

Sclerosing peritonitis was suspected an abdominal CT scan was requested that confirmed the following findings: unknown Chilaiditi syndrome and mesenteric thickening causing encapsulated ileal loop in the upper abdomen level and anterior to the transverse colon.

Treatment was initiated with GI rest, corticoids, tamoxifen and nutritional support with good response.

Presently and after being discharged from the hospital nutrition unit, the patient follows a normal diet and remains asymptomatic.

In the control CT scan the patient had improved showing a reduced peritoneal thickening and not showing any signs of intestinal sub-occlusion. The RCP dropped to 0.2 mg/dl.

Both *E. gallinarum* and *Enterococcus casseliflavus* are organisms that affect critically ill or immunosuppressed patients. The prior use of antibiotics can increase colonization by these organisms. These germs are usually vancomycin-resistant.³

No cases of peritonitis due to this germ in patients on PD have been reported in the medical literature. In our patient the clinical manifestation was not very florid and the patient remained asymptomatic during most of the process. The peritoneal swelling resolved rapidly after initiating antibiotic therapy.

[☆] Please cite this article as: Pérez Melón C, Ferreiro Álvarez B, Iglesias Lamas E, Gamba Caride MJ, Borrajo Prol MP, Novoa Fernández E. *Enterococcus gallinarum* y síndrome de Chilaiditi en diálisis peritoneal. Nefrología. 2017;37:213-214.

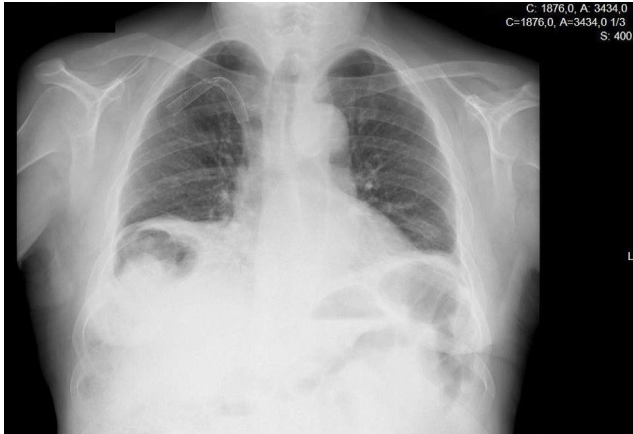


Fig. 1 – Thoracic X-ray with Chilaiditi syndrome.

The Chilaiditi sign consists of the interposition of one part of the colon between the liver and the diaphragm and in the presence of symptoms is called Chilaiditi syndrome.⁴ The most common symptoms of all are abdominal pain, vomiting, and constipation though cases of perforation, volvulus or intestinal obstruction have also been reported. Usually the clinical features resolve with conservative therapy and if there are any complications, the surgery may be necessary, some times even colectomy or laparoscopic colonopexy.^{4,5}

Both the Chilaiditi sign and syndrome are rare yet more common in males. Other factors associated with a higher frequency are mental retardation and chronic obstructive pulmonary disease, all of them factors present this case.

We think that both Chilaiditi syndrome and sclerosing peritonitis contributed to the clinical manifestation of intestinal sub-occlusion in our patient.

Entities like the pneumoperitoneum have X-ray expressions that are similar to Chilaiditi syndrome (Fig. 1), and this is the reason why in patients on peritoneal dialysis the diagnosis may go unnoticed easily. Performing an abdominal

CT scan may be helpful in cases like this.^{5,6}

REFERENCES

1. Alvarez MA, Doménech E, Rosinach M, Lorenzo-Zuñiga V, Smontoliu, Planas R. *Enterococcus gallinarum* bacteriascites in a patient with active tuberculosis and HCV cirrhosis. *Am J Gastroenterol.* 2002;97:2681-2.
2. Redondo-Cerezo E, López FN, Tapia M, Blanco FS, Garcia RM, Martín-Vivaldi R. *Enterococcus gallinarum* spontaneous bacterial peritonitis in a HCV cirrhotic woman. *Am J Gastroenterol.* 2002;97:214-5.
3. Van Horn KG, Rodney KM. Colonization and microbiology of the motile enterococci in a patient population. *Diagn Microbiol Infect Dis.* 1998;31:525-30.
4. Gil Díaz MJ, Murillo Gómez M, Jiménez González P. Signo y síndrome de Chilaiditi: entidades a tener en cuenta. *Semergen.* 2011;37:267-9.
5. Sparks DA, Dawood MY, Chase DM, Thomas DJ. Ischemic volvulus of the transverse colon: a case report and review of literature. *Cases J.* 2008;1:174.
6. Sonke GS, Beerepoot LV, Los M. A patient with subdiaphragmatic air. *Neth J Med.* 2008;66:89-90.

Cristina Pérez Melón*, Beatriz Ferreiro Álvarez, Elena Iglesias Lamas, María Jesús Camba Caride, María Paz Borrajo Prol, Enrique Novoa Fernández

Nefrología, Complejo Hospitalario Universitario de Ourense, Ourense, Spain

* Corresponding author.

E-mail address: cristicpm@hotmail.com (C. Pérez Melón).

2013-2514/© 2016 Sociedad Española de Nefrología. Published by Elsevier España, S.L.U. This is an open access article under the CC BY-NC-ND license (<http://creativecommons.org/licenses/by-nc-nd/4.0/>).

<http://dx.doi.org/10.1016/j.nefro.2017.03.002>

Segmental tuberous sclerosis in a patient with chronic kidney disease[☆]

Esclerosis tuberosa segmentaria en un paciente con enfermedad renal crónica

Dear Editor,

33-year-old woman presented with fatigue and renal failure. On physical examination, the patient had multiple non-

traumatic periungual fibromas in both hands and feet (Fig. 1a). Shagreen patch was seen in the right lumbosacral region (Fig. 1b). On admission biochemical tests revealed; urea: 132 mg/dl, creatinine:4.7 mg/dl, potassium: 4.7 mmol/L, GFR 12 ml/min/1.73 m² (MDRD), pH 7.32, HCO₃: 18.4. Renal ultrasonography revealed bilateral renal cysts (17 and 5 mm at right

DOI of original article:

<http://dx.doi.org/10.1016/j.nefro.2016.09.012>.

[☆] This case was accepted as a poster presentation at Proceeding Book for ASN Kidney Week 2015, San Diego, USA.