

Case report

Distal renal tubular acidosis in two children with acquired hypothyroidism[☆]

Norma E. Guerra-Hernández^{a,*}, Karen V. Ordaz-López^a, Rosa Vargas-Poussou^b,
Laura Escobar-Pérez^c, Víctor M. García-Nieto^d

^a Servicio de Nefrología Pediátrica, Hospital General del Centro Médico Nacional «La Raza», Instituto Mexicano del Seguro Social (IMSS), Ciudad de México, Mexico

^b Departamento de Genética y Fisiología, Hospital Europeo Georges Pompidou, París, France

^c Departamento de Fisiología, Facultad de Medicina, Universidad Nacional Autónoma de México, Ciudad de México, Mexico

^d Sección de Nefrología Pediátrica, Hospital Universitario Nuestra Señora de Candelaria, Santa Cruz de Tenerife, Spain

ARTICLE INFO

Article history:

Received 19 August 2017

Accepted 31 December 2017

Available online 4 December 2018

Keywords:

Renal tubular acidosis

Hypothyroidism

Autoimmunity

Maximum urinary pCO₂

ABSTRACT

Two cases of children diagnosed with renal tubular acidosis (RTA) associated with autoimmune hypothyroidism are presented.

Case 1 developed an intestinal ileus at the age of five in the context of a respiratory problem. The tests performed confirmed metabolic acidosis, hyperchloraemia, hypokalaemia and nephrocalcinosis. Case 2 was diagnosed with hypothyroidism at the age of 11, and with RTA two years later.

In both patients, the diagnosis of RTA was verified when decreased maximum urinary pCO₂ was found. In case 2, a proximal bicarbonate leak (type 3 RTA) was also confirmed. This was the first case to be published on the topic.

The causes of RTA in patients with hypothyroidism are reviewed. The deleterious effect on the kidneys may be due to the absence of thyroid hormone and/or autoantibodies in the cases of autoimmune hypothyroidism.

© 2018 Sociedad Española de Nefrología. Published by Elsevier España, S.L.U. This is an open access article under the CC BY-NC-ND license (<http://creativecommons.org/licenses/by-nc-nd/4.0/>).

DOI of original article:

<https://doi.org/10.1016/j.nefro.2017.12.005>.

[☆] Please cite this article as: Guerra-Hernández NE, Ordaz-López KV, Vargas-Poussou R, Escobar-Pérez L, García-Nieto VM. Acidosis tubular renal distal en dos niñas diagnosticadas de hipotiroidismo adquirido. *Nefrología*. 2018;38:655–659.

* Corresponding author.

E-mail addresses: nelizguerra@gmail.com, normaegh@yahoo.com.mx (N.E. Guerra-Hernández).

2013-2514/© 2018 Sociedad Española de Nefrología. Published by Elsevier España, S.L.U. This is an open access article under the CC BY-NC-ND license (<http://creativecommons.org/licenses/by-nc-nd/4.0/>).

Acidosis tubular renal distal en dos niñas diagnosticadas de hipotiroidismo adquirido

R E S U M E N

Palabras clave:

Acidosis tubular renal
Hipotiroidismo
Autoinmunidad
pCO₂ urinaria máxima

Se presentan dos casos en edad pediátrica diagnosticados de acidosis tubular renal (ATR) asociada a hipotiroidismo de causa autoinmune.

El caso 1 desarrolló un íleo intestinal a los 5 años de edad en el seno de un problema respiratorio. En los exámenes realizados se constató acidosis metabólica, hipercloremia, hipopotasemia y nefrocalcinosis. El caso 2 fue diagnosticado de hipotiroidismo a los 11 años de edad y 2 años después, de ATR.

En ambos pacientes, se comprobó el diagnóstico de ATR al observarse una pCO₂ urinaria máxima reducida. En el caso 2 se constató, además, una fuga proximal de bicarbonato (ATR tipo 3), que constituye el primer caso publicado sobre el tema.

Se revisan las causas de ATR en pacientes con hipotiroidismo. El efecto deletéreo sobre el riñón puede ser debido a la propia ausencia de hormona tiroidea y/o a los autoanticuerpos en los casos de hipotiroidismo autoinmune.

© 2018 Sociedad Española de Nefrología. Publicado por Elsevier España, S.L.U. Este es un artículo Open Access bajo la licencia CC BY-NC-ND (<http://creativecommons.org/licenses/by-nc-nd/4.0/>).

The term renal tubular acidosis (RTA) is applied to a group of transport defects in the reabsorption of bicarbonate in the proximal tubule (proximal or type 2 RTA), the excretion of hydrogen ions (H⁺) in the collecting tubule (RTA type 1 and 4) or both (RTA type 3).¹ It is characterised by the presence of persistent hyperchloraemic metabolic acidosis with a normal anion gap.

Primary forms are more common in infants and children.² Distal RTA is the most common variant. In recent years, molecular biology techniques have identified the genetic factors involved in inadequate urinary excretion of H⁺ and ammonium in patients with distal RTA.³ This defect can be diagnosed by NH₄Cl loading (rich in H⁺) or by determining maximum urinary pCO₂ (UpCO₂).⁴ Clinically, distal RTA is characterised by the presence of polyuria, polydipsia, nephrocalcinosis, hypokalaemia, persistently alkaline urine, hypercalciuria, hypocitraturia, and a defect in renal concentrating capacity, with a tendency towards dehydration.⁵

Secondary forms of distal RTA, more common in adults, are associated with the administration of drugs or toxins, or with systemic or immunological diseases. In children, secondary causes are less common, and have been described in cases of Sjögren's syndrome⁶ or systemic lupus erythematosus,⁷ or after oral intake of some medications.

Few cases of distal RTA associated with classic hypothyroidism or with autoimmune thyroid disease have been reported. Even fewer cases have been reported in children. We report the cases of two girls with acquired hypothyroidism associated with secondary distal RTA. The association between hypothyroidism and type 3 RTA in one of the patients is the first case reported in the literature.

Case 1

A girl aged 5 years and 7 months, with a history of abdominal distension from the first months of life, together with

Table 1 – Blood and urine biochemical tests.

	Case 1	Case 2
<i>Venous blood gas</i>		
pH	7.18	7.2
HCO ₃ ⁻ (mEq/l)	4.9	9.3
Serum chlorine (mmol/l)	125	116
Serum potassium (mmol/l)	2.47	2.3
Serum uric acid, (mg/dl)	2	1.9
Calcium/creatinine ratio (mg/mg)	0.95	0.33
24-Hour urine calcium (mg/kg/day)	13.8	4.5
Citrate/creatinine ratio (mg/mg)	50	
24-Hour urine citrate (mg/kg/day)	1.5	
Oxaluria (mmol/mol)	2.3	
Fractional excretion of bicarbonate	3.39%	12.75%

arrested weight gain and growth from the age of 2 (below the 3rd percentile). She was admitted due to a 3-day history of fever of 39 °C, greenish rhinorrhoea, productive cough and pharyngeal pain, accompanied by progressive respiratory difficulty, polypnoea and abdominal distension. On admission, the physical examination found severe dehydration, dry oral mucosa, tachycardia, signs of pulmonary consolidation in the right hemithorax, and distended abdomen with decreased peristalsis. A chest X-ray confirmed the diagnosis of pneumonia, and an abdominal X-ray was compatible with metabolic ileus. Laboratory test findings included metabolic acidosis, hyperchloraemia and hypokalaemia, which persisted despite restoration of the fluid balance (Table 1). A urine test found hypercalciuria and hypocitraturia (Table 1) and the kidney ultrasound showed grade 2 nephrocalcinosis (Fig. 1). An acetazolamide- and sodium bicarbonate-loading test was performed, obtaining a maximum urinary pCO₂ of 47 mmHg at 60 min (urine-blood pCO₂ gradient: 15 mmHg) (Table 2). The audiometry test was normal.

After reaching a diagnosis of distal RTA, treatment with potassium citrate solution was initiated (4 mEq/kg/day), with no improvement in weight and height, and persistence

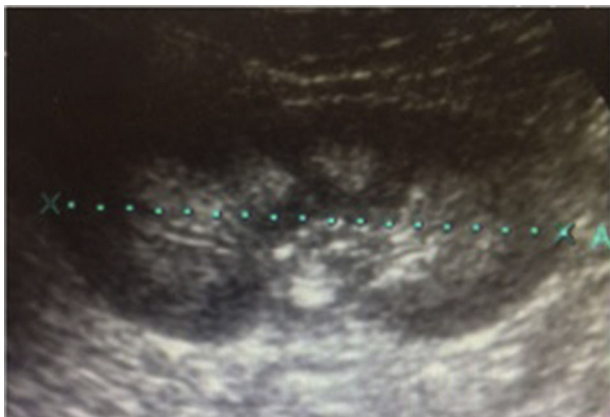

Fig. 1 – Ultrasound image of nephrocalcinosis in case 1.

of asthenia, adynamia and somnolence. The thyroid function test showed thyroid-stimulating hormone (TSH) levels of more than 150 mU/l, T3 levels of 0.19 ng/ml and undetectable T4. Blood samples were positive for antithyroglobulin (181.6 IU/ml) and antiperoxidase (373.2 IU/ml) antibodies. Levothyroxine was started, and the patient's weight and height improved. Now, at 11 years of age, her weight is 29 kg (p8%) and her height 133 cm (p6%); urinary acidification defect persists (maximum urinary pCO₂ of 49 mmHg).

No molecular alterations were observed in *ATP6V0A4*, *ATP6V1B1* and *SLC4A1* genes analysed by targeted exon and exon-intron transition sequencing.

Case 2

This was a 13-year-old girl, with no significant family history, with arrested weight gain and growth from the age of 7. Since then, she had presented 4 episodes of limb paralysis and generalised weakness, with craniocervical instability and bilateral genu valgum. At age 11 she was diagnosed with hypothyroidism, and started treatment with levothyroxine. She was subsequently referred to the hospital for a hypokalaemia study. The results of the blood and urine panels and acidification test are shown in Tables 1 and 2. Along with the distal acidification defect, a bicarbonate leak in the proximal tubule, compatible with type 3 RTA was observed (Table 1). Kidney ultrasound showed bilateral grade 2 nephrocalcinosis. The audiometry assessment was normal. Blood samples were positive for antithyroglobulin (246.8 IU/ml) and antiperoxidase (92.6 IU/ml) antibodies. One year after the diagnosis of RTA, the patient required higher doses of citrate, and the urinary acidi-

fication defect (maximum urinary pCO₂ of 53 mmHg) persists. Now, at 14 years of age, she weighs 40 kg (p5%) and her height is 138 cm (p0%).

Discussion

Thyroid hormones influence kidney development, kidney structure, renal haemodynamics, glomerular filtration rate, the function of many transport systems along the nephron, in particular those related to the management of sodium, acid–base balance and renal concentrating capacity. These effects of the thyroid hormone are in part due to direct renal actions, and in part to cardiovascular and systemic haemodynamic effects that influence kidney function.⁸

Thyroid hormones directly influence the expression and/or activity of a number of ion channels and transporters. Pioneering micropuncture studies in hypothyroid rats have shown a reduction in the renal glomerular filtration rate (GFR) and an increase in the urinary excretion of sodium and water.⁹ A subsequent study reported that the thyroid hormone regulates the activity of the proximal tubular type 3 Na⁺/H⁺ exchanger (NHE3)¹⁰ (Fig. 2), an effect that is due to direct binding of the hormone with the promoter region of the encoding gene.¹¹

A study published in 2007 confirmed the activity of several transporters involved in sodium and acid–base balance in rats rendered hypothyroid by the administration of methimazole.¹² The results obtained are summarised in the footer of Fig. 2. Basically, the activity of several proximal tubule transporters is reduced, which results in a loss of sodium and a reduction in the elimination of hydrogen ions at this level, while expression of the Cl⁻/HCO₃⁻ (AE1) exchanger specific to α -intercalated cells of the connecting tubule and cortical collecting duct increases.¹² This shows, therefore, that thyroid hormone deficiency is associated with a defect in the renal handling of sodium and of the acid–base balance, which is mainly located in the proximal tubule and is compensated by the distal nephron. Consequently, on a physiological level, the thyroid hormone modulates the renal response to acid overload and alters the expression of several transporters that are key in the maintenance of the acid–base balance.

This begs the question of why significant proximal sodium loss does not lead to reduced levels of sodium in hypothyroidism. This was studied in transgenic mice deficient in the Na⁺/H⁺ (NHE3) exchanger¹³ and in adults with mutations in the encoding gene.¹⁴ In these cases, loss of NHE3 was compensated by a reduction in GFR caused by adenosine-induced vasoconstriction of the afferent arteriole. This is one of the reasons why GFR is reduced in hypothyroid patients.^{15,16}

A study published in the 1970s showed that 2 of 5 adults with primary hypothyroidism without metabolic acidosis and with no clinical evidence of autoimmune disease were unable to lower their urine pH appropriately after short duration acid-loading¹⁷; this is typical of incomplete distal RTA. Subsequently, various cases of type 1 RTA have been described in adults with non-autoimmune hypothyroidism.^{18,19} One of these patients presented with hyperkalaemia (type 4 RTA) compatible with an increase in Na⁺ levels in the tubular lumen of the collecting duct and impaired distal secretion due to an H⁺ and K⁺¹⁸ gradient defect.

Table 2 – Results of the maximum urinary pCO₂ test performed after sodium bicarbonate and acetazolamide loading.

	Case 1	Case 2
Urinary pH	7.6	8
Maximum urinary pCO ₂ (mmHg)	51	46
Urinary HCO ₃ ⁻ (mEq/l)	85.22	101.97
Urine–blood pCO ₂ gradient (mmHg)	2	15

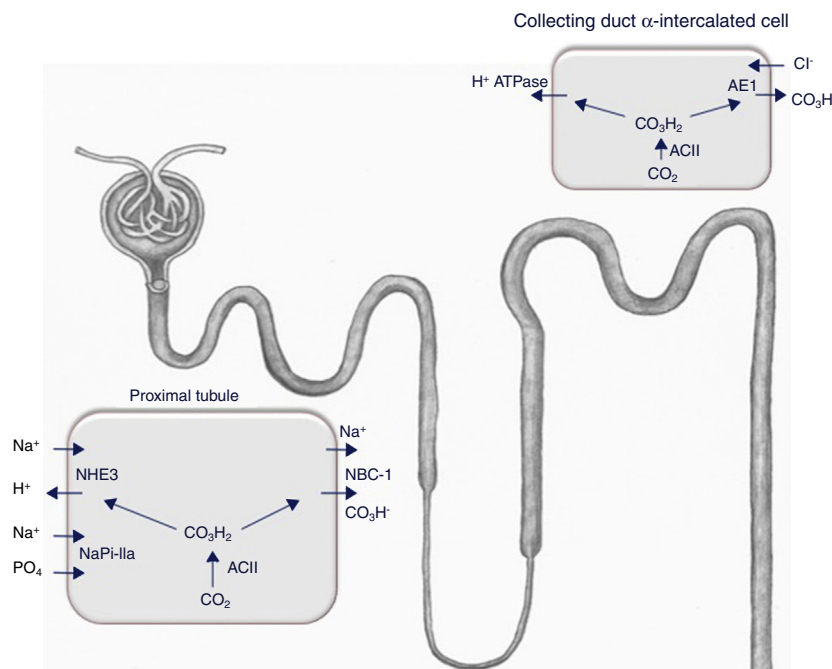


Fig. 2 – The expression of the Na⁺/H⁺ exchanger (NHE3), the Na⁺-phosphate cotransporter NaPi-IIa, and the B2 subunit of the vacuolar H⁺-ATPase (not shown here) is reduced in the brush-border membrane of the proximal tubule in hypothyroid rats. This is accompanied by a lower abundance of the Na⁺/HCO₃⁻ cotransporter (NBCe1) and a higher expression of the acid-secretory type A intercalated cell-specific Cl⁻/HCO₃⁻ exchanger (AE1) in the connecting tubule and cortical collecting duct. NBCe1 expression and the number of α -intercalated cells increased in hypothyroid rats during metabolic acidosis.¹² ACII: carbonic anhydrase II.

However, most patients with both clinical conditions presented autoimmune hypothyroidism. This combination has been described both in adults^{20–22} and children^{23,24}; in one of these cases of RTA, serum levels of T3, T4 and TSH were normal,²² supporting the notion that, as in other autoimmune diseases, antithyroid antibodies can *per se* can have a negative effect on renal acidification capacity.^{6,7} There are several references in the literature to the triple association of RTA, hypothyroidism and another autoimmune disease such as diabetes mellitus²⁵ or Sjögren's syndrome.^{26,27} The fact that our second case was diagnosed with RTA 2 years after starting treatment with thyroid hormone supports the hypothesis that antithyroid antibodies have a negative effect on renal acidification capacity, although poor compliance with replacement treatment cannot be entirely ruled out. The pathophysiological mechanism of distal RTA associated with autoimmune disease is not well understood. In patients with Sjögren's syndrome, immunohistochemical studies have shown the absence of vacuolar H⁺-ATPase in collecting duct cells obtained from renal biopsies.²⁸ More recently, in the same disease, autoantibodies against carbonic anhydrase II enzymes have been described (Fig. 2).²⁹

The test used to determine maximum urinary pCO₂ in both our patients is a variant of the one previously described by our Group. In this challenge, acetazolamide and sodium bicarbonate are administered simultaneously at lower doses than usual, thus obtaining valid results (urinary HCO₃⁻ > 80 mEq/l) while avoiding significant side effects.^{4,30,31}

The loss of proximal bicarbonate reported in case 2 must be associated with a reduction in the activity of both the Na⁺/H⁺ exchanger (NHE3) and the Na⁺/HCO₃⁻ (NBCe1) cotransporter, as described above (Fig. 2).¹² However, being a type 3 RTA (proximal and distal) the patient could, theoretically, be a carrier of autoantibodies against carbonic anhydrase II, which is functional in both the proximal and distal portions of the nephron.

Conflicts of interest

The authors declare that they have no conflicts of interest.

REFERENCES

- Rodríguez-Soriano J. Renal tubular acidosis: the clinical entity. *J Am Soc Nephrol.* 2002;13:2160–70.
- Santos F, Ordoñez FA, Claramunt-Taberner D, Gil-Peña H. Clinical and laboratory approaches in the diagnosis of renal tubular acidosis. *Pediatr Nephrol.* 2015;30:2099–107.
- Escobar L, Mejía N, Gil H, Santos F. Distal renal tubular acidosis: a hereditary disease with an inadequate urinary H⁺ excretion. *Nefrología.* 2013;33:289–96.
- Guerra-Hernández NE, Ordaz-López KV, Escobar-Pérez L, Gómez-Tenorio C, García-Nieto VM. Distal renal tubular acidosis screening by urinary acidification testing in Mexican children. *Rev Invest Clin.* 2015;67:191–8.
- Battle D, Haque SK. Genetics causes and mechanisms of distal renal tubular acidosis. *Nephrol Dial Transplant.* 2012;27:3691–709.

6. Pessler F, Emery H, Dai L, Wu Y-M, Monash B, Cron R, et al. The spectrum of renal tubular acidosis in paediatric Sjögren syndrome. *Rheumatology*. 2006;45:85–91.
7. Bagga A, Jain Y, Srivastava RN, Bhuyan UN. Renal tubular acidosis preceding systemic lupus erythematosus. *Pediatr Nephrol*. 1993;7:735–6.
8. Mariani LH, Berns JS. The renal manifestations of thyroid disease. *J Am Soc Nephrol*. 2012;23:22–6.
9. Michael UF, Barenberg RL, Chavez R, Vaamonde CA, Papper S. Renal handling of sodium and water in the hypothyroid rat. Clearance and micropuncture studies. *J Clin Invest*. 1972;51:1405–12.
10. Schmitt R, Klussmann E, Kahl T, Ellison DH, Bachmann S. Renal expression of sodium transporters and aquaporin-2 in hypothyroid rats. *Am J Physiol Renal Physiol*. 2003;284:F1097–104.
11. Li X, Misik AJ, Rieder CV, Solaro RJ, Lowen A, Fliegel L. Thyroid hormone receptor alpha 1 regulates expression of the Na⁺/H⁺ exchanger (NHE1). *J Biol Chem*. 2002;277:28656–62.
12. Mohebbi N, Kovacicova J, Nowik M, Wagner CA. Thyroid hormone deficiency alters expression of acid-base transporters in rat kidney. *Am J Physiol*. 2007;293:F416–27.
13. Woo AL, Noonan WT, Schultheis PJ, Neumann JC, Manning PA, Lorenz JN, et al. Renal function in NHE3-deficient mice with transgenic rescue of small intestinal absorptive defect. *Am J Physiol Renal Physiol*. 2003;284:F1190–8.
14. Janecke AR, Heinz-Erian P, Yin J, Petersen BS, Franke A, Lechner S, et al. Reduced sodium/proton exchanger NHE3 activity causes congenital sodium diarrhea. *Hum Mol Genet*. 2015;24:6614–23.
15. Montenegro J, González O, Saracho R, Aguirre R, González O, Martínez I. Changes in renal function in primary hypothyroidism. *Am J Kidney Dis*. 1996;27:195–8.
16. Kreisman SH, Hennessey JV. Consistent reversible elevations of serum creatinine levels in severe hypothyroidism. *Arch Intern Med*. 1999;159:79–82.
17. Oster JR, Micheal UF, Perez GO, Sonneborn RE, Vaamonde CA. Renal acidification in hypothyroid man. *Clin Nephrol*. 1976;6:398–403.
18. Fang JT, Huang CC. Distal renal tubular acidosis associated with non-autoimmune hypothyroidism. *Nephrol Dial Transplant*. 1996;11:1146–7.
19. Laway BA, Ali I, Bashir MI, Mir SA, Ganie MA, Wani IA. Distal renal tubular acidosis associated with non-autoimmune hypothyroidism. *Saudi J Kidney Dis Transpl*. 2012;23:846–9.
20. Mason AM, Golding PL. Renal tubular acidosis and autoimmune thyroid disease. *Lancet*. 1970;2:1104–7.
21. Basak RC, Sharkawi KM, Rahman MM, Swar MM. Distal renal tubular acidosis, hypokalemic paralysis, nephrocalcinosis, primary hypothyroidism, growth retardation, osteomalacia and osteoporosis leading to pathological fracture: a case report. *Oman Med J*. 2011;26:271–4.
22. Koul PA, Wahid A. Distal renal tubular acidosis and hypokalemic paralysis in a patient with hypothyroidism. *Saudi J Kidney Dis Transpl*. 2011;22:1014–6.
23. Drukker A, Dolberg M, Landau H. Renal tubular acidosis in a patient with hypothyroidism due to autoimmune thyroiditis. Improvement with hormone replacement therapy. *Int J Pediatr Nephrol*. 1982;3:205–9.
24. Spahiu L, Jashari H, Mulliqi-Kotori V, Elezi-Rugova B, Merovci B. Hashimoto thyroiditis and nephrocalcinosis in a child with Down syndrome. *Acta Inform Med*. 2016;24:143–5.
25. Maeng M, Pedersen KM. A young woman with metabolic acidosis and recently detected IDDM without ketonuria. A rare autoimmune (?) combination of hypothyroidism, diabetes mellitus and distal renal tubular acidosis. *Ugeskr Laeger*. 1998;160:5663–4.
26. Bouchhima C, Mnif M, Jarraya F, Rekik N, Hachicha J, Abid M. Association of distal tubular acidosis, Hashimoto's thyroiditis and Gougerot-Sjögren's syndrome. *Presse Med*. 2003;32:1410–2.
27. Agarwal A, Kumar P, Gupta N. Pediatric Sjögren syndrome with distal renal tubular acidosis and autoimmune hypothyroidism: an uncommon association. *CEN Case Rep*. 2015;4:200–5.
28. Takemoto F, Hoshino J, Sawa N, Tamura Y, Tagami T, Yokota M, et al. Autoantibodies against carbonic anhydrase II are increased in renal tubular acidosis associated with Sjögren syndrome. *Am J Med*. 2005;118:181–4.
29. DeFranco PE, Haragsim L, Schmitz PG, Bastani B. Absence of vacuolar H⁺-ATPase pump in the collecting duct of a patient with hypokalemic distal renal tubular acidosis and Sjögren's syndrome. *J Am Soc Nephrol*. 1995;6:295–301.
30. García Nieto V, Hernández-González MJ, Hernández-Hernández L, Monge M, Molini N. A new combined test to study the maximum urinary pCO₂ in the pediatric age. *Pediatr Nephrol*. 2002;17:C8.
31. Guerra-Hernández N, Matos-Martínez M, Ordaz-López KV, Camargo-Muñoz MD, Medeiros M, Escobar-Pérez L. Clinical and biochemical findings in Mexican patients with distal renal tubular acidosis. *Rev Invest Clin*. 2014;66:386–92.