

REFERENCES

- Motzer RJ, Tannir NM, McDermott DF, Arén Frontera O, Melichar B, Choueiri TK, et al. Nivolumab plus ipilimumab versus sunitinib in advanced renal-cell carcinoma. *N Engl J Med.* 2018;378:1277-90.
- Cortazar FB, Marrone KA, Troxell ML, Ralton KM, Hoenig MP, Brahmer JR, et al. Clinicopathological features of acute kidney injury associated with immune checkpoint inhibitors. *Kidney Int.* 2016;90:638-47.
- Kitchlu A, Fingrut W, Avila-Casado C, Chan CT, Crump M, Hogg D, et al. Nephrotic syndrome with cancer immunotherapies: a report of 2 cases. *Am J Kidney Dis.* 2017;70:581-5.
- Daanen RA, Mass RJH, Steenbergen EJ, van Herpen CML, Willemsen AECAB. Nivolumab-associated nephrotic syndrome in a patient with renal cell carcinoma: a case report. *J Immunother.* 2017;40:345-8.
- Kidd JM, Gizaw AB, Ipilimumab-associated minimal-change disease. *Kidney Int.* 2016;89:720.
- Reiser J, von Gersdorff G, Loss M, Oh J, Asanuma K, Giardino L, et al. Induction of B7-1 in podocytes is associated with nephrotic syndrome. *J Clin Invest.* 2004;113:1390-7.

Beatriz Redondo^a, Candela Moliz^a, Marina Alonso^b, Luis Paz-Ares^c, Manuel Praga^a, Enrique Morales^{a,*}

^a Servicio de Nefrología, Hospital Universitario 12 de Octubre, Madrid, Spain

^b Servicio de Anatomía Patológica, Hospital Universitario 12 de Octubre, Madrid, Spain

^c Servicio de Oncología, Hospital Universitario 12 de Octubre, Madrid, Spain

* Corresponding author.

E-mail address: emoralesr@senefro.org (E. Morales).

2013-2514/© 2018 Sociedad Española de Nefrología. Published by Elsevier España, S.L.U. This is an open access article under the CC BY-NC-ND license (<http://creativecommons.org/licenses/by-nc-nd/4.0/>).

<https://doi.org/10.1016/j.nefro.2018.05.005>

A case report of cyanotic nephropathy[☆]

Nefropatía por cianosis. A propósito de un caso

Dear Editor,

Cyanosis nephropathy is an infrequent and not well known condition, so the description of a case should be of interest.

A 49-year-old man attended outpatient clinic for proteinuria. He was diagnosed with tricuspid atresia in his early childhood, treated surgically with classic Glenn intervention (anastomosis of the superior vena cava to the right pulmonary artery) at 20 months of age, and in a second intervention by means of Blalock-Taussig pulmonary systemic fistula left (GORE-TEX[®] graft prosthesis from the subclavian artery to the homolateral pulmonary artery), which subsequently had to be repaired with an endovascular stent due to stenosis. He had moderate left ventricular dysfunction with chronic cyanosis, with habitual Hb values of 17 g/dl and Hct of 60%. Moderate thrombocytopenia and transient ischemic attack 10 years earlier, after which antiaggregation with ASA was replaced by clopidogrel. Regular treatment included clopidogrel, allopurinol and bosentan. In addition, he had periodic phlebotomies until 2 years ago when they were suspended at the discretion of their cardiologists. The patient consulted for a proteinuria of unknown time of evolution. Normal blood pressure with a BMI of 23 kg/m². In the analytic, Cr 0.78 mg/dl with estimated glomerular filtration rate by CKD-

EPI greater than 90 ml/min/1.73 m², Hb 23.8 g/dl; Hct of 80.8%; platelets 89,000/ml; uric acid 7.9 mg/dl; cholesterol 257 mg/dl; systematic urine with minimal microhematuria; MAu/Cru 3371.4 mg/g and proteinuria of 6.21 g/24 h of mixed type. Negative viral serology. Negative immunology tests including complement, ANA, ANCA, anti-DN, anti-phospholipase and anti-PLA2R antibodies. Immunoglobulins and proteinogram were normal. Abdominal ultrasound with kidneys of conserved size and bilateral diffuse hyper echogenicity as the only finding that that was noteworthy.

Since 1960,¹ it has been known that between 30 and 50% of cyanotic heart diseases can be the cause of a secondary glomerulopathy known as cyanosis nephropathy.² It is a correlate of cardiorenal syndrome type 2. It is produced through different mechanisms (Fig. 1)³⁻⁵ initiated by hyperviscosity syndrome secondary to extreme polycythemia and cyanosis, which cause an increase in shear stress by passing a high number of red blood cells through the capillary unit in the glomerulus. The subsequent decrease in renal blood flow and filtration fraction induce hypoxia, with an angiogenic response mediated by the release of nitric oxide, selective vasodilatation of the afferent arteriole and increased capillary pressure, which determines glomerular hyperfiltration. The decrease in peritubular capillary blood flow also contributes

DOI of original article:

<https://doi.org/10.1016/j.nefro.2018.05.001>.

[☆] Please cite this article as: Ortega-Díaz M, Puerta Carretero M, Corchete E, Martín Navarro JA, Jaldo MT, Albalade M, et al. Nefropatía por cianosis. A propósito de un caso. *Nefrología.* 2019;39:96-98.

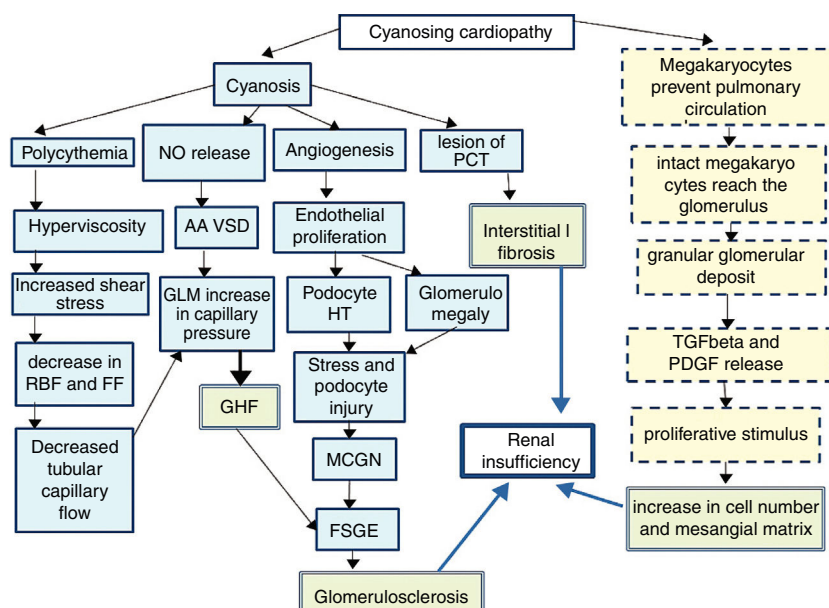


Fig. 1 – Pathophysiology of cyanotic nephropathy.

FF: filtration fraction; **RBF:** renal blood flow; **FSGE:** focal and segmental glomerulosclerosis; **GLM:** glomerulus; **MCGN:** minimal change glomerulonephritis; **GHF:** glomerular hyperfiltration; **HT:** hypertrophy; **PDGF:** platelet derived growth factor; **PCT:** proximal convoluted tubule; **TGFβ:** tumor growth factor β; **AA VSD:** arteriolar afferent vasodilation.

Continuous line: pathway of vascular damage; **broken line:** path of proliferative damage; **double grid:** path of final damage.

to increase in capillary pressure. In parallel, cyanosis triggers an angiogenic stimulus with an increase in the number of capillaries per glomerulus, glomerulomegaly due to endothelial proliferation and an increase in the surface area of the glomerular capillary, the podocyte stretches and it is hypertrophied due to stress and there is a damage that mimics glomerulonephritis due to minimal changes and subsequently to segmental glomerulosclerosis.⁶

It is accepted that the initial damage is in the tubule,^{7–9} especially in the proximal tubule, as reflected by an increase in urinary N-acetyl glucosamine and α1-microglobulin that usually occurs in the first decade of life and continue in the next decade with a glomerular damage (albuminuria, proteinuria and decrease in glomerular filtration). As the mechanism of compensating glomerular hyperfiltration is exhausted, a glomerular hyalinosis develops with glomerulosclerosis and interstitial fibrosis that will condition the midterm prognosis. A different injury is distinguished in small vessels resulting from capillary dilation, thickening or endothelial destruction, glomerulosclerosis and periglomerular fibrosis mediated by a non-vascular proliferative mechanism, resulting from the shunt in the pulmonary circulation. Under normal conditions, after being released from the spleen and bone marrow, a population of megakaryocytes are retained in the interstitium and in the pulmonary vasculature^{5,10,11} where they disaggregate forming active platelets at a rate of 10⁶/h. However in conditions of right/left shunt this step is avoided and the megakaryocytes pass intact to the systemic circulation making possible that their alpha granules, rich in PDGF and in TGFβ, reach the renal glomerulus and be released, producing 2 effects. A peripheral thrombocytopenia that indirectly quantifies the degree of shunt (the greater thrombocytopenia, the greater shunt) and an increase of proliferative platelet factors

that will cause an increase in mesangial juxtaglomerular cells, mesangial matrix and focal interstitial fibrosis.

The hematocrit level, the delay until shunt surgery and a platelet level of less than 250,000/ml are risk factors for the appearance of nephropathy.^{3,12,13}

The treatment consists of reducing surgical waiting times, periodic phlebotomies and inhibition of the renin-angiotensin-aldosterone axis with ACE inhibitors.¹⁴

Renal prognosis is unfavorable if the cause is not resolved. In our case, we began treatment with statins and ACEIs, and periodic phlebotomies were again recommended without sufficient follow-up to evaluate the response at the present time.

REFERENCES

1. Spear GS. Glomerular alterations in cyanotic congenital heart disease. *Bull Johns Hopkins Hosp.* 1960;106:347–67.
2. Holt T, Filler G. Is it time for a multi-specialty approach to cardio-renal dysfunction in children with cyanotic congenital heart disease? *Pediatr Nephrol.* 2018;33:359–60.
3. Inatomi J, Matsuoka K, Fujimaru R, Nakagawa A, Iijima K. Mechanisms of development and progression of cyanotic nephropathy. *Pediatr Nephrol.* 2006;21:1440–5.
4. Dittrich S, Kurschat K, Lange PE. Abnormal rheology in cyanotic congenital heart disease – a factor in non-immune nephropathy. *Scand J Urol Nephrol.* 2001;35:411–5.
5. Perloff JK, Latta H, Barsotti P. Pathogenesis of the glomerular abnormality in cyanotic congenital heart disease. *Am J Cardiol.* 2000;86:1198–204.
6. Gupte PA, Vaideeswar P, Kandalkar BM. Cyanotic nephropathy – a morphometric analysis. *Congenit Heart Dis.* 2014;9:280–5.
7. Dittrich S, Kurschat K, Dähnert I, Vogel M, Müller C, Alexi-Meskishvili V, et al. Renal function after

- cardiopulmonary bypass surgery in cyanotic congenital heart disease. *Int J Cardiol.* 2000;73:173-9.
8. Zheng J, Yao Y, Han L, Xiao Y. Renal function and injury in infants and young children with congenital heart disease. *Pediatr Nephrol.* 2013;28:99-104.
 9. Agras PI, Derbent M, Ozcay F, Baskin E, Turkoglu S, Aldemir D, et al. Effect of congenital heart disease on renal function in childhood. *Nephron Physiol.* 2005;99:10-5.
 10. Barcat JA. Megakaryocytes platelets and a new lung function. *Medicina (B Aires).* 2017;77:344-6 [in Spanish].
 11. Lefrançois E, Ortiz-Muñoz G, Caudrillier A, Mallavia B, Liu F, Sayah DM, et al. The lung is the site of platelet biogenesis and a reservoir for haematopoietic progenitors. *Nature.* 2017;544:105-9.
 12. Hongawong N, Khamdee P, Silvilairat S, Chartapisak W. Prevalence and associated factors of renal dysfunction and proteinuria in cyanotic congenital heart disease. *Pediatr Nephrol.* 2018;33:493-501.
 13. Amoozgar H, Basiratnia M, Ghasemi F. Renal function in children with cyanotic congenital heart disease: pre- and post-cardiac surgery evaluation. *Iran J Pediatr.* 2014;24:81-6.
 14. Fujimoto Y, Matsushima M, Tsuzuki K, Okada M, Shibata M, Yanase Y, et al. Nephropathy of cyanotic congenital heart

disease: clinical characteristics and effectiveness of an angiotensin-converting enzyme inhibitor. *Clin Nephrol.* 2002;58:95-102.

Mayra Ortega-Díaz, Marta Puerta Carretero, Elena Corchete, Juan A. Martín Navarro*, M. Teresa Jaldo, Marta Albalade, Patricia de Sequera, Roberto Alcázar Arroyo

Servicio de Nefrología, Hospital Universitario Infanta Leonor, Madrid, Spain

* Corresponding author.

E-mail address: juanmartinnav@hotmail.com (J.A. Martín Navarro).

2013-2514/© 2018 Sociedad Española de Nefrología. Published by Elsevier España, S.L.U. This is an open access article under the CC BY-NC-ND license (<http://creativecommons.org/licenses/by-nc-nd/4.0/>). <https://doi.org/10.1016/j.nefro.2019.01.001>

Role of sustained low-efficiency dialysis in the intensive care unit[☆]

Papel de la diálisis sostenida de baja eficiencia en las unidades de cuidados intensivos

Dear Editor,

Sustained low-efficiency dialysis (SLED) is an intermittent hybrid renal replacement modality in between conventional intermittent haemodialysis (IHD) and continuous renal replacement therapy (CRRT).¹ The superiority of continuous techniques compared to conventional intermittent techniques with regard to haemodynamic tolerance in critically ill patients has not been demonstrated,^{2,3} meaning that the choice of modality depends on the availability thereof and on the experience of the doctor the prescribe the modality of treatment. However, the clinical experience is that approximately two-thirds of IHD sessions in critically ill patients are not well tolerated,⁴ requiring the use of continuous techniques.

We present the experience of using SLED in a tertiary hospital where both modalities are available, and in which the prescription of both continuous and intermittent techniques depends on the Nephrology Department.

The objective of our study was to describe the characteristics of patients who received SLED-type renal replace-

ment therapy in intensive care units due to a non-standardised indication by the Nephrology specialist. As secondary objectives, we proposed to assess complications in relation to haemodynamic tolerance and electrolytes abnormalities.

A retrospective study was therefore conducted using the registry of patients in intensive care units treated with SLED between 2014 and 2016, including those who received it as the first therapeutic option, immediately after receiving CRRT or after IHD. The technique included a QB 100-150 ml/min, QD 200-250 ml/min and a dialysis time of 7-8 h. The presence of haemodynamic instability in a session was defined as the need to start or increase vasoactive drugs during the session according to the nursing record, a fall in systolic blood pressure <90 mmHg when values were greater than 90 mmHg at the start of the session or a decrease of >25% in systolic or diastolic blood pressure during the session. Mortality was defined as deaths which occurred during hospital admission.

A total of 54 patients were analysed, of which 26 received the technique after IHD, 11 as the first therapeutic option and

DOI of original article:
<https://doi.org/10.1016/j.nefro.2018.06.002>.

[☆] Please cite this article as: Molina-Andújar A, Blasco M, Poch E. Papel de la diálisis sostenida de baja eficiencia en las unidades de cuidados intensivos. *Nefrologia.* 2019;39:98-99.