

Letters to the Editor

Calcium of 28 mg/dl in patient of 4 days of life. Urgent treatment and follow-up[☆]

Calcio de 28 mg/dl en paciente de 4 días de vida. Tratamiento urgente y seguimiento posterior

Dear Editor,

We present an unusual case of severe hypercalcemia of neonatal onset.

Patient of 4 days of life brought to the Emergency Department for constipation of 48 h. Good oral tolerance and appetite. Hypotonic with good response to stimuli, without other symptoms. There is no family or personal background of interest.

Blood test with blood count, leukocyte formula and normal platelet levels; capillary gasometry and blood biochemistry with discrete metabolic acidosis: pH 7.33, bicarbonate 19.2 and ionic calcium 4.84 mmol/l confirmed with serum calcium: 28.1 mg/dl. Given the findings of severe hypercalcemia, enter the pediatric intensive care unit to complete the study.

On admission, figures of parathormone (PTH) > 5000 pg/ml were obtained (high limit of normality for age 78 pg/ml), figures compatible with severe neonatal primary hyperparathyroidism. Normal thyroid activity. Noteworthy vitamin D deficiency (VitD): 16 ng/ml; in probable relationship with maternal deficit.

In the radiological study, incipient osteopenia and cardiology showed a short corrected "Qt" interval, with rest of values and structurally normal heart.

Abdominal ultrasound showed evidence of right renal nephrocalcinosis without other findings; and the thyroid ultrasound showed no hyperplasia or glandular adenomas.

We performed thyroid scintigraphy that surprisingly objectified the physiological distribution of the tracer. In the presence of severe hypercalcemia due to suspicion of severe primary neonatal hyperparathyroidism (NSHPT), an urgent treatment is initiated with: abundant hydration (physiological saline at 100/m²/H); extrarenal purification therapy; furosemide (1 mg/kg/day); systemic corticosteroid

(methylprednisolone 2 mg/kg/day); calcitonin (5 UI/kg/day); and pamidronate (1 mg/kg/day). Requires mechanical ventilation for the first 48 h. This treatment is effective, with normalization of calcium values (2.43 mmol/l of Ca ionic) in the first 48 h and PTH level of decrease (after 5 days of treatment, 2044 pg/ml) (Fig. 1).

After these results, treatment reduction was initiated, confirming a new increase in ionic calcium levels (maximum 2.1 mmol/l and 11 mg/dl), forcing it to restart.

At 12 days of age, she was transferred to a child ENT service where she underwent total parathyroidectomy, with intraoperative diagnostic confirmation of visu. They were removed 6 orthotopic parathyroid glands all of them, reimplanting one in the forearm, apparently not functioning. Objective to the contrary, in the last analytical control, figures of PTH in ascent (12.1 pg/ml) that could show restart of activity, not enough for the moment for the adequate maintenance of phosphocalcic metabolism.

The reimplanted parathyroid glands may take up to restart their activity between 6 and 12 months, according to the literature described. However, we could consider the increase of this range of waiting to check the progressive rise and recovery in patients several months beyond the intervention, as in our case, after 16 months of the reimplantation.

The subsequent genetic study revealed a double mutation in heterozygosis of the "CaSR" gene. Diagnosing symptomatic severe neonatal hyperparathyroidism.

After the intervention, the patient presented progressive hypocalcemia, without renal losses; together hypophosphoremia and hypomagnesemia. Compatible with "hungry bone syndrome", treatment is started with 1,25 hydroxyvitamin D3 (calcitriol, 0.50 mcgr/day) and calcium supplements (calcium carbonate 1000 mg/day orally and calcium gluconate 216 mg/day orally, with total calcium contributions of 345 mg/kg/day) together with phosphorus and magnesium.

DOI of original article:

<https://doi.org/10.1016/j.nefro.2018.12.041>.

[☆] Please cite this article as: Segura González M, Carrasco Hidalgo-Barquero MC, Hidalgo-Barquero del Rosal E. Calcio de 28 mg/dl en paciente de 4 días de vida. Tratamiento urgente y seguimiento posterior. Nefrología. 2019;39:552-554.

PTH intacta Bioquímica					
9 observaciones encontradas					
	Fecha/Hora	Valor	Unidad	Rango	
	16/06/2017 09:52:00	>5.000	pg/ml	(11.5-78.4)	
	21/06/2017 10:37:23	2.044.3	pg/ml	(11.5-78.4)	
	21/06/2017 10:37:23	2.044.3	pg/ml	(11.5-78.4)	
	21/06/2017 10:37:23	2.044.3	pg/ml	(11.5-78.4)	
	19/07/2017 10:45:10	64.7	pg/ml	(11.5-78.4)	
	17/08/2017 08:41:09	<7	pg/ml	(11.5-78.4)	
	27/12/2017 08:35:14	<7	pg/ml	(11.5-78.4)	
	16/05/2018 12:43:15	<6	pg/ml		
	17/09/2018 12:56:39	12.1	pg/ml		

Evolución de PTH intacta

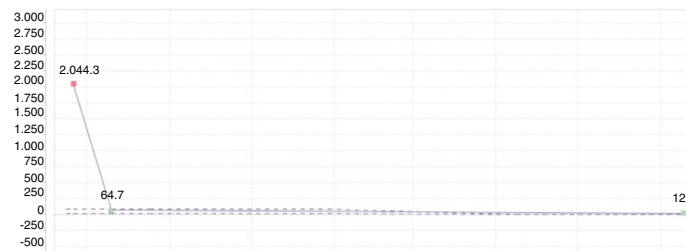


Fig. 1 – Evolutionary figures of parathyroid hormone.

Currently the patient is 15 months old, is asymptomatic and evolves favorably. The main sequelae is a permanent hypoparathyroidism with hypocalcemia and diffuse osteopenia, in maintenance treatment with calcium supplements, cholecalciferol and calcitriol.

The presentation of severe neonatal hyperparathyroidism is diverse; from asymptomatic cases to respiratory symptoms, neurological, failure of the plan etc. A comprehensive differential diagnosis is necessary (Fig. 2).¹

There is no “gold standard” diagnostic test and the imaging tests have proved ineffective, with a high false negative rate.

The treatment is fundamentally based on:

- The urgent and vital correction of high levels of hypercalcemia with hyperhydration, calcimimetics (cinacalcet), bisphosphonates (pamidronate), diuretics (furosemide) and corticosteroid therapy (methylprednisolone).
- Surgical etiological treatment.
- Treatment of subsequent sequelae: hypocalcemia and hungry bone syndrome; treated with 25OH-vitamin D3 (calcitriol/alfacalcidol) and calcium (calcium gluconate and carbonate).

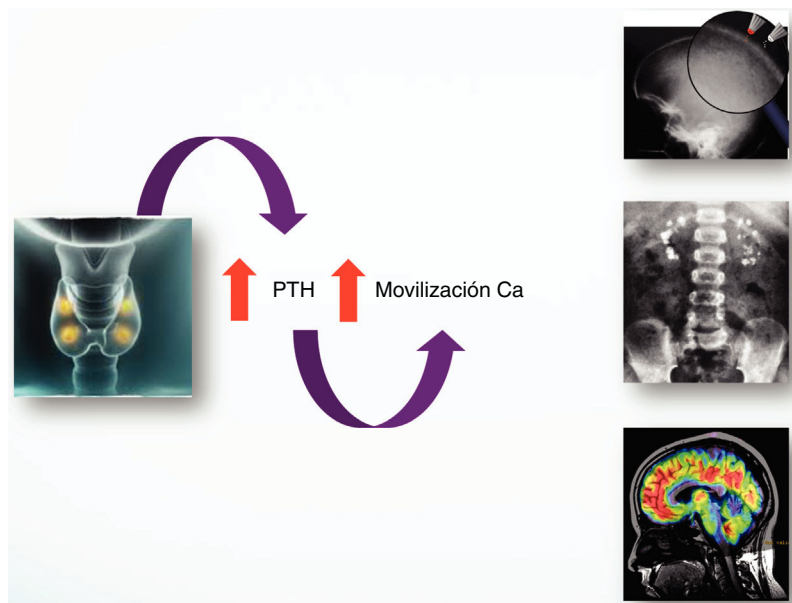


Fig. 2 – Clinical repercussion of hyperparathyroidism.

The existence of a biological marker that determines the favorable response or not to medical treatment, would save unnecessary pharmacotherapy periods. However, there is currently no such parameter.^{1,2} Therefore, surgical treatment is of choice when adequate control with pharmacotherapy is not achieved, as in our case.

As for the genetic study, mutations in the CASR gene of the parathyroid cells are related to alteration of calcium homeostasis. This receptor records calcium levels in the blood. Its mutation causes the insensibility of these cells to the variations of calcemia, generating an increase in PTH and glandular hyperplasia. This mutation is observed in hyperplasia, adenomas and NSHPT.

In our patient, DNA amplification was carried out by PCR of the CASR gene, detecting two changes in heterozygosis. The c.73C>T mutation had already been previously described, however, the second mutation found; c.1981T>C, is "novo" and probably pathogenic.

More than half of cases of hyperparathyroidism in children reported in the literature show family history; in our patient, the study of progenitors, revealed absence of mutations in the father and c.73C>T mutation in the mother. Many authors defend that family screening could be effective and efficient in the control of the disease.³

In conclusion, NSHPT should be considered in the differential diagnosis of newborns with hypercalcemia. The initial medical treatment will be vital for the patient, determining the need or not of subsequent surgical treatment. It is essential to establish the genetic diagnosis as well as a lifelong medical follow-up.

REFERENCES

1. Atay Z, Bereket A, Haliloglu B, Abali S, Ozdogan T, Altuncu E, et al. Novel homozygous inactivating mutation of the calcium-sensing receptor gene (CASR) in neonatal severe hyperparathyroidism-lack of effect of cinacalcet. *Bone*. 2014;64:102-7.
2. Gannon AW, Monk HM, Levine MA. Cinacalcet monotherapy in neonatal severe hyperparathyroidism: a case study and review. *J Clin Endocrinol Metab*. 2014;99:7-11.
3. Alagaratnam S, Kurzwinski TR. Aetiology, diagnosis and surgical treatment of primary hyperparathyroidism in children: new trends. *Horm Res Paediatr*. 2015;83:365-75.

María Segura González*,
Marta Cecilia Carrasco Hidalgo-Barquero,
Emilia Hidalgo-Barquero del Rosal

Servicio de Pediatría, Hospital Materno-Infantil, Badajoz, Spain

* Corresponding author.

E-mail address: maria.segura.gonzalez@gmail.com
(M. Segura González).

2013-2514/© 2019 Sociedad Española de Nefrología. Published by Elsevier España, S.L.U. This is an open access article under the CC BY-NC-ND license (<http://creativecommons.org/licenses/by-nc-nd/4.0/>).

<https://doi.org/10.1016/j.nefro.2019.06.002>

Comments on "The value of ABPM and subclinical target organ damage parameters in diagnosis of resistant hypertension" by Poveda Garcia MI, et al., NEFROLOGÍA journal, 13 March 2018[☆]

Comentario al artículo publicado «El valor de la MAPA y de los parámetros de lesión subclínica de órgano diana en el diagnóstico de hipertensión refractaria» por Poveda García MI, et al., revista de NEFROLOGÍA, 13 de marzo del 2018

Dear Editor,

We read with great interest the article "The value of ABPM and subclinical target organ damage parameters in diagnosis

of resistant hypertension",¹ and we believe that it is a very important contribution to the study of patients with difficult hypertension management and for the prevention of the secondary damage that this can lead to. However, we believe there are certain points they should take into account to improve their article. We have listed them below.

DOI of original article:

<https://doi.org/10.1016/j.nefro.2018.12.040>.

[☆] Please cite this article as: Collazos-Huaman L, Guerreros-Espino C. Comentario al artículo publicado «El valor de la MAPA y de los parámetros de lesión subclínica de órgano diana en el diagnóstico de hipertensión refractaria» por Poveda García MI, et al., revista de NEFROLOGÍA, 13 de marzo del 2018. *Nefrología*. 2019;39:554-555.