

REFERENCES

- Vázquez-Rodríguez JG. Hemodiálisis y embarazo: aspectos técnicos. *Cir Cir.* 2010;78:99-102.
- Vázquez-Rodríguez JG. Diálisis peritoneal y embarazo. *Cir Cir.* 2010;78:181-7.
- Briones-Garduño JC, Díaz de León-Ponce MA, Rodríguez-Roldán M, Briones-Vega CG, Torres-Pérez J. Diálisis peritoneal en pacientes obstétricas. *Cir Cir.* 2006;74:15-20.
- Norma Oficial Mexicana NOM-152-SSA1-1996, que establece las especificaciones sanitarias de los catéteres rígidos para diálisis peritoneal infantil y adulto. México: Secretaría de Salud; 1996. Available from: <http://www.salud.gob.mx/unidades/cdi/nom/152ssa16.html> [accessed 06.02.19].
- Tratamiento sustitutivo de la función renal. Diálisis y hemodiálisis en la insuficiencia renal crónica. México: Secretaría de Salud; 2014. Available from: <http://www.cenetec.salud.gob.mx/descargas/gpc/CatalogoMaestro/IMSS-727-14-DialisisyhemodialisisIRC/727GER.pdf> [accessed 06.02.19].
- Sansone G, Cirugeda A, Bajo MA, del Peso G, Sánchez-Tomero JA, Alegre L, et al. Clinical practice protocol update in peritoneal dialysis – 2004. *Nefrologia.* 2004;24:410-45.
- Pons-Ódena M, Ruiz García-Diego S, Esteban-Torné E. Diálisis peritoneal. *An Pediatr Contin.* 2006;4:129-33.

Juan Gustavo Vázquez-Rodríguez

Unidad de Cuidados Intensivos, Unidad Médica de Alta Especialidad Hospital de Ginecología y Obstetricia No. 3, Centro Médico Nacional La Raza, Instituto Mexicano del Seguro Social, Ciudad de México, Mexico

E-mail address: juangustavovazquez@hotmail.com

2013-2514/© 2019 Published by Elsevier España, S.L.U. on behalf of Sociedad Española de Nefrología. This is an open access article under the CC BY-NC-ND license (<http://creativecommons.org/licenses/by-nc-nd/4.0/>). <https://doi.org/10.1016/j.nefro.2018.11.017>

IgA dominant postinfectious glomerulonephritis secondary to cutaneous infection by methicillin-resistant *Staphylococcus aureus*☆

Glomerulonefritis postinfecciosa IgA dominante secundaria a infección cutánea por *Staphylococcus aureus* resistente a meticilina

To the Editor,

IgA-dominant postinfectious glomerulonephritis (IgA-PIGN), a morphological variant of PIGN, is increasingly common in our setting. Unlike classical post-streptococcal PIGN, which involves C3 and IgG or only C3 deposition, IgA is the sole or dominant immunoglobulin in IgA PIGN.¹ Most cases are concurrent with a *Staphylococcus aureus* infection, especially cutaneous, although they are also associated with coagulase-negative staphylococci and, rarely, gram-negative bacilli. IgA-PIGN has a predilection for older men, with various comorbidities, mainly diabetes mellitus, but also tumours, alcoholism or HIV infection.² IgA-PIGN is more aggressive than the standard variant, has a poor prognosis, and in the majority of cases (70-80%) starts with acute kidney injury, proteinuria, haematuria and hypocomplementaemia. The differential diagnosis should be made with post-streptococcal PIGN and with IgA nephropathy.³ Treatment is based on the eradication

of the infection and general support measures, there being little evidence to justify immunosuppressive treatment.

We present the case of a 70-year-old man with IgA PIGN secondary to cutaneous MRSA infection, which began with severe acute kidney injury. His medical history was only significant for hypertension and a traumatic right fibular fracture associated with compartment syndrome and rhabdomyolysis 5 months earlier, which had required several sessions of isolated haemodialysis, with recovery of renal function (at discharge, creatinine was 1.09 mg/dl).

He was admitted to the Plastic Surgery Department 5 months later due to infection of the wound and MRSA osteomyelitis in the right foot, which was complicated by a *Pseudomonas aeruginosa* superinfection. Antibiotic treatment was started with linezolid and piperacillin-tazobactam. At 2 weeks, he began to present foveal oedema in the legs, hypertension, progressive volume overload, macroscopic haematuria, and foamy urine. These symptoms were asso-

DOI of original article:

<https://doi.org/10.1016/j.nefro.2018.10.013>.

☆ Please cite this article as: Carbayo J, Rodríguez-Benitez P, Diaz-Crespo F, Muñoz de Morales A. Glomerulonefritis postinfecciosa IgA dominante secundaria a infección cutánea por *Staphylococcus aureus* resistente a meticilina. *Nefrologia.* 2019;39:446-448.

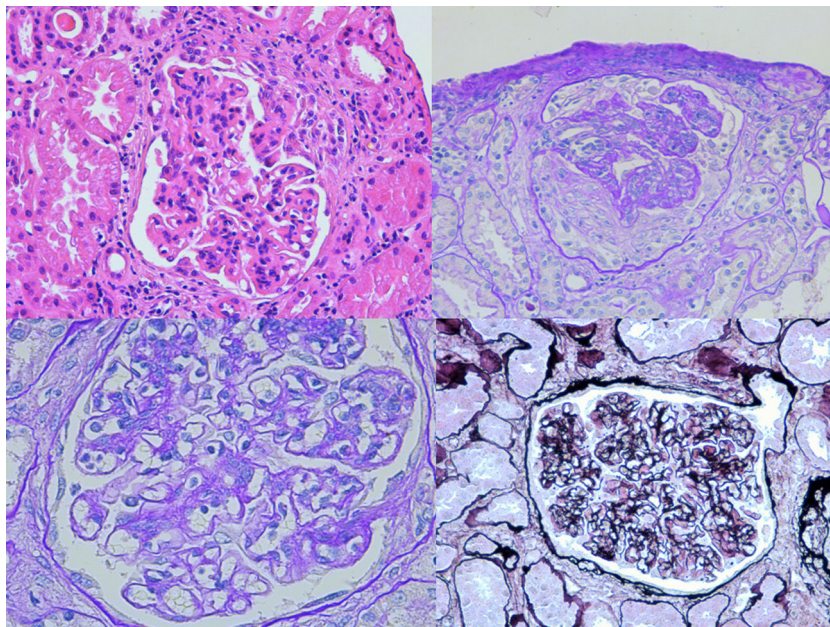


Fig. 1 – Optical microscopy: mesangial proliferation and endocapillary hypercellularity are observed. In addition, extracapillary proliferation with cellular crescents can be seen.

ciated with acute kidney injury, nephrotic-range proteinuria, and a tendency to hyperkalaemic metabolic acidosis. A renal ultrasound was performed, which showed kidneys of normal size and morphology, with adequate cortical differentiation. Serologies and the immunological study were completely negative (normal complement levels). Given the suspicion of a nephritic syndrome secondary to PIGN, the patient was initially managed conservatively with antibiotics, intravenous diuretics and antiproteinuric therapy with RAAS blockers. However, despite the good evolution of the infection, the deterioration of renal function persisted with creatinine levels of 3.54 mg/dl, microscopic haematuria and nephrotic range proteinuria (with a protein/creatinine index of 5.36 mg/mg), so it was decided to start treatment with corticosteroids at a dose of 1 mg/kg (prednisone 60 mg) and perform a renal biopsy.

The biopsy was compatible with IgA PIGN; it showed a global and diffuse expansion of the mesangial matrix, with a focal increase in mesangial cellularity, as well as an exudative pattern of the glomerular capillary loops. In addition, 17% of the glomeruli showed an extracapillary proliferation with cellular crescents (Fig. 1). In the direct immunofluorescence test, a granular pattern was observed at the mesangial level and in the walls of the glomerular capillaries, IgA (+++) and C3 (++), without restriction of light chains, being negative for IgG, IgM, C1q and fibrinogen (Fig. 2). Although in our case it was not done, in IgA PIGN, electron microscopy usually shows electron-dense subepithelial “humps” and mesangial deposits.^{1,4}

Evolution with corticoid treatment was adequate, with a decrease in proteinuria (protein/creatinine index of 0.7 mg/mg), good blood pressure control, resolution of oedema and improvement of renal function (creatinine level at discharge was 2.08 mg/dl), although microscopic haematuria persisted. After completing 8 weeks of antibiotic treatment

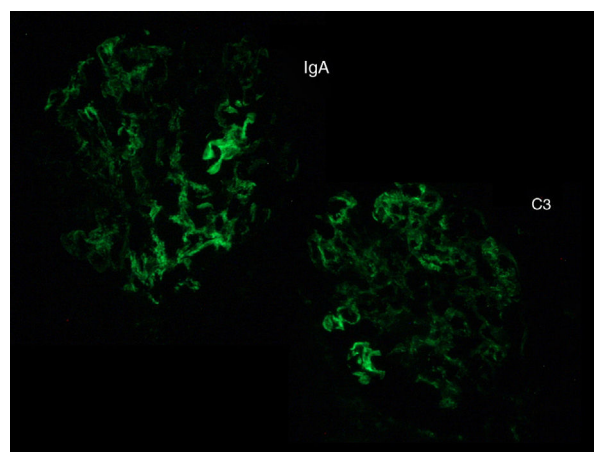


Fig. 2 – Direct immunofluorescence: mesangial deposit of IgA (+++) and C3 (++)

for osteomyelitis and performing a graft in the wound area, he was discharged on a tapering corticosteroids regimen.

Based on the data available in the literature, there is no evidence for the use of steroids in the treatment of IgA PIGN. In fact, the use of immunosuppressants can increase mortality in patients with active infection. Therefore, initial management should be based on the aetiological treatment with antibiotic therapy and general measures for the control of oedema and blood pressure, following the same regimen as in similar diseases (salt restriction, loop diuretics and use of RAAS blockers).^{1,5}

However, treatment with corticosteroids should be considered in IgA PIGN that presents with acute kidney injury and with no improvement after adequate antibiotic treatment.

Only a few case series have been published in which steroid treatment improves renal prognosis.^{5,7} In the case presented here, after the failure of antibiotic therapy, an acceptable response to steroid treatment was observed, with progressive improvement in renal function.

REFERENCES

1. Nasr SH, D'Agati VD. IgA-dominant postinfectious glomerulonephritis: a new twist on an old disease. *Nephron Clin Pract.* 2011;119:c18-26.
2. Nasr SH, Radhakrishnan J, D'Agati VD. Bacterial infection-related glomerulonephritis in adults. *Kidney Int.* 2013;83:792-803.
3. Satoskar AA, Nadasdy G, Plaza JA, Sedmak D, Shidham G, Hebert L, et al. *Staphylococcus* infection-associated glomerulonephritis mimicking IgA nephropathy. *Clin J Am Soc Nephrol.* 2006;1:1179-86.
4. Nasr SH, Fidler ME, Valeri AM, Cornell LD, Sethi S, Zoller A, et al. Postinfectious glomerulonephritis in the elderly. *J Am Soc Nephrol.* 2011;22:187-95.
5. Anand M, Arroyo JP, Alhalabi H, Thayer T, Lusco M, Langone A, et al. IgA-dominant acute postinfectious glomerulonephritis presenting as acute renal failure in a kidney transplant recipient. *Kidney Int Rep.* 2017;2:766-9.
6. Nasr SH, Markowitz GS, Stokes MB, Said SM, Valeri AM, D'Agati VD. Acute postinfectious glomerulonephritis in the modern era: experience with 86 adults and review of the literature. *Medicine (Baltimore).* 2008;87:21-32.
7. Bu R, Li Q, Duan ZY, Wu J, Chen P, Chen XM, et al. Clinicopathologic features of IgA-dominant infection-associated glomerulonephritis: a pooled analysis of 78 cases. *Am J Nephrol.* 2015;41:98-106.

Javier Carbayo^{a,*}, Patrocinio Rodríguez-Benitez^a,
Francisco Díaz-Crespo^b, Alejandra Muñoz de Morales^a

^a Servicio de Nefrología, Hospital General Universitario Gregorio Marañón, Madrid, Spain

^b Servicio de Anatomía Patológica, Hospital General Universitario Gregorio Marañón, Madrid, Spain

* Corresponding author.

E-mail address: jcarbayo92@gmail.com (J. Carbayo).

2013-2514/© 2019 Sociedad Española de Nefrología. Published by Elsevier España, S.L.U. This is an open access article under the CC BY-NC-ND license (<http://creativecommons.org/licenses/by-nc-nd/4.0/>).

<https://doi.org/10.1016/j.nefro.2018.10.015>

Acute renal failure secondary to rhabdomyolysis in a patient receiving treatment with ticagrelor and atorvastatin[☆]

Fracaso renal agudo secundario a rabdomiólisis en paciente en tratamiento con ticagrelor y atorvastatina

To the Editor:

In conditions of acute ischaemic heart disease, both American and European guidelines recommend double antiplatelet therapy with ticagrelor or prasugrel and acetylsalicylic acid together with administration of high or moderate intensity statins.¹ The risk of rhabdomyolysis with statins is considered to be 1/10⁵ patients/year,² although the risk of myopathy is 1/10³-10⁴/patients/year, and it is multiplied 5 times if 2 drugs are combined.³ We present a case of rhabdomyolysis in relation to atorvastatin and ticagrelor.

A 69-year-old woman with preserved renal function. Chronic type 2 diabetes mellitus, without diabetic retinopathy or nephropathy. Severe chronic ischaemia of the lower limbs. Hypertension, morbid obesity and mix dyslipidaemia. Chronic consumer of NSAIDs. In treatment with insulin, ARBs,

thiazide and ibuprofen. She was admitted for Killip III NSTEMI due to non-revascularisable 3-vessel disease. After optimising medical treatment, she improved slowly despite several infectious complications and severe deconditioning syndrome. At 4 weeks, without any triggering trauma, she developed generalised muscle pain with CPK levels of 27,000 U/L. During the previous week, she had been treated with 90 mg/day of ticagrelor, omeprazole, paracetamol, 40 mg/day of atorvastatin, amlodipine and duloxetine. Viral serology, thyroid profile, ACTH, cortisol, complete immunology, tumour markers, paracetamol levels, vitamin B₁₂ and serum folic acid were all normal. There were no symptoms of serotonin syndrome or acute adrenal insufficiency. All drugs were discontinued and clopidogrel was added to the treatment. The patient developed heart failure with oliguric renal failure and hyperkalaemia, which required 4 sessions of acute haemodialysis. She quickly regained renal function and improved clinically, but on the

DOI of original article:

<https://doi.org/10.1016/j.nefro.2018.10.012>.

[☆] Please cite this article as: Martín Navarro JA, Gutiérrez Sánchez MJ, Petkov Stoyanov V, Jiménez Herrero MC. Fracaso renal agudo secundario a rabdomiólisis en paciente en tratamiento con ticagrelor y atorvastatina. *Nefrología.* 2019;39:448-450.