

3. Weigert A, Querido S, Carvalho L, Lebre L, Chagas C, Matias P, et al. Hepatitis C virus eradication in kidney transplant recipients: a single-center experience in Portugal. *Transplant Proc.* 2018;50:743–5.
4. Meer AJ, Van Der, Veldt BJ, Feld JJ, Wedemeyer H, Dufour J-F. Association between sustained virological response and all-cause mortality among patients with chronic hepatitis c and advanced hepatic fibrosis. *JAMA.* 2012;308:2584–93.
5. Pawlotsky JM, Negro F, Aghemo A, Berenguer M, Dalgard O, Dusheiko G, et al. EASL recommendations on treatment of hepatitis C 2018. *J Hepatol.* 2018;69:461–511.

Rita Calça^{a,*}, Cristina Jorge^a, Luís Lebre^b, Eunice Cacheira^a, Sara Querido^a, Célia Nascimento^a, Teresa Adragão^a, Margarida Bruges^a, André Weigert^a, Domingos Machado^a

^a Department of Nephrology, Hospital Santa Cruz – Centro Hospitalar Lisboa Ocidental, Lisbon, Portugal
^b Department of Gastroenterology, Hospital Egas Moniz – Centro Hospitalar Lisboa Ocidental, Lisbon, Portugal

* Corresponding author.

E-mail address: arrcalca@gmail.com

(R. Calça).

<https://doi.org/10.1016/j.nefro.2019.11.005>

0211-6995/© 2019 Sociedad Española de Nefrología. Published by Elsevier España, S.L.U. This is an open access article under the CC BY-NC-ND license (<http://creativecommons.org/licenses/by-nc-nd/4.0/>).

Immunoglobulin A vasculitis in a patient with neurofibromatosis type 1

Vasculitis por inmunoglobulina A en un paciente con neurofibromatosis tipo 1

ARTICLE INFO

Dear Editor,

Neurofibromatosis type 1 (NF1) is an autosomal dominant disorder that affects multiple organ systems.¹ It can be diagnosed if a patient presents with two or more of the following features: six or more café-au-lait macules of larger than 5 mm in diameter before puberty or larger than 1.5 mm in diameter after puberty, axillary or inguinal skinfold freckling, two or more dermal neurofibromas or one plexiform neurofibroma, two or more iris hamartomas, an optic pathway glioma, a distinctive long bone dysplasia involving the sphenoid wing or thinning of the long bone cortex with or without pseudarthrosis, and a first-degree relative with NF1.² Neurofibromas, one of the main clinical features, usually present as discrete nodules or pedunculated masses, but cannot be presented as vasculitic skin purpura.³ Here, we report a female patient with NF1 who demonstrated vasculitic skin rash.

A 56-year-old Japanese woman with neurofibromatosis type 1 presented with new onset of microscopic hematuria, abdominal pain, and arthralgia. Her past medical history included the left limb amputation due to a traffic accident and malignant peripheral nerve sheath tumours. She had no previous history of renal disease and denied any use of tobacco or alcohol. Upon physical examination, her respiratory rate was 14 breaths per minute, heart rate was 106 beats per minute, blood pressure was 137/85 mmHg, and body temperature was 36.7 °C. Notable examination findings included generalized neurofibromas, palpable purpura on the right leg (Fig. 1), and a slight tenderness at the epigastric area. The musculoskeletal examination showed mild pain in the bilateral elbow joints. Urinalysis showed >100 erythrocytes per high-power field and 0.54 g/gCr of proteinuria. The kidney function was normal (blood urea nitrogen level, 15.6 mg/dL; serum creatinine level, 0.44 mg/dL). Renal biopsy revealed mild mesangial proliferation with granular Immunoglobulin A (IgA) deposition, and skin biopsy showed leukocytoclastic vasculitis with IgA deposition. The diagnosis of IgA vasculitis (IgAV) was made based on the European League Against Rheumatism, the Paediatric Rheumatology International Trials Organizations, and the Paediatric Rheumatology European Society (EULAR/PRNTO/PRES) classification criteria.⁴

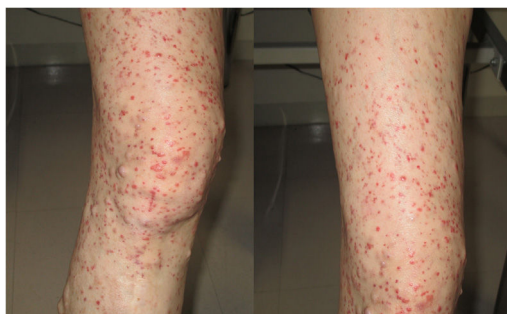

Fig. 1 – Physical examination showed neurofibromas and palpable purpura on the right leg.

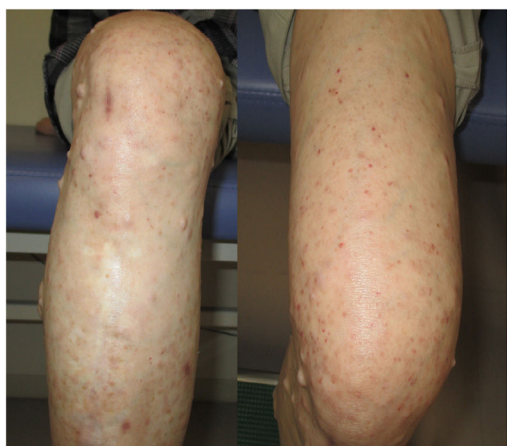


Fig. 2 – Subsidence of palpable purpura on the left leg after initiating enalapril.

IgAV is a small-vessel vasculitis, involving the skin, joints, and kidney. According to the EULAR/PRINTO/PRES classification criteria, the diagnosis of IgAV is confirmed by the presence of purpura and one of the following clinical manifestations: abdominal pain, arthralgia, renal insufficiency, and leukocytoclastic vasculitis with predominant IgA deposits.⁴ Proteinuria, hematuria, or renal insufficiency are present in 70–80% of adult patients with IgAV.⁵ There is no specific treatment for IgAV because it generally resolves spontaneously; however, renin-angiotensin system inhibitors and corticosteroid therapy are recommended to reduce proteinuria and maintain kidney function in moderate and severe cases.⁶

By contrast, neurofibromatosis type 1, an autosomal dominant disorder caused by germline mutations in the NF1 tumour suppressor gene, can manifest progressive multiple organ dysfunctions in the skin, bones, eyes, and neuropsychiatric system.¹ Neurofibromas and café-au-lait macules are the main skin features, whereas, palpable purpura is not.³ Regular assessment of neurofibromas (owing to the increased risk of malignant peripheral nerve sheath tumours), vitamin D supplementation (owing to the increased risk of osteoporosis), blood pressure monitoring (owing to the increased risk of hypertension) and visual assessment (owing to the risk of optic pathway gliomas), are the mainstay of clinical management. Of note, patients with neurofibromatosis type 1 have

the increased risk of developing malignancy such as brain tumours, adrenal cancer, and early-onset breast cancer.¹

Although the association between IgAV and neurofibromatosis type 1 is not clear, this was the first reported case of IgAV in a patient with neurofibromatosis type 1. The esophagogastroduodenoscopy showed no evidence of gastrointestinal bleeding or gastrointestinal stromal tumours. After one month initiating enalapril, the patient's proteinuria and hematuria resolved, and the purpura subsided (Fig. 2). We recommended performing mammography for breast cancer screening because women with neurofibromatosis type 1 have the increased risk of breast cancer.¹

Funding

This research did not receive any specific grant from funding agencies in the public, commercial, or not-for-profit sectors.

REFERENCES

1. Gutmann DH, Ferner RE, Listerick RH, Korf BR, Wolters PL, Johnson KJ. Neurofibromatosis type 1. *Nat Rev Dis Primers*. 2017;23:17004.
2. Neurofibromatosis. Conference statement. National Institutes of Health Consensus Development Conference. *Arch Neuro*. 1988;45:575–8.
3. Ortonne N, Wolkenstein P, Blakeley JO, Korf B, Plotkin SR, Riccardi VM, et al. Cutaneous neurofibromas: current clinical and pathologic issues. *Neurology*. 2018;91:S5–13.
4. Ozen S, Pistorio A, Lusan SM, Bakaloglu A, Herlin T, Brik R, et al. EULAR/PRINTO/PRES criteria for Henoch-Schönlein purpura, childhood polyarteritis nodosa, childhood Wegener granulomatosis and childhood Takayasu arteritis: Ankara 2008. Part II: Final classification criteria. *Ann Rheum Dis*. 2010;69:798–806.
5. Hong S, Ahn SM, Lim DH, Ghang B, Yang WS, Lee SK, et al. Late-onset IgA vasculitis in adult patients exhibits distinct clinical characteristics and outcomes. *Clin Exp Rheumatol*. 2016;34:S77–83.
6. Chapter 11: Henoch-Schönlein purpura nephritis. *Kidney Int Suppl*. 2012;2:218–20.

Yoshinosuke Shimamura^{a,*}, Yayoi Ogawa^b, Toshiya Shinohara^c

^a Department of Nephrology, Teine Keijinkai Medical Center, Sapporo, Hokkaido, Japan

^b Hokkaido Renal Pathology Center, Sapporo, Hokkaido, Japan

^c Department of Pathology, Teine Keijinkai Medical Center, Sapporo, Hokkaido, Japan

*Corresponding author.

E-mail address: yshimamura.tkh@gmail.com (Y. Shimamura). <https://doi.org/10.1016/j.nefro.2019.10.008>

0211-6995/© 2020 Sociedad Española de Nefrología. Published by Elsevier España, S.L.U. This is an open access article under the CC BY-NC-ND license (<http://creativecommons.org/licenses/by-nc-nd/4.0/>).