

glomerular filtration rate (eGFR) should be determined and, in the event that such discrepancy is confirmed, more specific testing should be done (24-h urine creatinine clearance) and the risk/benefit ratio individually assessed of selecting a high or low dose or a different direct oral anticoagulant (DOAC) with no dosing discrepancies depending on the formula used.⁶ In individuals with less than two criteria, the CKD-EPI and CG equations can be used indiscriminately. Hence, using this scale, calculation using the CG equation could be limited to 34.9% of patients.

The sample size was small, especially in patients with stage 3–5 kidney disease, and this might have limited the statistical power. Larger studies will be needed to confirm the external validity of our results.

Funding

Alejandro Isidoro Pérez Cabeza and Francisco Ruiz Mateas declare that they have received consulting fees from Bayer Hispania, S.L.

REFERENCES

1. Steffel J, Verhamme P, Potpara TS, Albaladejo P, Antz M, Desteghe L, et al. The 2018 European Heart Rhythm Association practical guide on the use of non-vitamin antagonist oral anticoagulants in patients with atrial fibrillation. *Eur Heart J*. 2018;39:1330–93.
2. https://kdigo.org/wp-content/uploads/2017/02/KDIGO_2012_CKD_GL.pdf [accessed 05.04.19].
3. Manzano-Fernández S, Andreu-Cayuelas JM, Marín F, Orenes-Piñero E, Gallego P, Valdés M, et al. Comparison of estimated glomerular filtration rate equations for dosing new oral anticoagulants in patients with atrial fibrillation. *Rev Esp Cardiol*. 2015;68:497–504.
4. Pérez Cabeza AI, Chinchurreta Capote PA, González Correa JA, Ruiz Mateas F, Rosas Cervantes G, Rivas Ruiz F, et al.

Discrepancies between the use of MDRD-4 IDMS and CKD-EPI equations, instead of the Cockcroft-Gault equation, in the determination of the dosage of direct oral anticoagulants in patients with non-valvular atrial fibrillation. *Med Clin (Barc)*. 2018;150:85–91.

5. Yao X, Shah ND, Sangaralingham LR, Gersh BJ, Noseworthy PA. Non-vitamin K antagonist oral anticoagulant dosing in patients with atrial fibrillation and renal dysfunction. *J Am Coll Cardiol*. 2017;69:2779–90.
6. Eppenga WL, Kramers C, Derijks HJ, Wensing M, Wetzels JFM, De Smet PAGM drug therapy management in patients with renal impairment: how to use creatinine-based formulas in clinical practice. *Eur J Clin Pharmacol*. 2016;72:1433–9.

Alejandro Isidoro Pérez Cabeza^{a,*}, José Luis Górriz^b, Rafael Bravo Marqués^a, Pedro Antonio Chinchurreta Capote^a, Sergio López Tejero^a, José Antonio González Correa^c, Fidel Ernesto Mesa Prado^a, Almudena Valle Alberca^a, Francisco Ruiz Mateas^a

^a Servicio de Cardiología, Hospital Costa del Sol, Marbella (Málaga), Spain

^b Servicio de Nefrología, Hospital Clínico Universitario, INCLIVA, Universidad de Valencia, Valencia, Spain

^c Departamento de Farmacología, Facultad de Medicina, Universidad de Málaga-IBIMA, Málaga, Spain

* Corresponding author.

E-mail addresses: alejandroipec@hotmail.com, alejandro.perez.cabeza@juntadeandalucia.es (A.I. Pérez Cabeza).

2013-2514/© 2020 Sociedad Española de Nefrología. Published by Elsevier España, S.L.U. This is an open access article under the CC BY-NC-ND license (<http://creativecommons.org/licenses/by-nc-nd/4.0/>).

<https://doi.org/10.1016/j.nefro.2021.04.002>

Syndrome of inappropriate antidiuretic hormone as the initial presentation of COVID-19: A novel case report

Síndrome de Hormona Antidiurética Inapropiada como la Presentación Inicial de COVID-19: Un nuevo informe de un caso

Dear Editor:

The rapid and unprecedented spread of severe acute respiratory syndrome coronavirus disease 2019 (COVID-19) has significantly limited our understanding of this disease. As the

pandemic continues to evolve,¹ cardio-pulmonary symptoms predominate, however new atypical manifestation of COVID are increasingly recognized.

To alert clinicians regarding a novel presentation of COVID-19. We present the first reported case of SARS-COV2 induced syndrome of inappropriate diuretic hormone (SIADH) manifesting as new-onset seizures.

A previously healthy 75-year-old man presents with a witnessed episode of new-onset seizures. Per family accounts,

DOI of original article: <https://doi.org/10.1016/j.nefro.2020.04.016>.

Table 1 – Laboratory investigations.

	Initial	Discharge
Hematological studies		
Complete blood count		
Hb (g/dL)	11.3	13.0
WBC ($\times 10^9 L^{-1}$)	3.2	6.7
Platelets ($\times 10^9 L^{-1}$)	116	306
Inflammatory markers		
Procalcitonin (ng/ml)	0.02	0.12
Interleukin-6 (ref 0–15.5 pg/ml)	270	9.2
C-Reactive protein (ref <5.1 mg/l)	173	126
Ferritin (ref 30–400 ng/ml)	678	1437
D-Dimer (ref <0.5 ug/ml)	2.84	1.75
Lactate dehydrogenase (ref 100–220 U/l)	448	285
Biochemistry (mEq/L)		
Serum sodium	104	130
Serum osmolality (mOsm/kg)	230	
Uric Acid	3	
Potassium	4.8	4.4
Chloride	74	98
Calcium	7.8	8.7
Magnesium	1.9	1.9
Phosphorous	2.2	2.5
Renal (mg/dl)		
BUN	12	19
Creatinine	0.52	0.8
Hepatic		
AST (U/L)	28	33
Total/direct bilirubin	0.6	1.2
Albumin (g/dL)	3.4	2.8
PT/INR (ref 0.9–1.1)	1.1	1.1
Urine studies		
U. osmolality 9 m (Osm/kg)	693	
Spot sodium (mmol/L)	58	
Spot potassium (mmol/L)	17.3	
Spot creatinine (mg/dL)	86	
U uric acid	850	

the episode lasted three minutes with tonic-clonic movements of all extremities, followed by a period of confusion. He had endorsed worsening fatigue and headaches with a declining appetite over the preceding two weeks. There was no history of cough, respiratory symptoms, sick contacts or

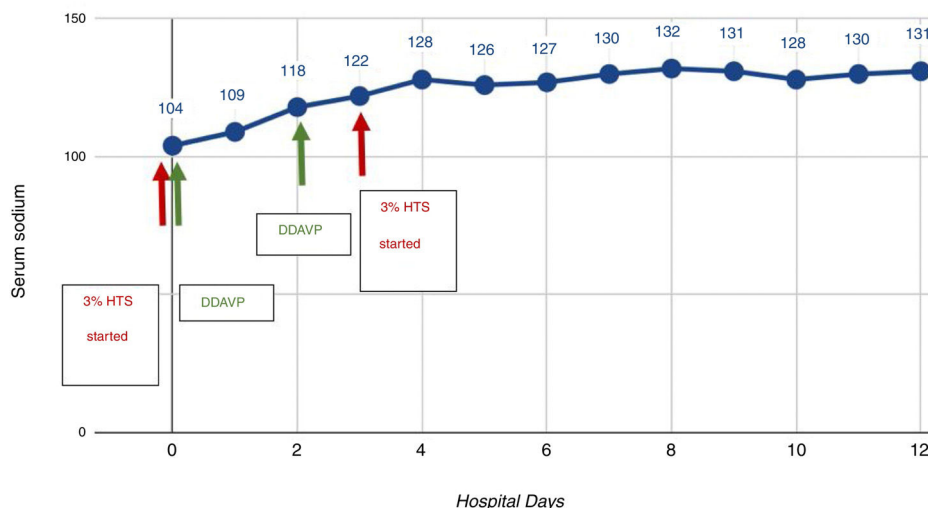
prior similar episodes. Travel history was significant for a trip to California two weeks prior. He denied any medication, health supplement or illicit substance use. Past medical, surgical and family histories were unremarkable. On examination, the patient was obtunded and afebrile (37.3 °C). He appeared visibly dyspneic, with an SpO₂ of 85% on room air and RR of 34/minute, but remained hemodynamically stable. Lung auscultation revealed scattered bilateral crackles while the neurological exam was non-focal. Clinically the patient appeared euvolemic. Computed tomography of the brain was unrevealing with no additional explanation for his prolonged altered mentation. Chest-radiography revealed bilateral air-space opacities.

Labs indicated mild leukocytopenia ($3.2 \times 10^9 L^{-1}$) with lymphopenia ($0.6 \times 10^9 L^{-1}$) and a profound hyponatremia of 104 mEq/L. Renal and liver parameters were normal. Workup of his hyponatremia revealed a serum and urine osmolality of 230 mOsm/kg and 693 mOsm/kg respectively with a urine sodium of 58 mmol/L. TSH and cortisol levels were normal. Inflammatory markers were significantly elevated as summarized in Table 1. Influenza polymerase chain reaction (PCR), respiratory viral PCR panel, legionella urine antigen and blood cultures were all negative; however, the COVID-19 PCR assay was subsequently found to be positive.

Based on the patient's clinical and biochemical data, he was diagnosed with severe symptomatic hyponatremia secondary to syndrome of inappropriate antidiuretic hormone secretion (SIADH) in the setting of COVID-19 pneumonia.

In view of his severe symptoms, 3% hypertonic saline (HTS) infusion was initiated with concomitant fluid restriction. We utilized a pro-active DDAVP strategy (DDAVP 2mcg iv q8h as needed) to minimize overcorrection in the setting of his high risk of osmotic demyelination. He demonstrated a dramatic clinical recovery with symptom resolution and normalization of sodium on day 4 of hospitalization as indicated in Fig. 1. The remainder of his hospital course was unremarkable.

The rapid rise and spread of COVID-19 in the US have posed a significant challenge to the healthcare system. At this time, understanding of its clinical presentation is largely based on data from China and Singapore. A meta-analysis of

**Fig. 1 – Trend of sodium correction.**

nearly 46,000 patients indicates that upper respiratory and flu-like symptoms predominate with less common complaints including headache, dizziness, abdominal pain, anosmia, diarrhea, nausea, and vomiting.² In this paper, we present the first report of COVID-19 related SIADH presenting as new onset seizures in the absence of fever or overt respiratory symptoms.

SIADH in the setting of pneumonia has been extensively studied and reported. Several potential mechanisms have been postulated including extensive cytokine release, hypoxemia, nausea and stress.³ Additionally, inflammation (IL-6 in particular) itself has been reported to directly impair osmoregulation leading to hyponatremia.⁴

Increasingly evidence indicates a propensity for hyperinflammation and cytokine release with COVID-19 infections.⁵ This has manifested as Acute respiratory distress syndrome, myocarditis and overt cytokine storm which are becoming increasingly well recognized associations.

We hypothesize that milder forms of hypercytokinemia and hyper-inflammation could result in a number of less dramatic atypical presentations including SIADH. Elderly populations are particularly susceptible due to impaired free water excretion and late recognition of symptoms. A high index of suspicion and awareness of this association is essential to mitigate SIADH related complications as cases of COVID-19 continue to rise.

REFERENCES

1. Fink S. Worst-case estimates for US coronavirus deaths. *New York Times*. 2020;13. <https://www.nytimes.com/2020/03/13/us/coronavirus-deaths-estimate.html> [accessed 15.03.20].

- Wu Y, Jiang S, Lou T, Xu J, Zhang Y, Chen H, et al. A meta-analysis of clinical characteristics and mortality COVID-19 pneumonia; 2020, <http://dx.doi.org/10.21203/rs.3.rs-18723/v1>.
- Edmonds ZV. Hyponatremia in pneumonia. *J Hosp Med*. 2012;7(S4), <http://dx.doi.org/10.1002/jhm.1933>.
- Swart RM, Swart RM, Hoom EJ, Betjes MG, Zietse R. Hyponatremia and inflammation: the emerging role of interleukin-6 in osmoregulation. *NEP*. 2011;118:45–51.
- Mehta P, McAuley DF, Brown M, Sanchez E, Tattersall RS, Manson JJ. COVID-19: consider cytokine storm syndromes and immunosuppression. *Lancet*. 2020;395(10229):1033–4, [http://dx.doi.org/10.1016/s0140-6736\(20\)30628-0](http://dx.doi.org/10.1016/s0140-6736(20)30628-0).

Kam Sing Ho^{a,*}, Bharat Narasimhan^a, Aravinth Kumar^d, Erin Flynn^a, James Salonia^{a,b}, Karim El-Hachem^{a,c}, Joseph P. Mathew^{a,b}

^a Department of Internal Medicine, Icahn School of Medicine at Mount Sinai, New York, NY, USA

^b Department of Pulmonary and Critical Care, Icahn School of Medicine at Mount Sinai, New York, NY, USA

^c Department of Nephrology, Icahn School of Medicine at Mount Sinai, New York, NY, USA

^d Institute of Nephrology, Madras Medical College, Chennai, India

* Corresponding author.

E-mail address: kam.ho@mountsinai.org (K.S. Ho).

<https://doi.org/10.1016/j.nefro.2020.05.004>

0211-6995/© 2020 Sociedad Española de Nefrología. Published by Elsevier España, S.L.U. This is an open access article under the CC BY-NC-ND license (<http://creativecommons.org/licenses/by-nc-nd/4.0/>).

Intravenous immunoglobulins: A therapeutic alternative to consider in kidney transplant patients with COVID-19[☆]

Inmunoglobulinas por vía intravenosa: una alternativa terapéutica a tener en cuenta en el paciente trasplantado renal con COVID-19

Dear Editor,

Infection with the coronavirus SARS-CoV-2, causing COVID-19, originated in Wuhan, China, in December 2019.¹ This infection quickly propagated around the world, affecting numerous countries, and was declared a pandemic by the World Health Organization on 11 March 2020.

Subgroups at risk of developing severe forms of the disease have been identified, including kidney transplant patients, who have a greater incidence of infection and admission, as well as a greater need for admission in intensive care units.² Immunosuppressant treatment is one of the reasons for this population's vulnerability.

The management of immunosuppressant treatment in a context of SARS-CoV-2 infection is unclear.^{3,4} In addition, the

DOI of original article:

<https://doi.org/10.1016/j.nefro.2020.05.003>.

[☆] Please cite this article as: Sánchez Cadena AD, Negreira Caamaño M, Pérez Serrano R, Porras Leal ML. Inmunoglobulinas por vía intravenosa: una alternativa terapéutica a tener en cuenta en el paciente trasplantado renal con COVID-19. *Nefrología*. 2021;41:220–222.