

Images

Vacuolar denatured cast, the unknown element in the urinary sediment[☆]

Cilindro desnaturalizado vacuolar, un elemento poco conocido del sedimento urinario

Carlos Martínez-Figueroa^{a,*}, Karen Cortés-Sarabia^b, Hilda Guadalupe Catalán-Nájera^a, Micaela Martínez-Alarcón^a, Enrique Alejandro Molina-Avilés^c

^a Servicio de urgencias, Laboratorio clínico, Clínica Hospital ISSSTE, Iguala, Guerrero, Mexico

^b Laboratorio de Inmunobiología y Diagnóstico Molecular, Facultad de Ciencias Químico Biológicas, UAGro, Chilpancingo, Guerrero, Mexico

^c Laboratorio clínico, Hospital General de zona N.º 27, IMSS, Ciudad de México, Mexico

We are presenting the case of a 62-year-old male patient with history of diabetes mellitus, who attended the peritoneal dialysis clinic for follow up and blood work (blood cytology and blood chemistry) and urinalysis were obtained. The results of the blood work were as follows: haemoglobin 11.8 g/dl (12–15 g/dl), glucose 60 mg/dl (70–110 mg/dl), urea 85.5 mg/dl (10–50 mg/dl), creatinine 2.9 mg/dl (0.6–1.3 mg/dl), BUN 39.95 mg/dl (7–18 mg/dl), uric acid 4.2 mg/dl (2.6–7.2 mg/dl), total cholesterol 252 mg/dl (120–200 mg/dl) and triglycerides 220 mg/dl (70–150 mg/dl). The results of the urinalysis were proteinuria (>300 mg/dl) and haematuria (200 red blood cells/ μ l). Microscopy of the sediment confirmed the haematuria (10–15 erythrocytes/field under a high-dry lens) and also found oval fat bodies, fat droplets (lipiduria), yeasts, squamous, urothelial and kidney cells, and a large variety of casts, including waxy, red blood cell, granular, white blood cell, lipid and hyaline cases (Fig. 1), with the presence of a cast with a waxy matrix and large num-

ber of vacuoles that was identified as vacuolar denatured casts (Fig. 2), which is being of particularly rare

A main complications of diabetes mellitus is diabetic nephropathy, which is commonly associated with the development of end-stage chronic renal disease.¹ Vacuolar denatured casts are formed elements not described in the western literature, and their clinical significance and origin are unknown. These casts have been associated with the presence of diabetic nephropathy with reduced kidney function (creatinine >2 mg/dl), although they are not specific to this disease as they have also been observed in nephritis and nephrotic syndromes due to other causes.^{2,3} In addition to a waxy matrix, vacuolar denatured casts can be granular with vacuoles, with the latter commonly being accompanied by oval fat bodies and lipid casts.² Regarding the origin of these, the most widely-accepted hypothesis is that are derived from vacuolated renal cells or fatty casts that lose their lipid components, but to date this has not been proven.^{4,5}

DOI of original article:

<https://doi.org/10.1016/j.nefro.2020.06.002>.

[☆] Please cite this article as: Martínez-Figueroa C, Cortés-Sarabia K, Catalán-Nájera HG, Martínez-Alarcón M, Molina-Avilés EA. Cilindro desnaturalizado vacuolar, un elemento poco conocido del sedimento urinario. *Nefrología*. 2021;41:365–366.

* Corresponding author.

E-mail address: carlosmtzfg@gmail.com (C. Martínez-Figueroa).

2013-2514/© 2020 Sociedad Española de Nefrología. Published by Elsevier España, S.L.U. This is an open access article under the CC BY-NC-ND license (<http://creativecommons.org/licenses/by-nc-nd/4.0/>).

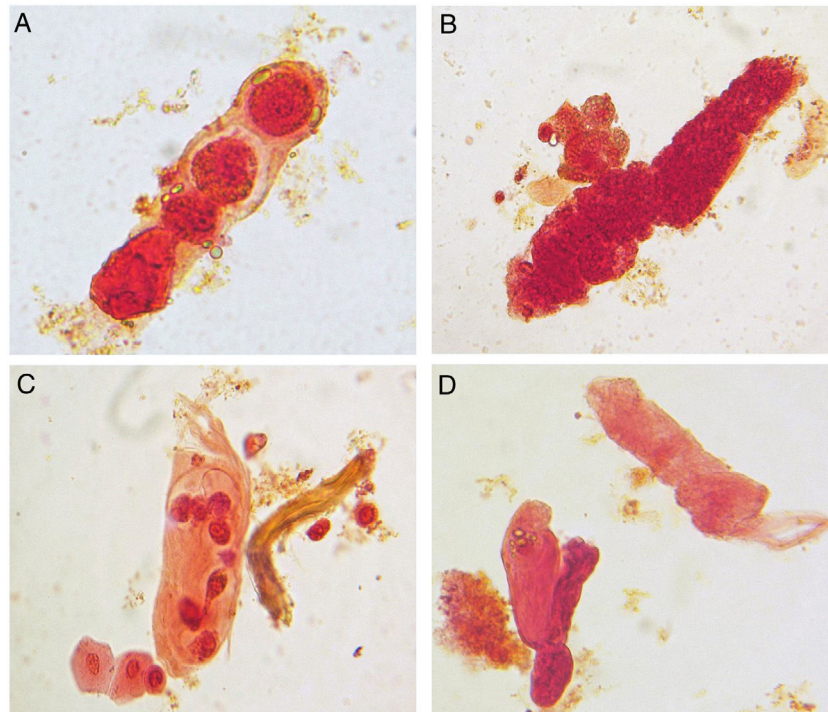


Fig. 1 – Formed elements observed in urine sediment of a patient. (A) Cast with oval fat bodies. (B) Granular cast and oval fat bodies. (C) Cast of tubule cells and two urothelial cells (bottom). (D) Hyaline cast (top) and cast with lipid inclusions (bottom left). Sternheimer-Malbin stain, 40 \times , bright-field microscopy.

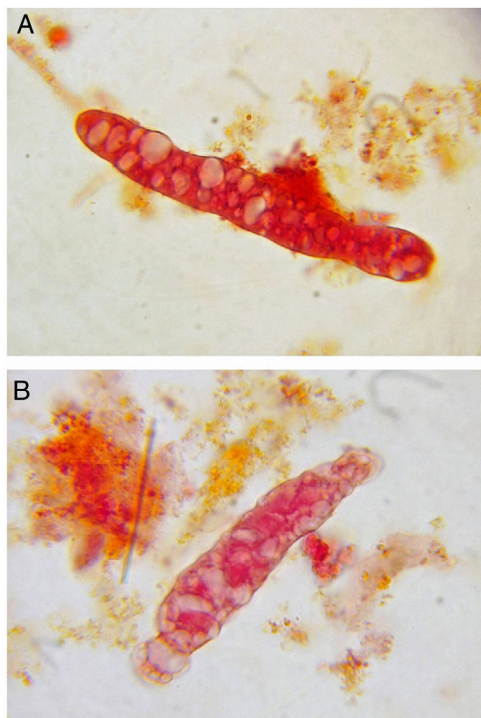


Fig. 2 – Vacuolar denatured casts. (A) and (B) Waxy matrix casts with large numbers of vacuoles. Sternheimer-Malbin stain, 40 \times , bright-field microscopy.

Funding

This study received no support of any kind from public, private or non-profit organisations.

Conflicts of interest

None.

REFERENCES

1. Lim AKH. Diabetic nephropathy — complications and treatment. *Int J Nephrol Renovasc Dis.* 2014;7:361–81.
2. JCCLS. Aims of the guidelines on urinary sediment examination procedures proposed by the Japanese Committee for Clinical Laboratory Standards (JCCLS). *Jpn J Med Technol.* 2017;66(J-STAGE-1):9–17.
3. Tanaka K, Nakagawa S, Matsumoto M, Kanayama Y, Nagata K, Serikawa F. What is a vacuolar denatured cast? *Insp Technol.* 2004;32:352–4.
4. Tanaka K, Serikawa F, Matsumoto M, Nakagawa S, Nojima T. Vacuolar denatured cast. *Insp Technol.* 2008;36:1257–61.
5. Graber M, Lane B, Lamia R, Pastoriza-Munoz E. Bubble cells: renal tubular cells in the urinary sediment with characteristics of viability. *J Am Soc Nephrol.* 1991;1:999–1004.