

The result showed that no patient tested positive in the SARS-CoV-2 RNA PCR and all were negative for total antibodies.

The importance of SARS-CoV-2 screening has been discussed recently by some authors.³ Since haemodialysis patients are especially vulnerable due to their clinical and logistical characteristics (for example, their need to go to the hospital an average of three to four times a week), we consider that the screening of both the population and the personnel who care for them is fundamental.

The results obtained in our series may be due to four causes: 1) the low prevalence of the disease during the peak of the pandemic in the northern area of the island of Gran Canaria¹; 2) since the time for preparation was longer than in other provinces, protocols were established for both physical distancing and strict clinical control (for example, use of masks by all patients, limitation of visits, temperature measurement before entry into the units, etc.)⁴; 3) the measurement of antibodies was conducted late,⁵ and 4) the political measures were adopted early, such as the closure of schools, airports and harbors, among others.⁶

REFERENCES

1. Cartográfica de Canarias, S.A. COVID-19 Canarias: Gobierno de Canarias (Servicio Canario de Salud) [Accessed 8 Aug 2020]. Available from: <https://grafcan1.maps.arcgis.com>.
2. Wu Z, McGoogan JM. Characteristics of important lessons from the coronavirus disease 2019 (COVID-19) outbreak in China: summary of a report of 72 314 cases from the Chinese Center for Disease Control Prevention. *JAMA*. 2020;10, <http://dx.doi.org/10.1001/jama.2020.2648>, 1001/jama.2020.2648. [Electronic publication 24 Feb 2020].

3. Dudreuilh C, Moutzouris DA. Is SARS-CoV-2 serology relevant for hemodialysis patients with COVID-19? *Am J Kidney Dis*. 2020. S0272-6386:30784-8, <https://doi.org/10.1053/j.ajkd.2020.06.006> [Electronic publication 27 Jun 2020].
4. Albalade M, Arribas P, Torres E, Cintra M, Alcázar A, Puerta M, et al. [High prevalence of asymptomatic COVID-19 in haemodialysis: learning day by day in the first month of the COVID-19 pandemic] Alta prevalencia de COVID-19 asintomático en hemodiálisis. *Apreniendo día a día el primer mes de pandemia de COVID-19*. *Nefrologia*. 2020;40:279-86, <http://dx.doi.org/10.1016/j.nefro.2020.04.005>.
5. Rapid decay of Anti-SARS-CoV-2 antibodies in persons with mild Covid-19 [Electronic publication 23 Jul 2020]. *N Engl J Med*. 2020, <http://dx.doi.org/10.1056/NEJMx200017>.
6. Boletín Oficial de Canarias Orden de 12 de marzo 2020 [16 Mar 2020; Accessed 8 Aug 2020]. Available from: <http://www.gobiernodecanarias.org/boc/2020/052/006.html>.

Francisco Valga^{a,*}, Tania Monzón^b, Nicanor Vega-Díaz^a, Gloria Antón-Pérez^b, José Carlos Rodríguez-Pérez^a

^a Servicio de Nefrología, Hospital Universitario de Gran Canaria Doctor Negrín, Las Palmas de Gran Canaria, Spain

^b Servicio de Nefrología, Centro de Hemodiálisis Avericum Negrín, Las Palmas de Gran Canaria, Spain

* Corresponding author.

E-mail address: fvalga@hotmail.com (F. Valga).

2013-2514/© 2020 Sociedad Española de Nefrología. Published by Elsevier España, S.L.U. This is an open access article under the CC BY-NC-ND license (<http://creativecommons.org/licenses/by-nc-nd/4.0/>). <https://doi.org/10.1016/j.nefro.2020.08.006>

A patient with COVID-19 and anti-glomerular basement membrane disease

Un paciente con Covid-19 y enfermedad de la membrana basal anti glomerular

Dear Editor,

Elderly patients and patients with co-morbidities such as hypertension, diabetes and heart disease are under risk of COVID-19.¹ Anti-glomerular basement membrane (anti-GBM) disease is an autoimmune disease presenting with features of rapidly progressive glomerulonephritis and alveolar

hemorrhage.² It requires an aggressive immunosuppressive treatment.

We report the case of a 80-year-old female patient with anti-GBM disease who had a fatal course after acquiring a severe COVID-19 infection under immunosuppressive treatment. She had well-controlled hypertension and presented with fever, dyspnea, hemoptysis and hematuria for the last five days. Her laboratory values were as follows: Creatinine (Cre): 6.0 mg/dL, blood urea nitrogen (BUN): 86.6 mg/dL, sodium (Na): 139 mEq/L, potassium (K): 3.6 mEq/L, uric acid (Ua): 12.6 mg/dL, albumin (alb): 3.1 g/dL, erythrocyte sedimentation rate (ESR): 64 mm/h, CRP: 14.8 mg/dL, BNP: 403 pg/mL, procalcitonin: 1.14 ng/mL. Urinalysis revealed 1226

DOI of original article: <https://doi.org/10.1016/j.nefro.2020.08.004>.

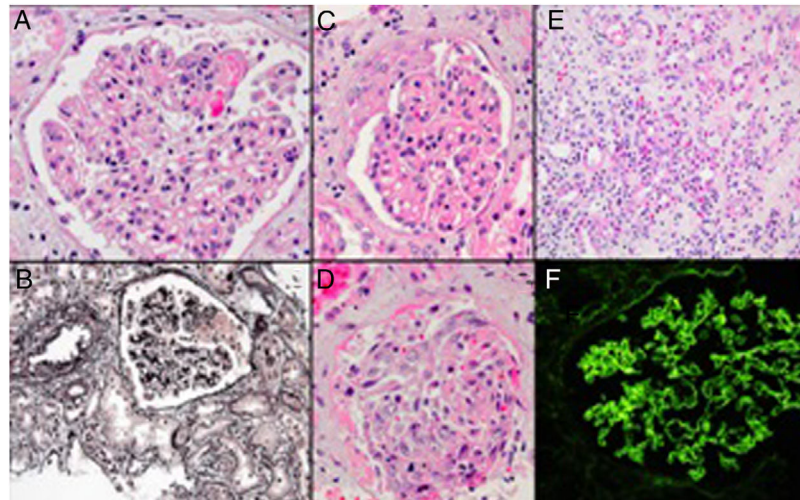


Fig. 1 – Glomerulus with focal fibrinoid necrosis (A, hematoxylin-eosin), another glomerulus with fibrinoid necrosis, which can be seen as the pink argyrophobic area in the silver stain (B, Jones methenamine silver). Glomerulus with partial cellular crescent formation (C, hematoxylin–eosin stain), another glomerulus with extensive extracapillary proliferation filling the Bowman space and part of a tubule filled with a red blood cell cast (D, hematoxylin–eosin stain). Accompanying interstitial inflammation with abundance of eosinophils (E, hematoxylin–eosin stain). Immunofluorescence microscopy showing linear IgG along the glomerular basement membrane (F).

erythrocytes/HPF and 86 leucocytes/HPF. 24-h proteinuria was 5.8 g/day. Echocardiography revealed normal left ventricular functions with an ejection fraction of 66% and pulmonary hypertension (pulmonary artery pressure: 60 mmHg).

A non-contrast chest CT revealed alveolar hemorrhage and a suspicion of pneumonia. Nasopharyngeal swap for respiratory pathogens and PCR for COVID-19 was sent but there was no positivity. ANA, ANCA were negative, C3 and C4 levels were normal. However, testing for anti-GBM antibody was reported as positive.

Renal biopsy revealed a focal necrotizing extra-capillary proliferative glomerulonephritis and acute tubulointerstitial nephritis. Immunofluorescence microscopy showed presence of linear IgG along the glomerular basement membrane. A diagnosis of anti-GBM disease with a comment about supervening possible drug reaction was made (Fig. 1).

500 mg intravenous methylprednisolone (mps) for three days and 500 mg once a week cyclophosphamide treatment was started. She was discharged on oral mps treatment since there was no fever and progression in the infiltrations in the control CT imaging.

Three days after discharge, patient presented to the emergency service with tachypnea and hemoptysis. She was admitted to intensive care unit. A control chest CT showed similar findings with the previous ones (Fig. 2).

Considering her hospitalization history during COVID-19 outbreak and CT findings, a control PCR for COVID-19 was sent which was reported as positives. She had leukocytosis with lymphopenia and high level of acute phase reactants.

Combination treatment of hydroxychloroquine and azithromycin was started. In the fifth day of treatment she had to be intubated and vasopressor treatment was started. Favipravir and intravenous immunoglobulin were added because of resistant COVID-19 infection. Patient under-

went continuous renal replacement therapy due to severe oliguric acute kidney injury and died on the 14th day of hospitalization.

This case report demonstrates a patient with anti-GBM disease who died in a short period of time after acquiring COVID-19 infection under immunosuppressive treatment. Although immunosuppressive treatment may theoretically complicate the course of an infectious disease,³ there is no firm evidence of increased complication for COVID-19 infections in patients under immunosuppressive treatment.^{4–6} However, it is impossible to completely exclude any detrimental effect of immunosuppression for specific disorders such as anti-GBM disease on COVID-19 infection. The unfavorable clinical course of this patient may be related either to the immunosuppression or the primary disease affecting the lungs, as it is well known that patients with lung diseases are at increased risk.

The PCR test for COVID-19 is far from perfect as approximately 30% of the patients have an initial false-negative result.⁷ This creates a dilemma for the clinicians when encountering a patient who has or may have an alternative diagnosis requiring immunosuppression but also has some features of COVID-19 infection. In this particular patient, since the initial PCR for COVID-19 was negative, a prompt response to antibacterial treatment was observed and there was no progression in the control CT imaging we excluded COVID-19 during the initial hospitalization. However, when the patient presented with a more severe condition in the second admission, considering her previous hospitalization history in the same ward with COVID-19 positive patients and her severe lymphopenia a repeat PCR test for COVID-19 was ordered which was found positive. The patient was therefore considered as new onset COVID-19 infection under immunosuppressive treatment.

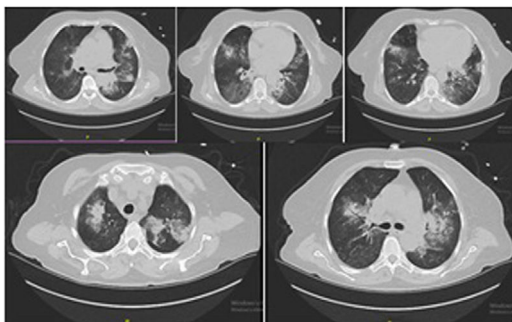


Fig. 2 – Chest computerized tomography revealed anti-GBM disease but could not exclude accompanying infection.

Another point that should be considered however is the potential direct pathogenetic effect of the COVID-19 infection on the kidneys. Anti-GBM disease is known to be associated with infectious triggers and to present as mini-epidemics concurrent with influenza outbreaks.⁸⁻⁹ Considering reports of false negativity of patients at initial PCR testing there is thus the possibility that COVID-19 can be the causative factor of the anti-GBM disease. A Chinese study that examined post mortem renal biopsy findings in 26 COVID-19 infection cases however did not mention any cases with necrotizing extracapillary proliferative glomerulonephritis that could suggest possibility of anti-GBM renal disease.¹⁰ Thus to date there is no known case of anti-GBM glomerulonephritis in a covid19 patient.

Ethical approval

The article does not contain any studies with human participants or animals performed by any of the authors.

Informed consent

Since the patient that is described in the case report was died, her daughter has given consent for publication

Funding

This research did not receive any specific grant from funding agencies in the public, commercial, or not-for-profit sectors.

Conflict of interest

The authors declare that they have no conflict of interest.

REFERENCES

1. Zhou F, Yu T, Du R, Fan G, Liu Y, Liu Z, et al. Clinical course and risk factors for mortality of adult inpatients with

COVID-19 in Wuhan, China: a retrospective cohort study. *Lancet*. 2020;395:1054-62, [http://dx.doi.org/10.1016/S0140-6736\(20\)30566-3](http://dx.doi.org/10.1016/S0140-6736(20)30566-3).

2. Marques C, Plaisier E, Cacoub P, Cadranet J, Saadoun D. Review on anti-glomerular basement membrane disease or Goodpasture's syndrome. *Rev Med Intern*. 2019;41:14-20, <http://dx.doi.org/10.1016/j.revmed.2019.10.338>.
3. Memoli MJ, Athota R, Reed S, Czajkowski L, Bristol T, Proudfoot K, et al. The natural history of influenza infection in the severely immunocompromised vs nonimmunocompromised hosts. *Clin Infect Dis*. 2014;58:214-24, <http://dx.doi.org/10.1093/cid/cit725>.
4. D'Antiga L. Coronaviruses and immunosuppressed patients. The facts during the third epidemic. *Liver Transpl*. 2020, <http://dx.doi.org/10.1002/lt.25756>.
5. Monti S, Balduzzi S, Delvino P, Bellis E, Quadrelli VS, Montecucco C. Clinical course of Covid-19 in a series of patients with chronic arthritis treated with immunosuppressive targeted therapies. *Ann Rheum Dis*. 2020;79:667-8, <http://dx.doi.org/10.1136/annrheumdis-2020-217424>.
6. Willicombe M, Thomas D, McAdoo S. COVID-19 and calcineurin inhibitors: should they get left out in the storm? *J Am Soc Nephrol*. 2020, <http://dx.doi.org/10.1681/ASN.2020030348>.
7. Arevalo-Rodriguez I, Buitrago-Garcia D, Simancas-Racines D, Zambrano-Achig P, del Campo R, Ciapponi A, et al. False-negative results of initial RT-PCR assays for COVID-19: a systematic review. *medRxiv*. 2020, <http://dx.doi.org/10.1101/2020.04.16.20066787>.
8. Lingaraj U, Mallappa SS, Neminah RE, Mohan SM, Venkatesh L, Gurusiddaiah SC, et al. A "mini-epidemic" of anti-glomerular basement membrane disease: clinical and epidemiological study. *Saudi J Kidney Dis Transpl*. 2017;28:1057-63, <http://dx.doi.org/10.4103/1319-2442.215128>.
9. Wilson CB, Smith RC. Goodpasture's syndrome associated with influenza A2 virus infection. *Ann Intern Med*. 1972;76:91-4, <http://dx.doi.org/10.7326/0003-4819-76-1-91>.
10. Su H, Yang M, Wan C, Yi LX, Tang F, Zhu HY, et al. Renal histopathological analysis of 26 postmortem findings of patients with COVID-19 in China. *Kidney Int*. 2020, <http://dx.doi.org/10.1016/j.kint.2020.04.003>. S0085-2538(20)30369-0.

Neriman Sila Koc^{a,*}, Tolga Yildirim^a, Arzu Saglam^b, Mustafa Arici^a, Yunus Erdem^a

^a Hacettepe University Faculty of Medicine, Department of Nephrology, 06230, Altındag, Ankara, Turkey

^b Hacettepe University Faculty of Medicine, Department of Pathology, 06230, Altındag, Ankara, Turkey

*Corresponding author.

E-mail address: silacank@hotmail.com (N.S. Koc).

<https://doi.org/10.1016/j.nefro.2020.08.003>

0211-6995/© 2020 Sociedad Española de Nefrología. Published by Elsevier España, S.L.U. This is an open access article under the CC BY-NC-ND license (<http://creativecommons.org/licenses/by-nc-nd/4.0/>).