

- guidelines for hemophagocytic lymphohistiocytosis. *Pediatr Blood Cancer*. 2007;48:124–31.
8. Asci G, Toz H, Ozkahya M, Cagirgan S, Duman S, Sezis M, et al. High-dose immunoglobulin therapy in renal transplant recipients with hemophagocytic histiocytic syndrome. *J Nephrol*. 2006;19:322–6.
 9. Fardet L, Galicier L, Lambotte O, Marzac C, Aumont C, Chahwan D, et al. Development and validation of the HScore, a score for the diagnosis of reactive hemophagocytic syndrome. *Arthritis Rheumatol*. 2014;66:2613–20.
 10. Ravelli A, Minoia F, Davi S, Horne A, Bovis F, Pistorio A, et al. 2016 Classification Criteria for Macrophage Activation Syndrome Complicating Systemic Juvenile Idiopathic Arthritis: A European League Against Rheumatism/American College of Rheumatology/Paediatric Rheumatology International Trials Organisation Collaborative Initiative. *Arthritis Rheumatol*. 2016;68:566–76.

Joana Tavares*, Filipa Silva, Ana Castro, Josefina Santos, Guilherme Rocha, Manuela Almeida, La Saete Martins, Leonídio Dias, António Castro Henriques, António Cabrita

Serviço de Nefrologia do Centro Hospitalar Universitário do Porto, Porto, Portugal

*Corresponding author.

E-mail address: joanatavares91@gmail.com (J. Tavares).

<https://doi.org/10.1016/j.nefro.2020.07.008>

0211-6995/© 2020 Sociedad Española de Nefrología. Published by Elsevier España, S.L.U. This is an open access article under the CC BY-NC-ND license (<http://creativecommons.org/licenses/by-nc-nd/4.0/>).

Acute vision loss on hemodialysis: Mönckeberg arteriosclerosis

Pérdida de visión aguda en hemodiálisis: arterioesclerosis de Mönckeberg

Dear Editor,

Regarding the article published in the journal NEFROLOGÍA ["Acute vision loss in patients with kidney failure",¹ and taking into account the scarcity of cases published in the bibliography, we propose the presentation of the following case of amaurosis in a patient on regular haemodialysis.

We present the case of a 73-year-old woman with a medical history of allergy to iodinated contrast, chronic myeloid leukaemia, insulin-dependent type II diabetes mellitus and chronic kidney disease without histological assessment, on haemodialysis since 2018, with poor tolerance to haemodialysis sessions (hypotension), secondary hyperparathyroidism and glaucoma.

During a haemodialysis session and coinciding with an episode of severe hypotension, the patient had onset of holocranial headache accompanied by acute loss of vision of the left eye. Cranial CT without IV contrast was performed with no findings of interest. She was assessed by Ophthalmology and examination of the eye fundi revealed "bilateral papilloedema with retinal haemorrhagic papillitis as a consequence of left retinal infarction" and she was discharged with a follow-up by the ophthalmology unit.

After three weeks, she presented with the same clinical picture in the right eye, reporting an altitudinal loss with progression to total amaurosis. Assessed by Neurology, a Doppler

ultrasound of the supra-aortic trunks was performed without findings of interest and a temporal artery biopsy was performed, three boluses of 500 mg of methylprednisolone were started due to the suspicion that the patient might be suffering from temporal arteritis.

Laboratory testing

- Acute phase reactants: CRP and ESR in normal range
- Total protein corrected serum calcium (mean): 10.5 mg/dl
- Serum phosphorus (mean): 5–6 (mg/dl)
- i-PTH serum: 850 pg/mL

Temporal artery biopsy

No signs of inflammation. There were calcium deposits in the middle layer of the temporal artery (Figs. 1 and 2).

Given these findings, she was diagnosed with Mönckeberg's arteriopathy, and finally the patient did not regain her vision.

Mönckeberg's arteriosclerosis, or Mönckeberg's medial sclerosis, was described for the first time in 1903 by Johann Georg Mönckeberg, as a calcification of the tunica media of the medium and small muscular arteries of the lower extremities and, less frequently, in the visceral or coronary arteries.^{2,3} It is the calcification that has been commonly associated with kidney disease.

The aetiology of this condition is unknown.⁴

It is mainly related to age, diabetes, time on dialysis, and mineral metabolism. It causes stiffness of the arterial wall and, with it, an increase in systolic blood pressure as well as an increase in pulse pressure and pulse wave velocity. It

DOI of original article:

<https://doi.org/10.1016/j.nefro.2020.07.007>.

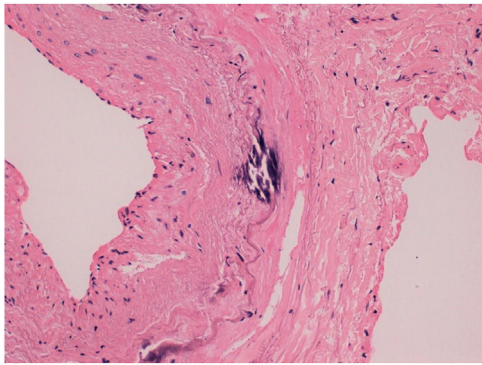


Fig. 1 – Transverse section of the temporal artery revealing marked intimal thickening, with isolated calcifications in the tunica media and on the periphery of the internal elastic lamina.

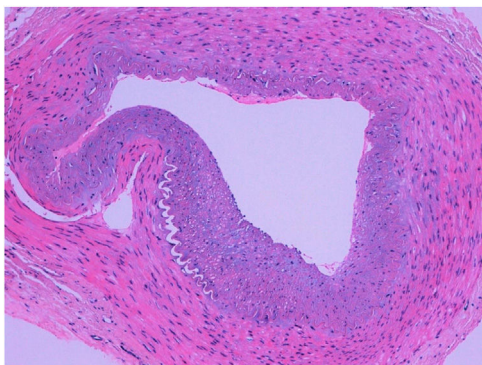


Fig. 2 – Transverse section of the temporal artery showing marked intimal thickening, without other alterations. No inflammation or infiltration by giant cells can be observed.

contributes to the development of left ventricular hypertrophy, fibrosis, ventricular dysfunction, decreased coronary flow during diastole, and heart failure.

Clinically, the manifestations are extensive, all derived from the vascular occlusion that is generated.^{5,6}

Differential diagnoses are mainly given by vasculitis affecting these vessels, including polyarteritis nodosa and giant cell arteritis. In the literature review, only a total of 10 publications between 1999–2019 have been found on Mönckeberg's syndrome, two of them with ocular involvement.

Symptoms can be so similar that, given the inability to determine alterations in calcium-phosphorus metabolism, tissue biopsy must be drawn upon as a means to achieve a definitive diagnosis.⁷

Mönckeberg's arteriopathy has been increasingly recognised in patients with end-stage renal disease in relation to calcium-phosphorus metabolism disorder.

Al-Absi et al.⁸ described a case similar to ours with a 50-year-old man on haemodialysis with symptoms of temporal artery arteritis (temporal headache, blurred vision, jaw claudication) who was found to have Mönckeberg's arteritis on temporal artery biopsy.

Korzets et al.⁹ describe two cases of anterior ischaemic optic neuropathy in haemodialysis patients with extensive medial calcification. Both patients had hypotension and acute unilateral vision loss.

At present, there are no specific treatment for Mönckeberg's sclerosis, and actions are only chosen aiming to optimise calcium metabolism, including chelators such as sodium thiosulfate. In our case, despite intensifying medical treatment, the ocular involvement was irreversible.¹⁰

In conclusion, the development of Mönckeberg's sclerosis is closely linked to senescence, but risk factors such as chronic kidney disease and diabetes mellitus can directly favour its development and progression. In addition, the diagnosis of this condition continues to be an incidental finding in histopathological samples, and there are currently no laboratory diagnostic aids or specific images of the disease. Clinical suspicion will be the cornerstone of diagnosis that may allow for early medical management, thus avoiding an accelerated progression of the disease, and to avoid the prescription of futile treatments.

REFERENCES

- Martín V, Sención Martínez GL, Cañones Zafra R, del Rocío Samillán Sosa K, Velo Plaza M, Teus Guezala MA, et al. Pérdida aguda de visión en pacientes con insuficiencia renal. *NefroPlus*. 2017;9:77–183.
- Silbert S, Lippmann H, Gordon E. Monckeberg's arteriosclerosis. *JAMA*. 1953;151:1176–9.
- McCullough PA, Agrawal V, Danielewicz E, Abela GS. Accelerated atherosclerotic calcification and Monckeberg's sclerosis: a continuum of advanced vascular pathology in chronic kidney disease. *Clin J Am Soc Nephrol*. 2008;3:1585–98.
- Díaz CJ, Herrera Uribe S, González MR, Posada GC, Mejía Zuluaga M. Manifestaciones clínicas de la esclerosis de Monckeberg. Reporte de caso y revisión de la Literatura. *Rev Colomb Reumatol*. 2017;24:118–22.
- Couri CE, da Silva GA, Martínez JA, de Assis Pereira F, Albuquerque de Paula FJ. Mönckeberg's sclerosis—is the artery the only target of calcification? *BMC Cardiovasc Disord*. 2005;5:34.
- Castling B, Bhatia S, Ahsan F. Mönckeberg's arteriosclerosis: vascular calcification complicating microvascular surgery. *Int J Oral Maxillofac Surg*. 2015;44:34–6.
- Pesona L, Latha K, Nikhil S, Amlan G. Monckeberg's arteriosclerosis in uterine vessels: an unusual presentation. *J Obstet Gynaecol India*. 2014;64:436–7.
- Al-Absi AI, Wall BM, Cooke CR. Medial arterial calcification mimicking temporal arteritis. *Am J Kidney Dis*. 2004;44:E73–8.
- Korzets A, Marashek I, Schwartz A, Rosenblatt I, Herman M, Ori Y. Ischemic optic neuropathy in dialyzed patients: a previously unrecognized manifestation of calcific uremic arteriolopathy. *Am J Kidney Dis*. 2004;44:E93–9.
- Castillo BV Jr, Torczynski E, Edward DR. Monckeberg's sclerosis in temporal artery biopsy specimens. *Br J Ophthalmol*. 1999;83:1091–2.

Álvaro Pérez Fernández*, Inmaculada Poveda García, María Teresa Cantón Yebra

UGC (Unidad de Gestión Clínica), Nefrología, Complejo Hospitalario Torrecárdenas, Almería, Spain

* Corresponding author.

E-mail addresses: alvaroperfdez@gmail.com,
alvaro.perez.fernandez.sspa@juntadeandalucia.es
(Á. Pérez Fernández).

2013-2514/© 2020 Sociedad Española de Nefrología. Published by Elsevier España, S.L.U. This is an open access article under the CC BY-NC-ND license (<http://creativecommons.org/licenses/by-nc-nd/4.0/>).
<https://doi.org/10.1016/j.nefro.2021.09.002>