

significantly reduces overall costs, infection, and dysfunction rates of tunneled hemodialysis catheters. *Kidney Int.* 2018;75:3-60.

9. Al-Ali F, Hamdy AF, Hamad A, Elsayed M, Iqbal ZZ, Elsayed A, et al. Safety and efficacy of taurolidine/urokinase versus taurolidine/heparin as a tunneled catheter lock solution in hemodialysis patients: a prospective, randomized, controlled study. *Nephrol Dial Transplant.* 2018;33:619-26.
10. El-Hennawy AS, Frolova E, Romney WA. Sodium bicarbonate catheter lock solution reduces hemodialysis catheter loss due to catheter-related thrombosis and blood stream infection: an open-label clinical trial. *Nephrol Dial Transplant.* 2019;34:1739-45.

Néstor Fontseré<sup>a,\*</sup>, Alex Soriano<sup>b</sup>, Gaspar Mestres<sup>c</sup>, Patricia Bermudez<sup>d</sup>, Federico Zarco<sup>d</sup>, Valentín Lozano<sup>a</sup>, Lida Rodas<sup>a</sup>, Jose Broseta<sup>a</sup>, Marta Arias<sup>a</sup>, Francisco Maduell<sup>a</sup>

<sup>a</sup> Unidad Funcional de Acceso Vascular, Servicio de Nefrología, Hospital Clínico de Barcelona, Barcelona, Spain

<sup>b</sup> Unidad Funcional de Acceso Vascular, Servicio de Enfermedades Infecciosas, Hospital Clínico de Barcelona, Barcelona, Spain

<sup>c</sup> Unidad Funcional de Acceso Vascular, Servicio de Cirugía Vascular, Hospital Clínico de Barcelona, Barcelona, Spain

<sup>d</sup> Unidad Funcional de Acceso Vascular, Servicio de Radiología Vascular Intervencionista, Hospital Clínico de Barcelona, Barcelona, Spain

\*Corresponding author.

E-mail address: fontser@clinic.cat (N. Fontseré).

<https://doi.org/10.1016/j.nefro.2021.02.013>

2013-2514/© 2021 Sociedad Española de Nefrología. Published by Elsevier España, S.L.U. This is an open access article under the CC BY-NC-ND license (<http://creativecommons.org/licenses/by-nc-nd/4.0/>).

## COVID-19 reinfection in a kidney transplant recipient, time for rethinking?

### Reinfección por COVID-19 en un paciente portador de trasplante renal, ¿tiempo para reflexionar?

Dear Editor:

COVID-19 reinfections in immunocompromised patients are a challenge for scientific community. Here we present the first case of a kidney transplant recipient with a lethal COVID-19 reinfection.

He is a 60-year-old male, with chronic kidney disease (CKD) due to focal and segmental glomerulosclerosis that received his first kidney transplant 2004. In treatment with prednisone and rapamycin since 2007 when we was diagnosed of a hepatocellular carcinoma.

In August 2020, after a close contact to a COVID-19 family member, he developed mild symptoms (cough and low-grade fever) and SARS-CoV-2 infection was confirmed by a positive nasopharyngeal real-time reverse transcription-polymerase chain reaction (rRT-PCR) (Fig. 1). The clinical course was favorable, and he did not need further clinical assistance in that moment. A confirmatory rRT-PCR was performed showing a negative result.

In December 2020 and January 2021, he was admitted in the hospital due to two episodes of urinary tract infection caused by *Staphylococcus aureus* and *Serratia marcescens*. In both hospitalizations, rRT-PCR were repeated five times (12th, 30th

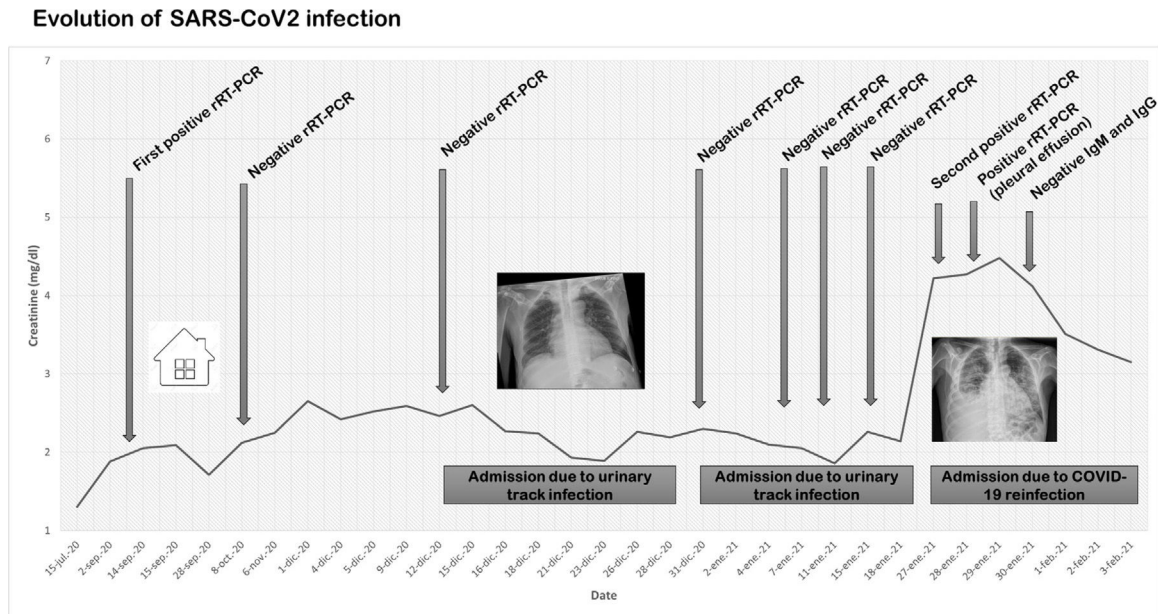
December and 4th, 9th, 17th January 2021) resulting negative in all of them. A chest X-ray performed on 12th December 2020 showed very low intensity bilateral infiltrates. In addition, on 8th January 2021, a chest-abdomen computed tomography scan demonstrated bilateral infiltrates in both hemithorax, probably as a residual lesion of the SARS-CoV-2 previous infection (Fig. 2). After diuretic and antibiotic treatment, chest X-ray improved significantly, and the patient was discharge asymptomatic 20th January 2021.

However, 28th January 2021, the patient was again admitted due to respiratory fever and acute injury of the allograft function. A chest X-ray showed bilateral infiltrates with unilateral pleural effusion. A new rRT-PCR confirmed SARS-CoV-2 infection by the same viral genotype, so immunosuppression was stopped, and dexamethasone was started. A thoracentesis of the pleural effusion demonstrated SARS-CoV-2 in the obtained sample. Antibodies (IgM and IgG) for SARS-CoV2 resulted negative. Although he was theoretically immunosuppressed, lymphocyte populations were normal. Despite established treatment including high flux oxygen, the patient deceased on 5th February 2021.

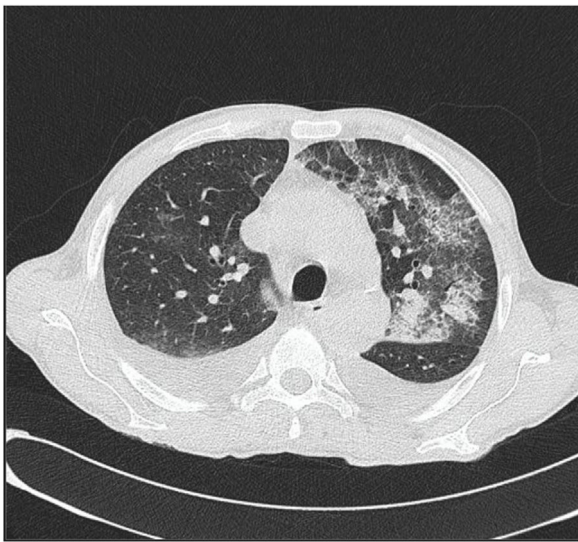
Several doubts have emerged around reinfections in general population. Technical errors in specimen collection or false negative results in rRT-PCR have been demonstrated in many patients driving to mistakes in COVID-19 reinfections. In

DOI of original article:

<https://doi.org/10.1016/j.nefro.2021.02.004>.



**Fig. 1 – Evolution of the patient highlighting the SARS-CoV-2 tests performed since the first infection. Abbreviation: real-time reverse transcription-polymerase chain reaction (rRT-PCR).**



**Fig. 2 – Chest and abdomen computed tomography showing bilateral infiltrates in lungs.**

addition, virus or non-active fragments of them can persist in sputum for weeks showing false positive results. However, the most part of the published reinfections have shown an asymptomatic course in the second positive rRT-PCR episode.<sup>1</sup> This situation interestingly differs from our patient who presented a pauci-symptomatic course of COVID-19 infection with a lethal reinfection 5 months later.

Our patient presented some confirmatory features of a COVID-19 reinfection. First, he had positive rRT-PCR concurring with a family member contact and some mild symptoms. Despite this classical clinical picture, and even using a

highly specific rRT-PCR, in some circumstances false positives can occur. Second, we confirmed negative rRT-PCR in several times, but radiological images showed residual bilateral lesions suggestive of COVID-19 past infection. Third, he developed new symptoms and chest X-ray worsened significantly simultaneously. In addition, in the reinfection episode, pleural effusion revealed the presence of SARS-CoV-2 in the lungs.

Reasons for reinfection have not been widely studied, in part because immune response to SARS-CoV-2 has not been yet addressed.<sup>2</sup> Probably, immunosuppressive factors can contribute to limit viral clearance and to impair cellular and humoral immunity in COVID-19 as in other infections.<sup>3</sup> The clinical course of our patient agrees with this hypothesis. Although lymphocyte populations were normal at admission, in our patient concurred the personal history of the active neoplasia and the immunosuppression due to kidney transplant. Unfortunately, data regarding humoral or cellular immunity was not available after the first episode.

On this regard, reinfections can raise some concerns about the COVID-19 vaccines efficacy in those populations with risk factors for attenuating humoral immunity. In addition, pivotal COVID-19 vaccines randomized clinical trials have systematically excluded CKD patients so there is an important lack of information about their efficacy in that population. A very recent investigation letter has shown that a single dose of SARS-CoV2 mRNA vaccine generates a poor antispikes antibody response, situation than can explain a COVID-19 reinfection, especially more than 4 months before the primoinfection.<sup>4</sup> On the other hand, we must be cautious with those patients with prior episodes of COVID-19 who develop new symptoms and chest X-ray lesions and, of course, always recommend maintaining infection preventive measures.

In conclusion, reinfections in kidney transplants are plausible and require paying attention to those patients who developed COVID-19 symptoms even if they have had a previous episode.

## REFERENCES

1. Krishna E, Pathak VK, Prasad R, Jose H, Kumar MM. COVID-19 reinfection: linked possibilities and future outlook. *J Family Med Prim Care*. 2020;9:5445-9, <http://dx.doi.org/10.4103/jfmprc.jfmprc.1672.20>.
2. Kellam P, Barclay W. The dynamics of humoral immune responses following SARS-CoV-2 infection and the potential for reinfection. *J Gen Virol*. 2020;101:791-7, <http://dx.doi.org/10.1099/jgv.0.001439>.
3. Ling Y, Xu SB, Lin YX, Tian D, Zhu ZQ, Dai FH, et al. Persistence and clearance of viral RNA in 2019 novel coronavirus disease rehabilitation patients. *Chin Med J (Engl)*. 2020;133:1039-43, <http://dx.doi.org/10.1097/CM9.0000000000000774>.
4. Boyarsky BJ, Werbel WA, Avery RK, Tobian AAR, Massie AB, Segev DL, et al. Immunogenicity of a single dose of SARS-CoV-2

messenger RNA vaccine in solid organ transplant recipients. *JAMA*. 2021;325:1784-6, <https://doi.org/10.1001/jama.2021.4385>.

Borja Quiroga<sup>a,\*</sup>, Andrés Fernández Ramos<sup>a</sup>, Alicia Delgado Arroyo<sup>b</sup>

<sup>a</sup> Nephrology Department, Hospital Universitario de La Princesa, Madrid, Spain

<sup>b</sup> Intensive Care Unit, Hospital Universitario de La Princesa, Madrid, Spain

\* Corresponding author.

E-mail address: [borjaqg@gmail.com](mailto:borjaqg@gmail.com) (B. Quiroga).

<https://doi.org/10.1016/j.nefro.2021.04.013>

2013-2514/© 2021 Sociedad Española de Nefrología. Published by Elsevier España, S.L.U. This is an open access article under the CC BY-NC-SA license (<http://creativecommons.org/licenses/by-nc-sa/3.0/>).

# We must evaluate the previous kidney damage in the acute kidney failure due to COVID-19

## Debemos evaluar el daño renal previo en el fracaso renal agudo por COVID-19

Dear Editor,

On behalf of all the authors, we would like to convey our gratitude to you for showing interest in our publication, as reflected in your letter to the editor<sup>1,2</sup>.

The sample size is indeed a limitation of our work and this is reflected in the discussion, even though this is the largest Spanish prospective series to date of acute kidney injury (AKI) in patients with COVID-19 directly treated by nephrology. This implies a negative selection bias for the most critical patients who required referral to the nephrologist due to the severity of their condition, the need for dialysis or additional complications. Under no circumstances can we take our series of 41 patients as representative of AKI in the COVID-19 patient in general. In fact, our analysis approach is fundamentally descriptive. Our focus was on highlighting the tremendous variability of causes, clinical presentations and outcomes we have collected and which go beyond direct kidney involvement due to the SARS-CoV-2 infection or resulting from the cytokine storm. We wanted to give a perspective from the point of view of the nephrologist, providing clarity at a time when

there were large gaps in our knowledge. If you remember, the Ministry's COVID-19 report of April 2020 did not acknowledge chronic kidney disease (CKD) as a risk factor, and nor did it provide published evidence that AKI was a problem associated with COVID-19<sup>3</sup>.

As for the differential diagnosis between AKI and CKD, we specified in the methods section that the KDIGO criteria were used to diagnose AKI. It is then clarified in the section on baseline characteristics, within the results, that 36.6% of our population had underlying CKD. In our previous analysis of 1.600 patients admitted to the hospital as a whole during the first wave, the association of CKD and AKI was specifically analysed separately in the prognosis of the patients<sup>4</sup>. In the same issue, editorial comments precisely stress this point, the difficulty of separating pure AKI from the deterioration of pre-existing CKD<sup>5</sup>.

## REFERENCES

1. Tarragón B, Valdenebro M, Serrano ML, Maroto A, Llópez-Carratalá MR, Ramos A, et al. Acute kidney failure in