

after AZD1222 (Oxford-AstraZeneca) SARS-CoV-2 vaccination: Casuality or causality? *Kidney Int.* 2021;100:937–8, <http://dx.doi.org/10.1016/j.kint.2021.07.026>.

8. Plasse R, Nee R, Gao S, Olson S. Acute kidney injury with gross hematuria and IgA nephropathy after COVID-19 vaccination. *Kidney Int.* 2021, <http://dx.doi.org/10.1016/j.kint.2021.07.020>.
9. Tuschen K, Bräsen JH, Schmitz J, Viscchedyk M, Weidemann A. Relapse of class V lupus nephritis after vaccination with COVID-19 mRNA vaccine. *Kidney Int.* 2021, <http://dx.doi.org/10.1016/j.kint.2021.07.019>.
10. Da Y, Goh GH, Khatri P. A case of membranous nephropathy following Pfizer-BioNTech mRNA vaccine against coronavirus 2019. *Kidney Int.* 2021, <http://dx.doi.org/10.1016/j.kint.2021.07.016>.

Pehuén Fernández^{a,b,*}, María Luján Alaye^a,
María Emilia García Chiple^{b,c}, Javier De Arteaga^{a,b,d},
Walter Douthat^{a,b,d}, Jorge De La Fuente^{a,b,d},
Carlos Chiurchiu^{a,b,d}

^a Servicio de nefrología, Hospital Privado Universitario de Córdoba, Córdoba, Argentina

^b Instituto Universitario de Ciencias Biomédicas de Córdoba (IUCBC), Córdoba, Argentina

^c Servicio de anatomía patológica, Hospital Privado Universitario de Córdoba, Córdoba, Argentina

^d Fundación Nefrológica de Córdoba, Córdoba, Argentina

* Corresponding author.

E-mail address: pehuenfernandez@hotmail.com
(P. Fernández).

2013-2514/© 2021 Sociedad Española de Nefrología. Published by Elsevier España, S.L.U. This is an open access article under the CC BY-NC-ND license (<http://creativecommons.org/licenses/by-nc-nd/4.0/>).
<https://doi.org/10.1016/j.nefro.2021.09.007>

Hematuria in patients with IgA nephropathy after vaccine for SARS-CoV-2

Hematuria macroscópica en pacientes con nefropatía IgA tras vacuna para SARS-CoV-2

Dear Editor,

The devastating COVID-19 pandemic has led to rapid mass vaccination of the population in record time. Vaccine types different from classical inactivated virus or conjugate vaccines are being used for this purpose, based on the administration of a purified nucleoside of the virus messenger RNA (Moderna[®], Pfizer[®]) or virus DNA viral vector (AstraZeneca[®]).¹

Recently, several cases^{2–6} of patients with IgA nephropathy who developed macroscopic hematuria after administration of SARS-CoV-2 vaccines have been reported. We present three cases of patients with IgA nephropathy, vaccinated with different types of SARS-CoV-2 vaccine and being followed in our hospital, who developed macroscopic hematuria.

Case 1. A 52-year-old male under follow-up and being treated since 1995 for IgA nephropathy. His renal function was normal and he tested negative for proteinuria. He had not had COVID-19. He attended emergency department 48 h after administration of the second dose of the Moderna[®] vaccine due to onset of macroscopic hematuria. He was totally asymptomatic. After 24 h of observation, the clinical signs and symptoms resolved spontaneously. Macroscopic hema-

turia was confirmed by urgent assessment by the Laboratory Testing Department (Table 1).

Case 2. A 63-year-old male, diagnosed in December 2019 with IgA nephropathy with rapidly progressive component and extracapillary proliferation. He started peritoneal dialysis in October 2020. He was infected with COVID-19 in December 2020, with a good clinical course. He currently experiences bouts of asymptomatic macroscopic hematuria, which are self-limiting and disappear after resolution of the clinical signs and symptoms. Vaccination with the Moderna[®] vaccine started between February and March 2021. Onset of macroscopic hematuria occurred 48 h after the first dose, which disappeared 48 h later. There were no complications in his peritoneal dialysis treatment. The episode recurred after administration of the second dose of the vaccine (Table 1).

Case 3. A 45-year-old male, under follow-up for probable Henoch-Schonlein purpura and IgA nephropathy (episodes of dark urines coinciding with upper respiratory tract symptoms, purpuric dermatosis, etc.). He had not had COVID-19. The first AstraZeneca[®] vaccination dose was administered according to the schedule. After 24 h, macroscopic hematuria developed and continued for 36 h until it disappeared completely. He was asymptomatic at all times. This same clinical

DOI of original article:

<https://doi.org/10.1016/j.nefro.2021.09.005>.

Table 1 – Clinical data of the patients, before and after vaccination.

Patient	Age, years	Gender	IgA nephropathy diagnosis with biopsy	Vaccine	PCr mg/dl pre-vaccine	PCr mg/dl post-vaccine	US pre-vaccine	US post-vaccine	Associated symptoms
1	52	M	Yes	Moderna®	0.8	0.7	1–3 dysmorphic red blood cells/field	+100 dysmorphic red blood cells/field	No
2	63	M	Yes	Moderna®	3.5	3.9	10–30 dysmorphic red blood cells/field	+100 dysmorphic red blood cells/field	No
3	45	M	No	AstraZeneca®	1.5	1.3	20–40 dysmorphic red blood cells/field	15–20 dysmorphic red blood cells/field	No

PCr: plasma creatinine; US: urine sediment; M: male.

picture reoccurred after administration of the second vaccine dose. There was no purpuric dermatosis or other clinical manifestations (Table 1).

The development of glomerular diseases, especially vasculitis, secondary to the administration of vaccines for viruses or bacteria, is widely reported in the literature.^{2,3} With particular regard to SARS-CoV-2 vaccines, there have been reported small case series of patients with IgA nephropathy who developed macroscopic hematuria following administration of the first or second dose, or both.^{2–5}

It has been postulated that these vaccines trigger CD4 and CD8 T-lymphocyte activation, leading to a systemic cytokine cascade.¹ This cascade would be mediated by an increase in IgA1 production, which would lead to the development of a bout of macroscopic hematuria in these patients.^{2–5}

Recent cases have been described in patients who have received messenger RNA vaccines.^{2–4} In our series, two patients received a messenger RNA vaccine, while the other was administered a viral vector vaccine. In some cases, there were associated symptoms such as arthralgia, abdominal pain or urticaria.⁴ Our patients were asymptomatic throughout (Table 1). Occasionally, a transient increase in proteinuria has been described,^{2–5} coinciding with macroscopic hematuria, which is self-limiting over time. In our series, it was not possible to quantify the proteinuria, but there was no worsening of renal function. No treatment was required to correct the hematuria as the episodes were self-limiting within 24–72 h, consistent with the cases reported in the literature.^{2–5}

In our three patients, the onset of macroscopic hematuria occurred mainly with the administration of the second dose. This may lead to hesitancy in completing the vaccination regimen because of the risk of progression of glomerular disease. This recent debate, with the cases reported in the literature,^{6,7} could make this decision difficult. However, if we compare the possibility of developing a treatable flare-up after vaccination against the high mortality risk of COVID-19 in renal patients, we consider that completing vaccination in these particularly vulnerable patients is sufficiently justified.⁷

In conclusion, the use of this type of vaccine in patients with IgA nephropathy may cause macroscopic hematuria. In

our patients, the onset of the clinical picture was asymptomatic and resolved spontaneously. This side effect should alert us to monitor renal function and proteinuria in such patients. We believe it is important to complete SARS-CoV-2 vaccination and to achieve immunisation. More conclusive assessments are required to fully understand the effect of these vaccines on the renal population with IgA nephropathy.

Funding

The authors declare that they received no funding.

Conflict of interest

The authors declare that they have no conflicts of interest.

REFERENCES

- Martín De Francisco AL. Vacunas SARS-COV2 Mar. 2021. Catedrático medicina Universidad de Cantabria. Servicio de Nefrología HU Marqués de Valdecilla. [Accessed 22 July 2021]. Available from: www.nefrologiaaldia.org/es.
- Negrea L, Rovin BH. Gross Hematuria following vaccination for severe acute respiratory syndrome coronavirus 2 in 2 patients with IgA nephropathy. *Kidney Int.* 2021;99:1487–501.
- Gul Rahim SE, Lin JT, Wang JC. A case of gross hematuria and IgA nephropathy flare-up following SARS-CoV2 vaccination. *Kidney Int.* 2021;100:238.
- Perrin P, Bassand X, Benotmane I, Bouvier N. Gross hematuria following SARS-CoV-2 vaccination in patients with IgA nephropathy. *Kidney Int.* 2021;100:466–8, <http://dx.doi.org/10.1016/j.kint.2021.05.022>.
- Kudose S, Friedmann P, Albajrami O, D'Agati VD. Histologic correlates of gross hematuria following Moderna COVID-19 vaccine in patients with IgA nephropathy. *Kidney Int.* 2021;100:468–9, <http://dx.doi.org/10.1016/j.kint.2021.06.011>.
- Bomback AS, Kudose S, D'Agati VD. De novo and relapsing glomerular diseases after COVID-19 vaccination: What do we know so far? *Am J Kidney Dis.* 2021;78:477–80, <http://dx.doi.org/10.1053/j.ajkd.2021.06.004>.

7. Lim CC, Choo J, Tan CS. COVID-19 Vaccination in Immunoglobulin A Nephropathy. *Am J Kidney Dis.* 2021;78:317, <http://dx.doi.org/10.1053/j.ajkd.2021.07.001>.

Leonardo Calle Garcia^{a,*}, Carmen Martin Varas^a, Giomar Urzola Rodriguez^a, Maria Marcos Hidalgo^a, Astrid Rodriguez Gomez^a, Alvaro Molina Ordas^a, Veronica Fidalgo Gonzalez^a, Pablo Sanchez Garrote^a, Paulo Garcia Gutierrez^a, Marta Garcia de Burgos^b, Maria Jose Fernandez-Reyes Luis^a

^a Servicio de Nefrología, CA Segovia, Spain

^b Servicio de Análisis Clínicos, CA Segovia, Spain

*Corresponding author.

E-mail address: sailorleo20@hotmail.com (L. Calle Garcia).

2013-2514/© 2021 Sociedad Española de Nefrología. Published by Elsevier España, S.L.U. This is an open access article under the CC BY-NC-ND license (<http://creativecommons.org/licenses/by-nc-nd/4.0/>). <https://doi.org/10.1016/j.nefro.2021.09.012>

Persistent macroscopic hematuria as presentation of IgA nephropathy

Hematuria macroscópica persistente como presentación de nefropatía por IgA

Dear Editor,

IgA nephropathy is a prevalent glomerulopathy in the diagnostic work-up of haematuria and is the most common glomerular condition.^{1,2}

This autoimmune disease is characterised by abnormal synthesis and glycosylation of IgA, resulting in an imbalance and an increase in circulating galactose deficient IgA1 (Gd-IgA1).¹

The diagnosis is associated with a reduction in life expectancy of 6–10 years.²

Regarding treatment, patients with proteinuria above 500 mg/24 h should be started on ACE inhibitors/angiotensin II receptor blockers (ARBs). Steroids should be administered in patients with nephrotic proteinuria or in the group of patients at risk of progression to chronic kidney disease.^{3,4}

The course of the disease is glomerular in the usual forms of presentation, but there is very little information regarding the clinical course and its prognostic implications when the manifestation is persistent macroscopic haematuria as the only presenting sign of this glomerulopathy.^{5,6}

We present three clinical cases in which the presentation and common denominator is persistent macroscopic haematuria.

Case 1

A 38-year-old man, with no personal history of interest, was referred to the nephrology department for persistent macroscopic haematuria of 20 days' duration.

He had normal renal function and dysmorphic urinary red blood cells. Due to persistent macroscopic haematuria, a percutaneous renal biopsy was performed and IgA deposits were found on immunofluorescence (Fig. 1).

Steroid treatment was started at a dose of 1 mg/kg for three months in combination with losartan. The patient had very early complete remission, on the second day after starting

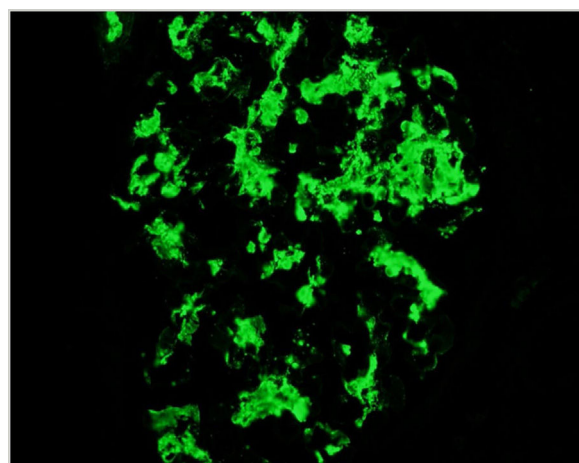


Fig. 1 – Immunofluorescence: IgA deposition.