

prescribed antihypertensive medication, along with a reversal of cardiomegaly demonstrated by follow-up chest x-ray.

In view of the patient's progressive recovery of kidney function along with increased diuresis, haemodialysis sessions were discontinued on 11 February 2020, with a creatinine level of 2.27 mg/dl. After that, her kidney function showed progressive improvement until reaching a creatinine level of 1.14 mg/dl without having required admission for exacerbations and/or complications. However, the patient sadly died in March 2021 due to a complicated respiratory infection.

We believe that thanks to the retrograde flow obtained towards the abdominal aorta and its branches (because the blood flow of the latter has lower pressure than that coming from the axillobifemoral bypass), renal function progressively improved, concomitantly resulting in clinical improvement and optimal control of blood pressure. Kidney function was preserved above 1.1 mg/dl despite the fact that patients with chronic kidney disease who have required dialysis for more than 90 days have little chance of recovering sufficient kidney function to be able to do without it.

In conclusion, this article reports a case of MAS as a cause of renovascular hypertension, with a clinical presentation that posed a challenge to its therapeutic management. The associated HTN was difficult to treat and required multiple therapeutic interventions, but which were ultimately successful.

## REFERENCES

1. Tummolo A, Marks SD, Stadermann M, Roebuck DJ, McLaren CA, Hamilton G, et al. Mid-aortic syndrome: long-term outcome of 36 children. *Pediatr Nephrol.* 2009;24:2225–32.

2. Sethna CB, Kaplan BS, Cahill AM, Velazquez OC, Meyers KE. Idiopathic mid-aortic syndrome in children. *Pediatr Nephrol.* 2008;23:1135–42.
3. Connolly JE, Wilson SE, Lawrence PL, Fujitany RM. Middle aortic syndrome: distal thoracic and abdominal caortctation, a disorder with multiple etiologies. *J Am Coll Surg.* 2002;194:774–81.
4. Uribe A. Síndrome aórtico medio. *Rev Col Vasc.* 2003;4(1), 418.
5. Sethna CB, Kaplan BS, Cahill AM, Velazquez OC, Meyers KE. Idiopathic mid-aortic syndrome in children. *Pediatr Nephrol.* 2008;23:1135–42.

S. Camino Ramos<sup>a,\*</sup>, A. Martín Rosique<sup>a</sup>, M. Terán Redondo<sup>a</sup>, X. Patricio Jacome Tapia<sup>b</sup>, F. Gabriel Yopez León<sup>a</sup>, E. Teresa Yerovi León<sup>a</sup>, V. Camarero Temiño<sup>a</sup>, P. Abaigar Luquin<sup>c</sup>, I. Agúndez Gomez<sup>d</sup>

<sup>a</sup> Médico del Servicio de Nefrología del Hospital Universitario de Burgos, Spain

<sup>b</sup> Médico del Servicio de Angiología y Cirugía Vasculardel Hospital Universitario de Burgos, Spain

<sup>c</sup> Jefe de Sección del Servicio de Nefrología del Hospital Universitario de Burgos, Spain

<sup>d</sup> Jefe de Sección del Servicio Deangiología y Cirugía Vasculardel Hospital Universitario de Burgos, Spain

\*Corresponding author.

E-mail address: [scrnefrologia@gmail.com](mailto:scrnefrologia@gmail.com) (S. Camino Ramos).

2013-2514/© 2024 Published by Elsevier España, S.L.U. on behalf of Sociedad Española de Nefrología. This is an open access article under the CC BY-NC-ND license (<http://creativecommons.org/licenses/by-nc-nd/4.0/>). <https://doi.org/10.1016/j.nefro.2024.03.016>

# De novo IgA nephropathy in a kidney transplant recipient after SARS-CoV-2 vaccination

## IgA de novo en trasplante renal tras vacunación frente a SARS-CoV-2

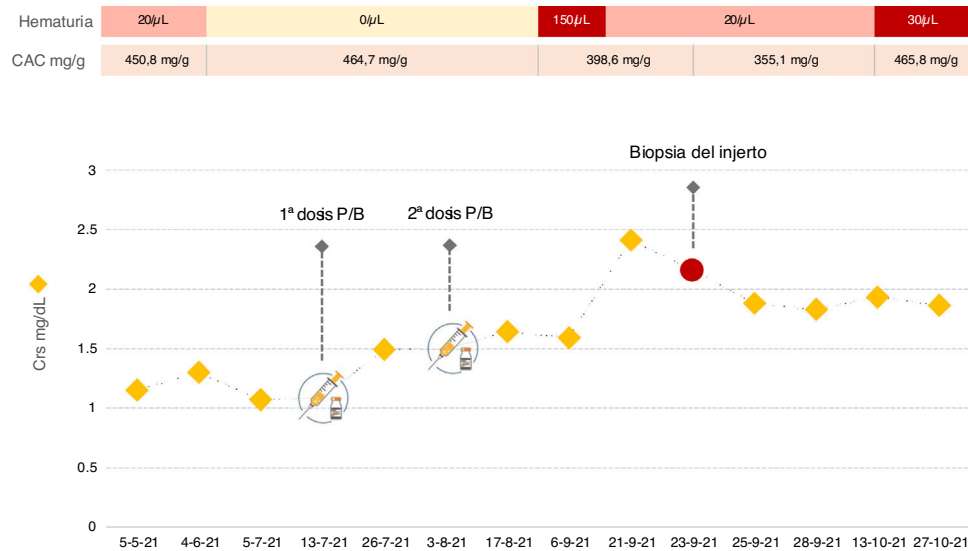


Dear Editor,

We present the case of a 30-year-old male diagnosed with membranoproliferative glomerulonephritis type 1 in 2011 and progression to end-stage chronic kidney disease. In 2019, he received a kidney transplant (KT), maintaining stable kidney function ever since, with baseline serum creatinine (sCr) around 1.1 mg/dl and albumin/creatinine ratio (ACR) in urine

of approximately 450 mg/g, without any other urinary sediment abnormalities. Immunosuppressive treatment included tacrolimus, mycophenolate mofetil and steroids. In April 2021, due to the development of condyloma acuminata, mycophenolate was replaced by everolimus. On 13/07/2021, he received the first dose of the Pfizer-BioNTech COVID-19 vaccine, with no documented adverse effects. Thirteen days later, in routine blood tests, a deterioration of renal function was found, with sCr 1.5 mg/dl. On 03/08/2021, he received the second dose and the deterioration in renal function progressed to sCr 2.4 mg/dl.

DOI of original article:  
<https://doi.org/10.1016/j.nefro.2021.11.002>.



**Fig. 1** – Serum creatinine, proteinuria and haematuria in our patient before and after vaccination against SARS-CoV-2. ACR: albumin/creatinine ratio; sCr: serum creatinine; P/B: Pfizer-BioNTech vaccine.

Simultaneously, the patient developed microhaematuria, with stable proteinuria (Fig. 1).

In view of the deterioration in kidney function, we performed tests. Donor-specific anti-HLA antibodies were negative. Determination of autoantibodies, proteins and complement were requested, which showed no abnormalities. Both cytomegalovirus and BK virus in blood were undetectable by PCR testing. Anti-SARS-CoV-2-S IgG antibodies and COVID-19 PCR were negative. In view of the microhaematuria, urine cytology was requested, which showed no abnormalities. Ultrasound of the graft also showed no ectasia of the urinary tract or abnormalities in vascularisation. For all these reasons, it was decided to perform a graft biopsy. On light microscopy, two out of nine glomeruli showed mesangial hypercellularity. Immunofluorescence study revealed intense granular mesangial IgA deposits (4+, on a scale of 0–4). Peritubular staining for C4d and SV-40 were negative and there were no findings consistent with acute rejection. Based on histological data, the patient was diagnosed with IgA nephropathy (IgAN). Although experience is limited in the treatment of IgAN in KT, given the deterioration in the patient's renal function, it was decided to start oral prednisone at a dose of 1 mg/kg/day. After a month of follow-up, there has been no improvement.

We present the first case of de novo IgAN confirmed by pathology study in a kidney transplant recipient after vaccination against SARS-CoV-2. The COVID-19 vaccine has been linked to the development of glomerular disease, and IgAN is one of the most common histological findings.<sup>1–4</sup> Cases of IgAN have also been described after recombinant Zoster or influenza vaccination.<sup>5,6</sup> The pathophysiological mechanism is not fully understood, but it is probably due to an aberrant immune response of the spike protein or messenger RNA of SARS-CoV-2 in predisposed individuals.<sup>1</sup> To date, there have been 15 published cases of IgAN after vaccination against SARS-CoV-2 in the general population. Ten are de

novo diagnoses confirmed by biopsy and the remaining five were considered recurrences due to a flare-up of macroscopic haematuria in previously diagnosed patients.<sup>1–4</sup> In KT, a single case of recurrence has been reported in a patient with IgAN as the underlying kidney disease and who developed haematuria after vaccination, although no graft biopsy was performed.<sup>4</sup>

IgAN can recur in KT, with an incidence of 20–53% and with a mean time of onset of seven years. Although rare, IgAN can also develop de novo in KT.<sup>7,8</sup> Our patient developed this complication early after vaccination. Although a coincidental association cannot be ruled out, the temporal relationship seems to suggest causality.<sup>9</sup> Moreover, he was a young man, on treatment with everolimus and HLA A2 and DR1, all of which are risk factors for IgAN in KT.<sup>10</sup> In the case described, the vaccine could have been another stimulus for the development of the condition.

Almost all reported cases of IgAN associated with vaccination against SARS-CoV-2 occurred in young patients and between weeks one and three after receiving the vaccine.<sup>1–4</sup> The main clinical manifestation was macroscopic haematuria. Most of the cases occurred after the second dose, but in the case of relapse in KT mentioned above, its onset was a few days after the first dose. In our patient, the deterioration in kidney function and the development of microhaematuria also began early, which may suggest that we need to be alert to the possibility of early development in KT, especially in patients at-risk.<sup>2,4,10</sup>

To date, 843 KT recipients at our centre have received at least two doses of the SARS-CoV-2 vaccine without having identified any more cases of IgAN (incidence 0.1% in our experience), which suggests that this is a rare event. However, although the follow-up of our patient has been short, this complication must be taken into account, as it could have serious consequences on the kidney graft function.

## Conflicts of interest

This study received no specific funding from public, private or non-profit organisations.

## REFERENCES

- Bomback AS, Kudose S, D'Agati VD. De novo and relapsing glomerular diseases after COVID-19 vaccination: what do we know so far? *Am J Kidney Dis.* 2021;78(4):477-80, <http://dx.doi.org/10.1053/j.ajkd.2021.06.004>.
- Abramson M, Mon-Wei Yu S, Campbell KN, et al. IgA nephropathy after SARS-CoV-2 vaccination. *Kidney Med.* 2021;3(5):860-3, <http://dx.doi.org/10.1016/j.xkme.2021.05.002>.
- Klomjit N, Alexander MP, Fervenza FP, et al. COVID-19 vaccination and glomerulonephritis. *Kidney Int Rep.* 2021, <http://dx.doi.org/10.1016/j.ekir.2021.09.008>. Online ahead of print.
- Perrin P, Bassand X, Benotmane I, et al. Gross hematuria following SARS-CoV-2 vaccination in patients with IgA nephropathy. *Kidney Int.* 2021;100(2):466-8, <http://dx.doi.org/10.1016/j.kint.2021.05.022>.
- Rahim SEG, Lin JT, Wang JC. A case of gross hematuria and IgA nephropathy flare-up following SARS-CoV-2 vaccination. *Kidney Int.* 2021;100(1):238, <http://dx.doi.org/10.1016/j.kint.2021.04.024>.
- McNally A, McGregor D, Searle M, et al. Henoch-Schönlein purpura in a renal transplant recipient with prior IgA nephropathy following influenza vaccination. *Clin Kidney J.* 2013;6(3):313-5, <http://dx.doi.org/10.1093/ckj/sft029>.
- Ponticelli C, Traversi L, Feliciani A, Gesana BM, Banfi G, Tarantino A. Kidney transplantation in patients with IgA mesangial glomerulonephritis. *Kidney Int.* 2001;60(5):1948-54, <http://dx.doi.org/10.1046/j.1523-1755.2001.00006.x>.
- Uffing A, Pérez-Saéz MJ, Jouve T, et al. Recurrence of IgA nephropathy after kidney transplantation in adults. *Clin J Am Soc Nephrol.* 2021;16(8):1247-55, <http://dx.doi.org/10.2215/CJN.00910121>.
- Cazorla-López JM, Wu J, Villanego-Fernández F, et al. IgA nephropathy after renal transplant: recurrences and de novo cases. *Transplant Proc.* 2020;52(2):515-8, <http://dx.doi.org/10.1016/j.transproceed.2019.12.008>.
- Von Visger JR, Gunay Y, Andreoni KA, et al. The risk of recurrent IgA nephropathy in a steroid-free protocol and other modifying immunosuppression. *Clin Transplant.* 2014;28(8):845-54, <http://dx.doi.org/10.1111/ctr.12389>.

M. Alonso\*, F. Villanego, Ó. Segurado, L.A. Vígara, C. Orellana, T. García, A. Mazuecos

*Servicio de Nefrología, Hospital Universitario Puerta del Mar, Cádiz, Spain*

\* Corresponding author.

E-mail addresses: [m.alonsom94@gmail.com](mailto:m.alonsom94@gmail.com) (M. Alonso), [tino.villanego@gmail.com](mailto:tino.villanego@gmail.com) (F. Villanego), [oscarstz86@hotmail.com](mailto:oscarstz86@hotmail.com) (Ó. Segurado), [luisberbig@gmail.com](mailto:luisberbig@gmail.com) (L.A. Vígara), [cristhian1124@hotmail.com](mailto:cristhian1124@hotmail.com) (C. Orellana), [teresa\\_garcia\\_alvarez@yahoo.es](mailto:teresa_garcia_alvarez@yahoo.es) (T. García), [mauxiliadora.mazuecos.sspa@juntadeandalucia.es](mailto:mauxiliadora.mazuecos.sspa@juntadeandalucia.es) (A. Mazuecos).

2013-2514/© 2024 Published by Elsevier España, S.L.U. on behalf of Sociedad Española de Nefrología. This is an open access article under the CC BY-NC-ND license (<http://creativecommons.org/licenses/by-nc-nd/4.0/>). <https://doi.org/10.1016/j.nefro.2024.03.012>

# Levotiroxin intoxication; role of extracorporeal techniques

## Intoxicación por levotiroxina; papel de las técnicas extracorpóreas

Intoxication is a common disorder in hospital Accident and Emergency departments, especially drug poisoning<sup>1,2</sup> (50% of cases). Clinical consequences and severity will depend on the characteristics of the poisoning agent and its metabolites, volume of distribution, molecular weight and protein affinity.<sup>3</sup> Furthermore, comorbidities such as kidney or liver failure can cause a greater toxicity.

The first step in treating intoxications consists of maintaining the clinical and haemodynamic stability of the patient and avoid intestinal absorption of the toxic compound through

emesis.<sup>3</sup> Additional measures are sometimes required, such as extracorporeal blood purification techniques (EBPT), including haemodialysis and haemoperfusion, which promote blood purification of toxins generated endogenously by organ failure or exogenous poisoning.<sup>4,5</sup>

We present two overlapping cases of levothyroxine poisoning treated with haemoperfusion (HP).

Two female patients aged 50 and 53 years were admitted for attempts at self harm, in the first case (case 1), having taken 100 levothyroxine 50 mcg tablets and in the second case (case 2), 75 levothyroxine 50 mcg tablets. The patients had no relevant previous medical history.

DOI of original article:

<https://doi.org/10.1016/j.nefro.2021.11.006>.

