



Acute interstitial tubulo nephritis associated with statin treatment

Nefritis tubulointerstitial aguda asociada al tratamiento con estatinas

To the Editor,

Acute tubulointerstitial nephropathy is a type of renal injury characterized by the presence of inflammatory infiltrates, edema, and tubulitis in the interstitial compartment, and it is often accompanied by acute failure.¹ It represents the third most frequent cause of acute renal function impairment in hospitalized patients,² with an incidence of 5–27% in renal biopsies performed for diagnosis of acute renal failure.^{3,4} Its course may be subclinical or it may present progressive deterioration evolving into chronic renal failure. Its etiology is diverse, with immunoallergic reaction to drugs being the most frequent cause, with a prevalence of approximately 60–70%.⁵

We present the clinical case of a patient with a pathological diagnosis of acute tubulointerstitial nephritis with hyaline arteriopathy secondary to treatment with statins.

The patient is a 69-year-old woman with a personal history of vascular risk factors: high blood pressure, mixed dyslipidemia on treatment with pravastatin, and ischemic heart disease that require a stent. She came to the emergency room with symptoms of asthenia, vomiting, and low blood pressure. These symptoms were accompanied by foamy urine with preserved diuresis, without dark urine or hematuria, of approximately two months' duration. Laboratory tests showed acute deterioration of renal function with creatinine 6.82 mg/dl (previously preserved renal function), metabolic acidosis (pH 7.28 with HCO₃ 15.5 mmol/l), hemoglobin 9.1 g/dl, and eosinophilia 7.2%. Finally, it was decided to admit her to the Nephrology department for study due to non-oliguric acute renal failure refractory to initial medical treatment and observation.

Due to the suspicion of a possible systemic disease with renal involvement, a study of secondary causes was performed, highlighting a normal autoimmune profile except for the presence of positive ANA values (ANA 1/320, homogeneous pattern). Regarding the rest of the complementary tests, the proteinogram, immunoglobulins and complement were within normal range, as well as neg-

ative viral serologies. A renal ultrasound was performed, which reported normal-sized kidneys with preserved cortical thickness without urinary tract dilation. It was decided to administer 3 boluses of methylprednisolone 250 mg for the treatment of a probable acute interstitial nephropathy, with adequate renal response in the first 48 h after starting corticosteroid treatment (creatinine 4.42 mg/dl). Finally, an ultrasound-guided percutaneous renal biopsy was performed with a pathological result (Fig. 1) of evolving tubulointerstitial nephritis (cytoplasmic acidophilia, nuclear pyknosis, loss of the brush border, flattening and detachment of the tubular epithelium) with moderate hyaline arteriopathy. The patient was subsequently discharged with follow-up by Nephrology, presenting stable renal function with creatinine of 3 mg/dl.

However, the year after hospital admission, the patient again presented two clinical symptoms similar to those of the first admission (Fig. 2). As a novelty, in the second admission she started treatment only with simvastatin/ezetimibe and the third admission she had started treatment with atorvastatin, presenting in addition with the deterioration of renal function a generalized skin rash. Progressive deterioration of renal function was notable (peak creatinine of 8.06 mg/dl). Finally, she responded on all occasions to corticosteroid therapy, thus the cause of acute renal failure in the last two admissions was associated with the use of statins. Allergy study was completed and currently she is being treated with alirocumab, maintaining lipid levels within the range (total cholesterol 145 mg/dl, HDL 49 mg/dl and LDL 38 mg/dl) and the renal function is preserved (creatinine 1.29 mg/dl).

Today, statins are one of the most prescribed drugs for the treatment of dyslipidemia. One of the side effects described in relation to the use of statins is rhabdomyolysis due to myotoxicity in 2–11% of patients,^{6,7} with the presence of myoglobinuria being attributed to the development of acute interstitial nephritis.⁸ However, acute interstitial nephropathy is a rare cause of acute renal failure.

The importance of this clinical case lies in the fact that it is essential to ask the patient about the recent medication received, changes in treatment or the introduction of new drugs, since in many cases it is difficult to establish the causal agent of the pathology. It should be taking into account that kidney damage does not always correlate directly with the

DOI of original article:

<https://doi.org/10.1016/j.nefro.2024.03.004>.

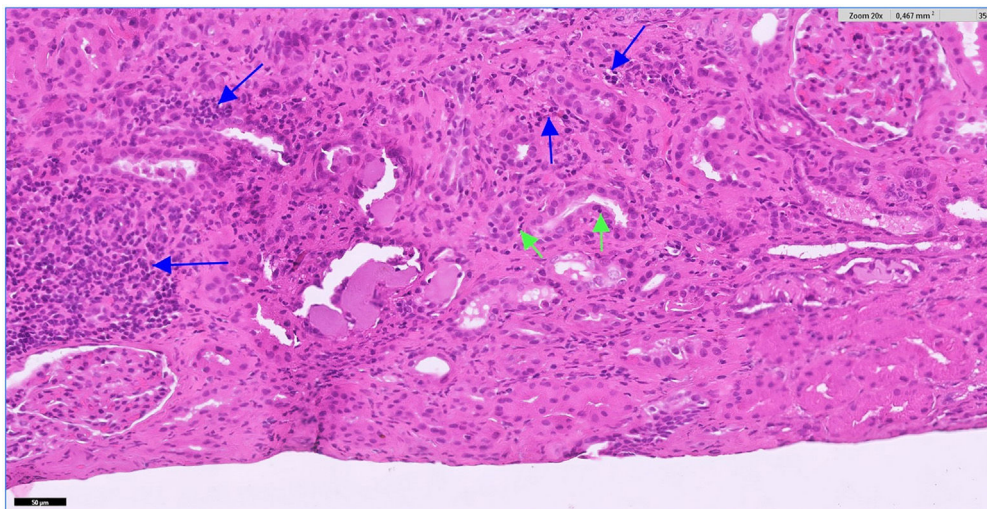


Fig. 1 – Foci of inflammatory infiltrate are observed in the cortex, forming patches and also arranged in a dispersed manner. It is mainly composed of lymphocytes (blue arrows). Focally, the infiltrate affects the tubules (tubulitis) (green arrows). Hematoxylin-eosin $\times 20$. The color of the figures can only be seen in the electronic version of the article.

EVOLUCIÓN DEL FILTRADO GLOMERULAR (CKD-EPI)

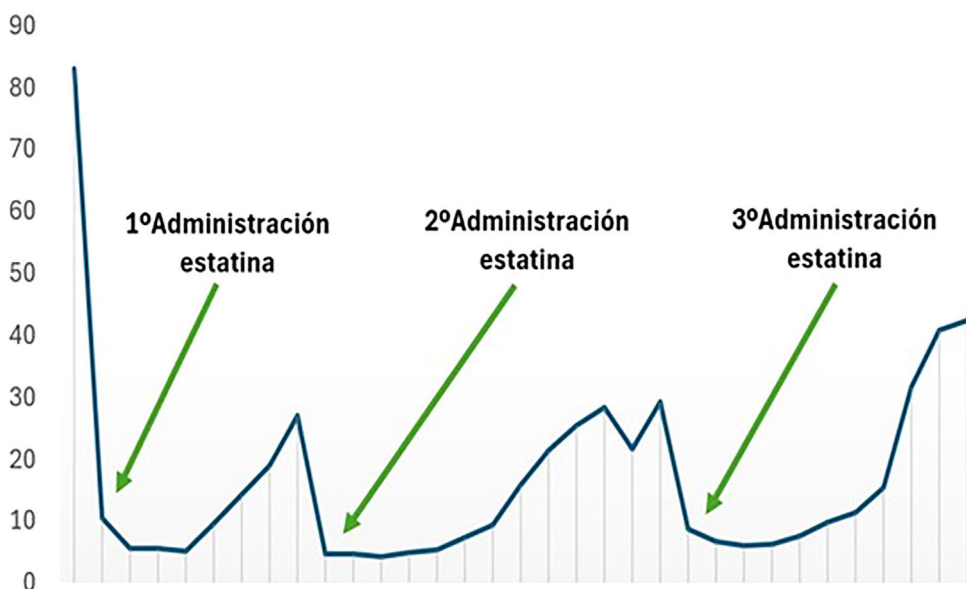

Fig. 2 – Evolution of glomerular filtration rate expressed by CKD-EPI formula (ml/min) associated with the moments of administration of the statin, observing a decrease in glomerular filtration rate coinciding with the administration of such drug.

initiation of the drug and the clinical manifestations can be variable.

Ethical aspects

The authors declare that they have followed the protocols established in their work center to access the data of the patient's clinical history to be able to write this manuscript aiming to be disseminated to the scientific community.

Funding

This research has not received specific financial aid from public sector agencies, the commercial sector or non-profit entities.

Declaration of competing interest

The authors declare that they have no conflict of interest.

REFERENCES

1. Caravaca-Fontán F, Fernández-Juárez G, Praga M. Acute kidney injury in interstitial nephritis. *Curr Opin Crit Care*. 2019;25(6):558–64.
2. Raghavan R, Shawar S. Mechanisms of drug-induced interstitial nephritis. *Adv Chronic Kidney Dis*. 2017;24(2):64–71.
3. Praga M, Sevillano A, Aunon P, Gonzalez E. Changes in the aetiology, clinical presentation and management of acute interstitial nephritis, an increasingly common cause of acute kidney injury. *Nephrol Dial Transplant*. 2015;30(9):1472–9.
4. Muriithi AK, Leung N, Valeri AM, Cornell LD, Sethi S, Fidler ME, et al. Biopsy-proven acute interstitial nephritis, 1993-2011: a case series. *Am J Kidney Dis*. 2014;64(4):558–66.
5. Perazella MA, Markowitz GS. Drug-induced acute interstitial nephritis. *Nat Rev Nephrol*. 2010;6(8):461–70.
6. Ucar M, Mjorndal T, Dahqvist R. HMG-CoA reductase inhibitors and myotoxicity. *Drug Saf*. 2000;22:441–57.
7. Evans M, Rees A. The myotoxicity of statins. *Curr Opin Lipidol*. 2002;13:415–20.
8. Golev GD. Myoglobinopathy as a cause of acute interstitial nephritis. *Klin Med (Mosk)*. 1990;68:92–5.

Miguel Ángel González Martínez^{a,*},
Dora Angélica Varillas Caso^a, María Ramírez Gómez^a,
Mercedes Caba Molina^b

^a Servicio de Nefrología, Hospital Universitario Clínico San Cecilio, Granada, Spain

^b Servicio de Anatomía Patológica, Hospital Universitario Virgen Delas Nieves, Beiro, Granada, Spain

*Corresponding author.

E-mail addresses: miguel.agm1505@gmail.com (M.Á. González Martínez), varillascaso@gmail.com (D.A. Varillas Caso), marago87@gmail.com (M. Ramírez Gómez), merchecabamolina2@gmail.com (M. Caba Molina).

2013-2514/© 2024 Published by Elsevier España, S.L.U. on behalf of Sociedad Española de Nefrología. This is an open access article under the CC BY-NC-ND license (<http://creativecommons.org/licenses/by-nc-nd/4.0/>).
<https://doi.org/10.1016/j.nefro.2024.10.004>

Profile hypersensitivity to the hemodialysis dializer

Perfilando la hipersensibilidad al dializador de hemodiálisis



Mr. Director,

Anaphylactic or anaphylactoid reactions during hemodialysis (HD) have been recorded since 1975.¹ The bio-incompatibility of the materials may be the cause.²

In the last decade, reactions associated with the use of synthetic membranes, generally polysulfones, have been described as “allergic”, “hypersensitive” or “anaphylactic”.^{1,3-5}

The different forms of presentation, from more to less frequent, are: dyspnea, hypotension, bronchospasm, cough, vomiting and other GI symptoms, precordial pain, pruritus, urticaria, fever, headache and confusion. Eosinophilia, increased serum tryptase or hypocomplementemia help in differential diagnosis.⁶

Allergic reactions to synthetic hemodialysis membranes have been described with the use of different membranes: polysulfone, polyethersulfone, polyneprone, polyarylethersulfone and polyacrylonitrile.^{4,7} If changed to cellulose triacetate (CT) membranes, there were no further reactions.^{5,8}

Rodríguez-Sanz et al. conclude that basophil degranulation and elevated tryptase levels, which occurred during the acute reaction in 7 patients, that were allergic to synthetic

membranes, demonstrate that there is the activation of mast cells and basophils.⁹ Years later, the same authors performed a study in 29 patients using polysulfone membranes and found alterations in tryptase levels, complement activation and interleukin-6 (IL-6) levels during acute reactions.¹⁰

Our main objective was to measure serum levels of tryptase, IL-6, complement (C3 and C4) in 3 groups of dialyzers: Group 1, synthetic membranes in post-dilution online hemodiafiltration (HDFOL), Group 2 with asymmetric TAC membranes (TACA) in HDFOL and Group 3 with synthetic membranes in extended HD (HDx).

As secondary objectives we observed the association of the presence of lymphopenia, eosinophilia, thrombocytopenia and chronic pruritus among the group of patients with allergies to synthetic membranes (using TACA membranes) vs. patients without allergies to these synthetic membranes.

This is an observational, retrospective, cross-sectional, descriptive-comparative, retrospective study of all patients in the hemodialysis unit of the Hospital Universitario Infanta Sofía older than 18 years of age who have been on HD for more than 3 months and with the same dialysis membrane for more than one month.

Statistical analysis was performed with SPSS® version 25 software.