



Tubulointerstitial nephritis associated with treatment with selective Cox-2 inhibitors, Celecoxib and Rofecoxib

M. Ortiz, C. Mon, M. J. Fernández, R. Sánchez, F. Álvarez Ude and F. Mampaso*

Nephrology Department. Hospital de Segovia. *Pathology Department. Hospital Ramón y Cajal

SUMMARY

The nephrotoxic effect of nonselective nonsteroidal anti-inflammatory drugs (NSAIDS) has been widely described. The main benefit of the Cox-2 inhibitors in relation to the NSAIDS is the production of a very similar analgesic effect, but with fewer gastrointestinal side effects. However, their effects on renal function are little known as yet and their long-term safety is still pending definition. The use of selective Cox-2 inhibitors as anti-inflammatory analgesic is becoming more and more common in our environment. We report two cases of tubulointerstitial nephritis confirmed by renal biopsy, associated with administration of the two Cox-2 inhibitors currently available on the market, celecoxib and rofecoxib. In both cases, we were talking about elderly women, with deterioration of the general condition and acute renal failure. In the former case, renal biopsy showed an acute tubulo-interstitial nephritis (TIN) so highly «variegated» in its histologic expression. In the second case, was associated with strong indications of chronicity. Treatment with steroid was initiated in both patients and improvement of renal function was observed.

Key words: *Cox-2 selective inhibitors. Acute and Chronic tubulointerstitial nephritis.*

NEFRITIS TUBULOINTERSTICIAL ASOCIADA AL TRATAMIENTO CON INHIBIDORES DE LA COX-2, CELECOXIB Y ROFECOXIB

RESUMEN

El efecto nefrotóxico de los inhibidores selectivos de la Cox-2 es poco conocido. El principal beneficio de los inhibidores de la Cox-2 con respecto a los AINES clásicos es la producción de un efecto analgésico muy similar, pero con menos efectos secundarios a nivel gastrointestinal. Sin embargo, sus efectos sobre la función renal son poco conocidos todavía y su seguridad a largo plazo está todavía por definir. El uso de inhibidores selectivos de la Cox-2 como analgésico y antiinflamatorios es cada vez más frecuente en nuestro medio. Nosotros referimos dos casos de nefritis tubulointerstitial

Recibido: 5-III-2004.

En versión definitiva: 7-VI-2004.

Aceptado: 7-VI-2004.

Correspondence: Dra. Milagros Ortiz
Servicio de Nefrología. Hospital Universitario de Segovia.
Carretera de Ávila s/n.
40002 Segovia (España)
E-mail: milaortiz@wanadoo.es

confirmadas por biopsia renal, asociadas a la toma de los dos inhibidores de la Cox-2 comercializados en la actualidad, celecoxib y rofecoxib. Ambos se presentaron en mujeres de edad avanzada, cursaron con importante afectación del estado general y fracaso renal agudo. En el primer caso, la biopsia renal mostró una nefritis tubulointersticial aguda (NTI) muy abigarrada en su expresión histológica. En el segundo, se asoció con importantes datos de cronicidad. Los dos casos se trataron con esteroides con buena evolución de la función renal.

Palabras clave: **Inhibidores selectivos de la Cox-2, nefritis tubulointersticial.**

INTRODUCTION

The nephrotoxic effect of non-selective non-steroidal anti-inflammatory drugs (NSAIDs) is widely described being able to produce water and electrolytic imbalances, AHT, hemodynamic renal failure, glomerular damage, papillary necrosis, and tubulointerstitial nephritis (TIN)¹⁻³. The main benefit from COX-2 inhibitors as compared with non-selective NSAIDs lies in achieving a very similar analgesic and anti-inflammatory effect but with less gastrointestinal side effects⁴⁻⁷. However, effects on renal function and at other levels are still little known⁸ and their long-term safety has yet to be defined. The increasingly older age of our population, the more frequent use of analgesic and anti-inflammatory drugs for chronic diseases treatment and self-administered medication will probably determine higher renal iatrogenic effects related to these drugs.

CLINICAL CASES

Case I

An eighty-three years old woman with a history of diet-controlled arterial hypertension, mild chronic bronchitis and transient vertebrobasilar ischemic accident in 1994, for which she was on anti-aggregation with acetyl salicylic acid at a 100 mg/day dose. Fifteen days before admission she starts with general condition impairment, fatigue and weakness at lower extremities. One week after the onset of symptoms she experiences hands and ankles swelling and lower limbs pain initiating treatment with celecoxib 200 mg/day. Six days after initiating that treatment, she states general condition worsening for which she seeks emergency care.

On physical examination she was pale and had a certain degree of mucocutaneous dehydration. No cutaneous lesions were evident. The laboratory analysis showed the following parameters: 12,180 leucocytes/mcL without eosinophilia, Hb 9 gr/dL, hematocrit 28.4%, MCV 78.2 fl and platelets 276,000/mcL. Cre-

atinine at admission was 4.7 mg/dL. Potassium was 4.6 mEq/L with accompanying metabolic acidosis. Urine sediment had 3-6 red blood cells/field. Twenty-four hour urine proteinuria was 0.76 g. CRP was 5 mg/dL. Urine culture was negative. Blood and urine electrophoresis, immunoglobulins and complement (C3 and C4) were normal. Rheumatoid factor was less than 20 IU/mL. Antinuclear, anti-glomerular basement membrane, and ANCA antibodies were negative; also negative were HBV, HCV and HIV serology tests. Renal ultrasounds showed kidneys with normal size and morphology, with a good cortical width. During hospital admission, she had unknown origin fever, the microbiologic study being negative.

Due to the lack of renal function improvement once possible functional factors were corrected, a renal biopsy was performed. It showed 10 glomeruli, none of them with sclerosis, together with important tubulointerstitial damage (figs. 1, 2): severe tubular epithelium necrosis with presence of apoptotic cells; tubular lumen occupation by cellular debris at different necrosis stages with acute inflammatory cells accumulation (microabscesses) and monocytic lineage cells with pseudogranulomas for-

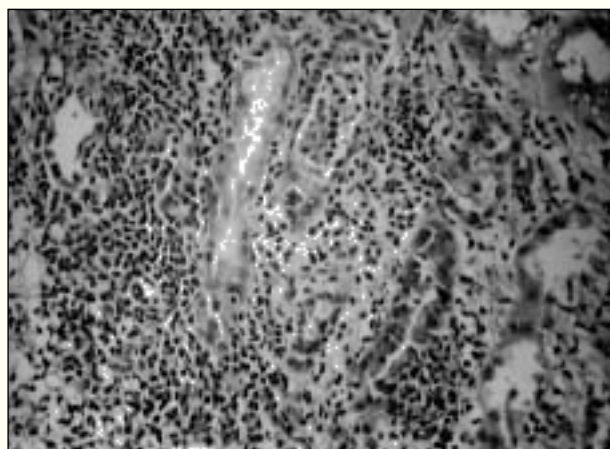


Fig. 1.—Severe diffuse interstitial inflammatory mononuclear infiltrate that involves by extension the renal tubule. «Tubulitis» phenomena and of severe acute tubular necrosis can be seen. Case I. (HE \times 260).

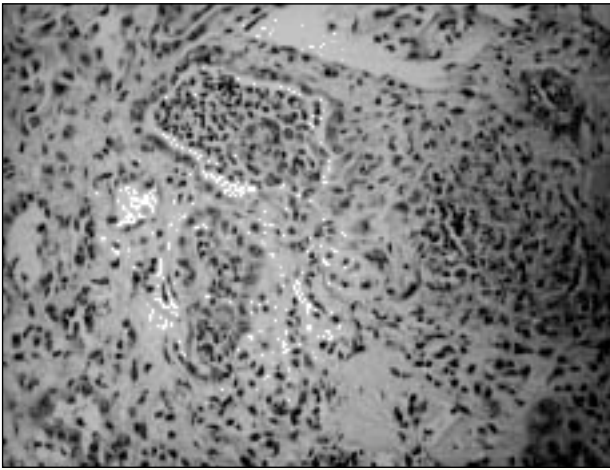


Fig. 2.—The cellular inflammatory infiltrate occupies the tubular lumen with images that correspond to microabscesses and pseudogranulomas formation. Case I (HE \times 250).

mation; tubulitis; lymphoplasmocytic interstitial inflammatory infiltrates with scattered neutrophils and eosinophils; abundant nuclei of tubular epithelium with degenerative signs showing ground glass images and/or vesicles and/or rounded eosinophilic inclusions. Biopsy also showed severe angiosclerosis. These data suggested the presence of an acute severe TIN, suspecting a relation with celecoxib taking into account the treatment history with that drug. Immunofluorescence was negative and electronic microscopy study was normal.

With an initial suspicion of vasculitis with renal involvement, empiric treatment was started with bolus intravenous steroids (0.5 g/day, for three days) and thereafter at a 1mg/kg/day dose p.o.. Considering renal biopsy results and that renal function deterioration persisted once celecoxib was interrupted, it was decided to maintain this treatment. In the following days, progressive renal function improvement was observed until reaching base-line values (0.9 mg/dL), proteinuria and systemic symptomatology fading away.

Case II

A 79 years old woman with a history of arterial hypertension treated with spironolactone, hypercholesterolemia treated with statins, hiatal hernia with secondary ferropenic anemia treated with oral iron substitute, colonic diverticulosis, and generalized osteoarthritis began treatment with rofecoxib 12.5 mg/day for 7 days for back pain. Four weeks after initiating treatment, she began with bad general condition, low-grade fever, and important fatigue and anorexia. Fifteen days after the onset of symptoms she presented to the emergency

room. In a laboratory work-up performed 3 months before for an acute gastroenteritis, renal function was normal (creatinine 0.9 mg/dL).

On physical examination she was pale and showed signs of mild dehydration. She did not show cutaneous lesions, and she denied having had them before. Laboratory analysis showed the following parameters: 7360 leucocytes/mcL without eosinophilia, Hb 11.8 gr/dL, hematocrit 34.9%, MCV 95.1 fl and 233,000 platelets/mcL. Serum BUN was 126 mg/dL and creatinine 3.9 mg/dL. Potassium was 4.9 mEq/L without metabolic acidosis. Urine sediment had 10-15 L/field. Twenty-four hour urine proteinuria was negative. Urine cultures were negative. Blood and urine electrophoresis, immunoglobulins and complement (C3 and C4) were normal. ESR was 100, CRP 4.47 and rheumatoid factor 60. Antinuclear, anti-glomerular basement membrane and ANCA antibodies were negative. HBV, HCV and HIV serologies were negative. Renal ultrasounds showed kidneys with normal size and morphology, with small cysts next to the renal pelvis, in the left kidney. During admission no fever was observed, although fatigue remained.

Diuretic treatment was stopped and fluid therapy was started in order to correct possible associated functional factors, observing a discreet decrease of creatinine values down to 3 mg/dL. However, because of renal function stagnation in spite of initial improvement, a renal biopsy was performed (figs. 3, 4 and 5). It showed 20 glomeruli, 5 of them with sclerosis. The remaining glomeruli were microscopically normal or presented unspecific discreet changes. It was surprising the presence of an extent mononuclear interstitial inflammatory infiltrate (40% of the sample) with an irregular and diffuse distribution. Together with this infiltrate, there were wide areas

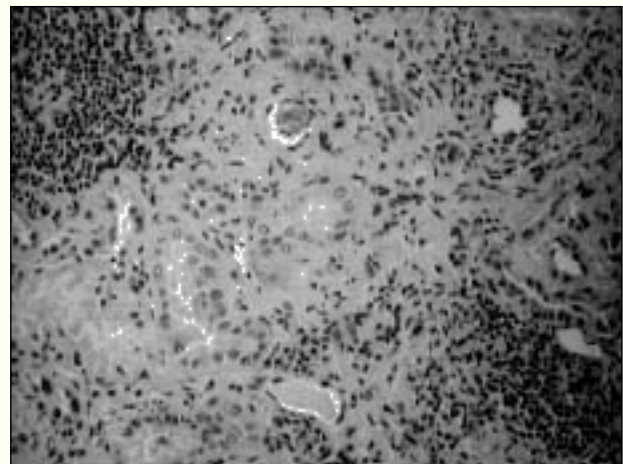


Fig. 3.—Mononuclear infiltrate of the renal interstitium and focal fibrosis. Case II (HE \times 250).

of interstitial fibrosis with severe tubular atrophy. Small arterial vessels showed degenerative lesions. Immunofluorescence study was negative. Electronic microscopy was normal. All was in agreement with severe tubulointerstitial nephritis.

Because of progressive renal function worsening, in spite of drug withdrawal and persistence of inflammatory signs in the biopsy, steroidal treatment 1 mg/kg/day was started. In the following weeks, a decrease in creatinine values was observed until reaching 1.5 mg/dL, thus the patient was left with some degree of renal insufficiency.

DISCUSSION

Use of selective COX-2 inhibitors as analgesic-antiinflammatory drugs is more and more common in our setting, especially in those patients for whom conventional antiinflammatory drugs are limited because of gastrointestinal pathology. Many times, they are elderly patients in whom renal hemodynamics may be altered more easily. Mechanism of action of these drugs could result in an increased analgesic and antiinflammatory effect mediated by selective inhibition of COX-2 isoenzyme, while diminishing gastrointestinal toxicity⁴⁻⁷ and perhaps also at other levels⁸ because they lack of an effect on COX-1 isoform. However, used at high doses they can inhibit the latter at a certain degree. The effect of COX-2 enzyme selective inhibition at the kidney is still unclear. The enzyme locates at the macula densa, ascendant thin limb of Henle's loop and interstitial

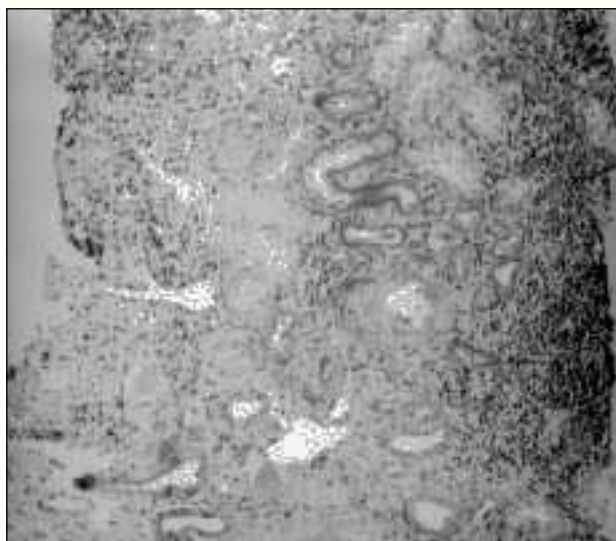


Fig. 4.—Large view showing severe tubular damage with advanced signs of atrophy. Case II. (HE x 30).

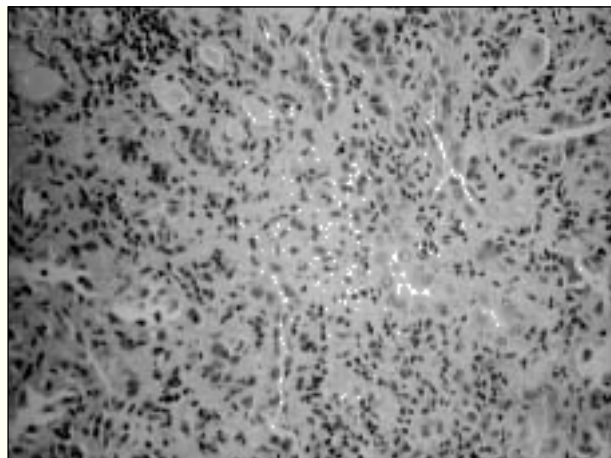


Fig. 5.—Focally distributed, fibrosis and tubular atrophy showed a high degree severity. Case II. (HE x 250).

papillary cells in rats and dogs, whereas it is only present at the podocytes, small arteries, arterioles and venules in humans and monkeys, hence having to be cautious when extrapolating laboratory findings obtained in animals to human species⁹. Several studies suggest that COX-2 isoenzyme could play an important role in normal human kidney development during embryogenesis¹⁰⁻¹³. Only in those patients in whom prostaglandins secretion is essential to maintain a glomerular filtration rate (volume depletion, heart failure, cirrhosis, chronic renal failure, hypercalcemia, diuretics and/or other nephrotoxic drugs treatment, older age), hemodynamic renal failure has been observed when using COX-2 selective inhibitors. Also, there have been described severe water and electrolytic impairments (especially hyperkalemia and metabolic acidosis) clearly facilitated by these drugs¹⁴⁻¹⁷ and arterial hypertension episodes in normotensive patients, and decompensation in hypertensive patients, essentially related to rofecoxib^{18,19}. These data suggest that COX-2 selective inhibition at the kidney leads to similar consequences as those seen with classical NSAIDs, therefore, in theory, we should take the same precautions when they are administered to patients at risk^{19,20}.

Presented cases correspond to two old women. In the first one, renal failure with sediment changes, elevation of acute phase reactants, arthralgias, and fever of unknown origin with negative microbiologic study raised the suspicion of vasculitis with renal involvement. For that reason, bolus intravenous steroidal treatment was initiated and continued p.o.. Biopsy showed the presence of acute TIN, with highly mixed histological features and severe involvement of tubuli and the interstitium. In the second case, however, renal failure together with low-grade

fever and sterile leukocyturia raised the possibility of TIN. Renal biopsy confirmed the diagnosis, also showing important data of chronic changes. It was treated with oral steroids. In both cases an improvement of renal function was observed. In the second one, possibly due to chronic changes, patient remained with a certain degree of renal insufficiency.

There was no evidence for other TIN causes in neither cases. In the first one, the patient was receiving acetyl salicylic acid treatment since 1994, which made this factor being responsible very unlikely. Our second patient also was receiving treatment with potassium sparing diuretics, statins, and iron for several years. In this latter case, the COX-2 inhibitor and diuretic interaction could have contributed, in part, to renal failure through a hemodynamic mechanism. In both cases, both patients were elderly and the disease was accompanied by an important general condition impairment.

Non-selective NSAIDs are one the most frequently TIN-associated drugs. To date, there are few described cases of acute TIN associated with COX-2 inhibitors; two with rofecoxib^{21,22} and four with celecoxib²³⁻²⁶. In the latter two cases they occur in association with nephropathies (minimal changes N. and membranous N.). In approximately half of the cases, patients were treated with steroids and/or hemodialysis. In all of them, an improvement of renal function was observed. Since rofecoxib marketing, from 1999 to July of 2001, 16 cases with a possible diagnosis of TIN have reported to the pharmaceutical company that manufactures the drug, referred by authorities all over the World. Two patients had alternative causes for their renal symptomatology (diabetic nephropathy and glomerulonephritis). Only two cases had biopsy but were not referred. In the remaining 12 cases, diagnosis was not confirmed²⁷. To date, progression to chronic TIN has not been described with COX-2 inhibitors.

Our two cases highlight that selective COX-2 inhibitors, similarly to non-selective NSAIDs, may be associated with TIN development. The ever growing use of these drugs will allow us to establish in the coming years the frequency of this side effect and their global safety profile.

REFERENCES

- Schlondorff D: Renal complications of nonsteroidal antiinflammatory drugs. *Kidney Int* 44: 643-653, 1993.
- Brater DC: Effects of nonsteroidal antiinflammatory drugs on renal function focus on cyclooxygenase-2 selective inhibition. *Am J Med* Dec 13: 107: 65S-70S, 1999.
- Whelton A: Nephrotoxicity of nonsteroidal anti-inflammatory drugs: physiologic foundations and clinical implications. *Am J Med* 106 (5B): 13S-24S, 1999.
- Simon LS, Weaver SL, Graham DY y cols.: Antiinflammatory and upper gastrointestinal effects of celecoxib in rheumatoid arthritis: A randomized controlled trial. *JAMA* 282: 1921-8, 1999.
- Silverstein FE, Faich G, Goldstein JL y cols.: Gastrointestinal toxicity with celecoxib vs nonsteroidal antiinflammatory drugs for osteoarthritis and rheumatoid arthritis. The Class Study: A randomized controlled trial. *JAMA* 284: 1247-55, 2000.
- Bombardier C, Laine L, Reicin A y cols.: Comparison upper gastrointestinal toxicity of rofecoxib and naproxen in patients with rheumatoid arthritis. Vigor Study Group. *N Engl J Med* 343: 1520-8, 2000.
- Langman MJ, Jensen DM, Watson DJ y cols.: Adverse upper gastrointestinal effects of rofecoxib compared with NSAIDs. *JAMA* 282: 1929-33, 1999.
- Lipsky PE, Brooks P, Crofford LJ y cols.: Unresolved issues in the role of cyclooxygenase-2 in normal physiologic processes and disease. *Arch Intern Med* 160: 913-20, 2000.
- Khan KNM, Venturini CM, Bunch RT y cols.: Interspecies differences in renal localization of cyclooxygenase isoforms: implications in nonsteroidal antiinflammatory drug related nephrotoxicity. *Toxicol Pathol* 26: 612-620, 1998.
- Dinchuck JE, Car BD, Focht RJ y cols.: Renal abnormalities and an altered inflammatory response in mice lacking cyclooxygenase. *Nature* 378: 406-409, 1995.
- Morham SG, Laugenbach RL, Loftin CD y cols.: Prostaglandin synthase 2 gene disruption causes several renal pathology in the mouse. *Cell* 83: 473-482, 1995.
- Komhoff M, Wang JL, Cheng HF y cols.: Cyclooxygenase-2 selective inhibitors impair glomerulogenesis and renal cortical development. *Kidney Int* 57: 414-22, 2000.
- Harris RC: Cyclooxygenase-2 in the kidney. *J Am Soc Nephrol* 11: 2387-2394, 2000.
- Peracella MA, Eras J: Are selective Cox-2 inhibitors nephrotoxic? *Am J Kidney Dis* 35: 937-940, 2000.
- Swan SK, Rudy DW, Lancaster KC y cols.: Effect of cyclooxygenase-2 inhibition on renal function in elderly persons receiving a low salt diet. A randomized, controlled trial. *Ann Intern Med* 133: 1-9, 2000.
- Peracella MA, Tray K: Selective cyclooxygenase-2 inhibitors: A pattern of nephrotoxicity similar to traditional nonsteroidal antiinflammatory drugs. *Am J Med* 111: 64-67, 2001.
- Dun MJ: Are Cox-2 selective inhibitors nephrotoxic? *Am J Kidney disease* 35: 976-7, 2000.
- Whelton A, Maurath CJ, Verburg KM y cols.: Renal safety and tolerability of celecoxib, a novel cyclooxygenase-2 inhibitor. *Am J Therap* 7: 159-175, 2000.
- Zhao SZ, Reynolds MW, Lejkowith J, Whelton A, Arellano FM: A comparison of renal related adverse drugs reactions between rofecoxib and celecoxib, based on the World Health Organization/Uppsala Monitoring Centre safety database. *Clin Ther* 23 (9): 1478-1491, 2001.
- Clement D: Celecoxib: a review of its use in osteoarthritis, rheumatoid arthritis and acute pain. *Drugs* 59: 957-982, 2000.
- Rocha JL, Fernández-Alonso J: Acute tubulointerstitial nephritis associated with the selective Cox-2 enzyme inhibitor, rofecoxib. *Lancet* 357: 1946-1947, 2001.
- Alim N, Peterson L, Zimmerman SW, Updike S: Rofecoxib-induced acute interstitial nephritis. *Am J Kidney Dis* 41: 720-721, 2003.
- Henao J, Hisamuddin I, Nzerue CM y cols.: Celecoxib-induced acute interstitial nephritis. *An J Kidney Dis* 39: 1313-1317, 2002.
- Brewster VC, Perazella MA: Acute tubulointerstitial nephritis associated with celecoxib. *Nephrol Dial Transplant* 19: 1017-1018, 2004.
- Alper AB Jr, Meleg-Smith S, Krane NK: Nephrotic syndrome and interstitial nephritis associated with celecoxib. *Am J Kidney Dis* 40: 1086-90, 2002.
- Markowitz GS, Falkowitz DC, Isom R y cols.: Membranous glomerulopathy and acute interstitial nephritis following treatment with celecoxib. *Clin Nephrol* 59 (2): 137-42, 2003.
- Demke D, Zhaos SZ, Arellano FM: Interstitial nephritis associated with celecoxib. *Lancet* 358: 1726-1727, 2001.