

pacientes diabéticos con enfermedad renal crónica sin tratamiento sustitutivo: enseñanzas del estudio TREAT. *Nefrologia* 2010;30(1):15-20.

3. Phrommintikul A, Haas SJ, Elsik M, Krum H. Mortality and target haemoglobin concentrations in anaemic patients with chronic kidney disease treated with erythropoietin: a meta-analysis. *Lancet* 2007;369(9559):381-8.
4. Clement FM, Klarenbach S, Tonelli M, Johnson JA, Manns BJ. The impact of selecting a high hemoglobin target level on health-related quality of life for patients with chronic kidney disease: a systematic review and meta-analysis. *Arch Intern Med* 2009;169(12):1104-12.

F.J. García López

Unidad de Epidemiología Clínica.
Hospital Universitario Puerta de Hierro.
Majadahonda. Madrid.

Correspondencia:

Francisco Javier García López
Unidad de Epidemiología Clínica.
Hospital Universitario Puerta de Hierro.
Majadahonda. Madrid.
fjgarcia@medynet.com

Pulmonary toxicity associated with sirolimus following kidney transplantation: computed tomography findings

Nefrologia 2010;30(2):259-60

Dear Editor:

We read with great interest the letter by Calle et al.¹ describing the case of a patient who underwent a kidney transplant and developed a pneumonitis caused by sirolimus. They related that there are, until now, only seven cases reported of recovery from pneumonitis caused by sirolimus.

We would like to describe the case of a 27-year-old woman with a two-year history of haemodialysis for end-

stage renal disease underwent a haplo-identical, living kidney, donor transplantation. Following the procedure, she began immunosuppressive therapy with tacrolimus, mycophenolate mofetil, and steroid. Her renal function was stable and she was discharged with normal serum creatinine levels.

Two months after beginning immunosuppressive therapy she presented with diarrhoea of unknown aetiology. After recovery from the diarrhoea, the patient was discharged while using mycophenolate sodium and metronidazol. Six months later, she was admitted with another episode of diarrhoea and the tacrolimus was switched to sirolimus.

Ten months after initiation of the sirolimus treatment, the patient was admitted with fever, shortness of breath, and dehydration. Chest X-rays and high-resolution CT of the chest demonstrated bilateral areas of non-homogeneous air space consolidation, mainly in the left upper lobe and lower lobes (figure 1A). Bronchoalveolar lavage revealed hypercellularity with lymphocytosis, and the microbiological evaluation was negative for bacteria, fungi, and viruses. Serological tests for cytomegalovirus were negative. The patient began an empirical, anti-infection treatment with intravenous azithromycin and ciprofloxacin, with no response. The fever persisted with antibiotic treatment and sirolimus was thought to be the cause of the symptoms. When sirolimus was switched to azathioprine symptoms improved within 10 days, and were resolved in 30 days. On the follow-up chest X-ray and high-resolution CT, 30 days after sirolimus discontinuation, the parenchymal abnormalities had improved, with accentuated reduction of the air-space consolidation pattern. There were persisting residual areas of bilateral ground-glass opacities on the high-resolution CT (figure 1B).

Sirolimus (rapamycin) is a potent immunosuppressive drug that has been successfully used in solid organ

transplant recipients as an alternative to calcineurin inhibitor therapy^{2,4}. The most common side effects associated with this drug are dose-dependent hyperlipidemia, and thrombocytopenia. Unlike calcineurin inhibitors, sirolimus does not induce acute or chronic nephrotoxicity. However, in very rare cases, patients treated with sirolimus may exhibit severe pulmonary toxicity^{2,3}.

The symptoms of pulmonary toxicity related to sirolimus are generally non-specific, and may include a dry cough, dyspnea, fatigue, and fever, frequently leading to the initial diagnosis of pulmonary infection⁵. Some reports have described histopathological patterns as a

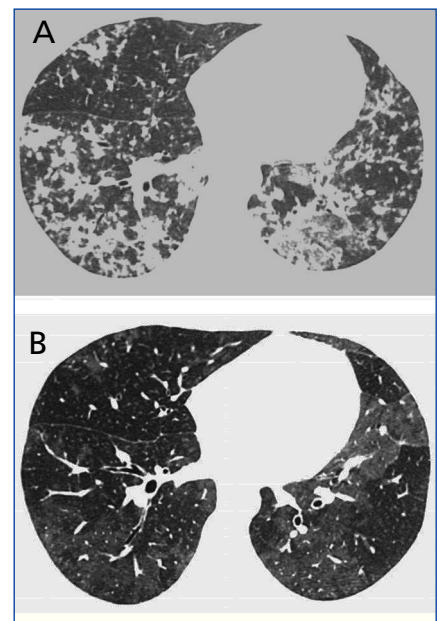


Figure 1. High-resolution CT at the level of the lower lobes (A) (obtained at the time of clinical presentation when respiratory symptoms were evident) demonstrates areas of non-homogeneous air space consolidation in the lower lobes, and mild ground-glass opacities. Follow-up scan (B), taken in the same plain as A, and 30 days after discontinuation of sirolimus, showed a reduction in the air-space consolidation pattern, with bilateral areas of residual ground-glass attenuation. The expiratory scans did not show air trapping.

result of sirolimus pulmonary toxicity, but these findings are usually non-specific, consisting of bronchiolitis obliterans with organizing pneumonia, interstitial pneumonitis, and non-necrotizing granulomas^{2,4}. For this reason, a lung biopsy is not essential, and the diagnosis of this condition must fulfil the following criteria: presence of lung disease on imaging tests, exclusion of pulmonary infection or other lung disease, and clinical improvement after drug withdrawal, independent of the pulmonary biopsy^{4,5}. All these criteria were fulfilled in the patient presented here, who showed significant imaging and clinical improvement after withdrawal of sirolimus.

Due to the increased use of sirolimus, radiologists interpreting imaging studies of transplant patients using this drug should be aware of the imaging features associated with this

potentially treatable complication. Although some previous authors reported the use of CT^{2,3,5}, to our knowledge, there are no reports illustrating and discussing the high-resolution CT findings of pulmonary toxicity due to sirolimus.

1. Calle L, Tejada C, Lancho C, Mazuecos A. Pneumonitis caused by sirolimus: improvement after switching to everolimus. *Nefrologia* 2009;29(5):490-1.
2. Adibelli Z, Dilek M, Kocak B, Tulek N, Uzun O, Akpolat T. An unusual presentation of sirolimus associated cough in a renal transplant recipient. *Transplant Proc* 2007;39(10):3463-4.
3. Champion L, Stern M, Israel-Biet D, et al. Brief communication: sirolimus-associated pneumonitis: 24 cases in renal transplant recipients. *Ann Intern Med* 2006;144(7):505-9.
4. Chhajer PN, Dickenmann M, Bubendorf L, Mayr M, Steiger J, Tamm M. Patterns of

pulmonary complications associated with sirolimus. *Respiration* 2006;73(3):367-74.

5. Haydar AA, Denton M, West A, Rees J, Goldsmith DJ. Sirolimus-induced pneumonitis: three cases and a review of the literature. *Am J Transplant* 2004;4(1):137-9.

T. Davaus Gasparetto, MD^{1,2}, E. Marchiori, MD, PhD¹, P. Menezes, MD³, G. Zanetti, MD²

¹ Department of Radiology. Fluminense Federal University. Niterói. Rio de Janeiro. Brazil.

² Department of Radiology. Federal University of Rio de Janeiro. Rio de Janeiro. Brazil.

³ Department of Nephrology. Fluminense Federal University. Niterói. Rio de Janeiro. Brazil.

Correspondence:

Edson Marchiori

Rua Thomaz Cameron, 438.

Valparaíso. CEP 25685.120.

Petrópolis. Rio de Janeiro. Brazil.

edmarchiori@gmail.com

B) COMUNICACIONES BREVES DE INVESTIGACIÓN BÁSICA O EXPERIENCIAS CLÍNICAS

Síndrome de Guillain-Barré en trasplante renal

Nefrologia 2010;30(2):260-1

Sr. Director:

El síndrome de Guillain-Barré (SGB) es la causa más frecuente de polineuropatía aguda en adultos. Se manifiesta por progresiva debilidad motora simétrica en miembros y arreflexia. Su complicación más grave es la insuficiencia respiratoria aguda, con una mortalidad del 15-30% si llega a precisar ventilación mecánica.

Puede asociarse con infección respiratoria o gastrointestinal (citomegalovirus [CMV], *Campylobacter yeyuni*) en dos tercios de los casos^{1,2}. Se ha descrito en trasplantes de médula ósea, aunque es muy raro en trasplantes de órganos sólidos³. También se ha asociado con neurotoxicidad por anticaleineurínicos⁴. Presentamos 2 casos de SGB en pacientes sometidos a trasplante renal.

El primer caso corresponde a una mujer sometida a un trasplante renal de 22 años de edad, con insuficiencia renal crónica (IRC) secundaria a vejiga neurogénica. Recibió esteroides, tacrolimus y micofenolato mofetil, así como tratamiento profiláctico frente a CMV con gammaglobulina hiperinmune (receptor IgG negativo/donante IgG positivo). La evolución de la función renal fue excelente. Cinco semanas después del trasplante renal desarrolló enfermedad por CMV (leucopenia grave, hipertransaminemia, gastritis, Ag P65 positivo.) Recibió ganciclovir intravenoso durante 15 días, y evolucionó satisfactoriamente. Reingresó 3 semanas después por debilidad progresiva y simétrica de los miembros inferiores, parestesias y disfagia, con desarrollo, en las horas siguientes, de insuficiencia respiratoria aguda que requirió ventilación mecánica.

El segundo caso es un hombre sometido a trasplante renal de 62 años de edad, con IRC no filiada. Fue tratado con este-

roides, tacrolimus y micofenolato mofetil. Presentó muy buena evolución de la función renal. A los 2,5 meses del trasplante ingresó por parálisis grave de los miembros inferiores que evolucionó rápidamente a tetraparesia. Se determinó Ag P65, que fue positivo, y fue tratado con ganciclovir i.v. durante 18 días. No requirió ventilación mecánica, pero sí un prolongado tratamiento rehabilitador.

En los 2 pacientes el líquido cefalorraquídeo (LCR) y el estudio electromiográfico fueron diagnósticos de SGB (polineuropatía sensitivo-motora desmielinizante; LCR con presión normal, elevación de proteínas y sin pleocitosis).

La primera paciente recibió 4 ciclos de plasmáferesis y 5 dosis de gammaglobulina hiperinmune (0,4 g/kg/día) y el segundo, 5 dosis de gammaglobulina hiperinmune (0,4 g/kg/día). La primera trasplantada mejoró de forma evidente, y fue extubada a los 7 días. Tras 8 años de seguimiento, permanece asintomáti-