

PATOGENIA, DIAGNOSTICO Y EPIDEMIOLOGIA DE LA POLIQUISTOSIS RENAL DEL ADULTO

The Pathogenesis of Polycystic Kidney Disease

J J Grantham

University of Kansas Medical Center. Kansas City Kansas, USA, 66160. Running Head: Polycystic Kidney Disease

Polycystic kidney disorders account for approximately 10 % of patients seeking treatment for end-stage kidney failure. These disorders are found throughout the world and in all races and ethnic groups. Autosomal dominant PKD is the most common monogenetic disorder that is potentially life-threatening.

Renal cysts can be found in a variety of clinical circumstances, but in general they fall into two categories: hereditary and acquired ¹. Figure 1 shows some of the major conditions associated with renal cysts. There are two inherited genotypes-autosomal dominant PKD, which affects adults primarily, and autosomal recessive PKD, a relatively rare condition that affects infants and small children. Acquired cysts are seen in individuals with end-stage renal disorders, and are recognized most commonly in dialysis patients. Renal cysts may also be acquired in potassium wasting states, after the administration of renal toxins, and as a secondary feature of several inherited metabolic or congenital disorders.

In autosomal dominant and recessive PKD the kidneys are massively enlarged. They are made up largely of sacs of fluid. The cysts are encased by a thin

and often transparent membrane. A water-filled balloon illustrates just what a cyst is—a sac of fluid—an extraordinarily simple biologic structure has an extraordinarily complex pathobiology.

The fluid within the cysts looks like urine. In a seminal study ², Gardner reported that some of the cysts maintained steep concentration gradients of Na, K and H⁺ between blood and cyst fluid. This simple observation established the fact that cysts are derived from renal tubules that have expanded to an extraordinary degree. Cysts are in fact giant nephrons that continue to function, albeit in a pathologic mode, throughout the lifetime of the patient ³.

The pathogenetic components of PKD are summarized in table I.

Table I. Central elements of renal cyst pathogenesis

- Expression of inherited genetic mutation.
- Abnormal proliferation of renal tubule epithelial cells.
- Abnormal accumulation of liquid within the cyst cavity.
- Abnormal synthesis and degradation of tubule basement membrane and interstitial matrix proteins.
- Interstitial inflammation and fibrosis.
- Destruction of renal function.

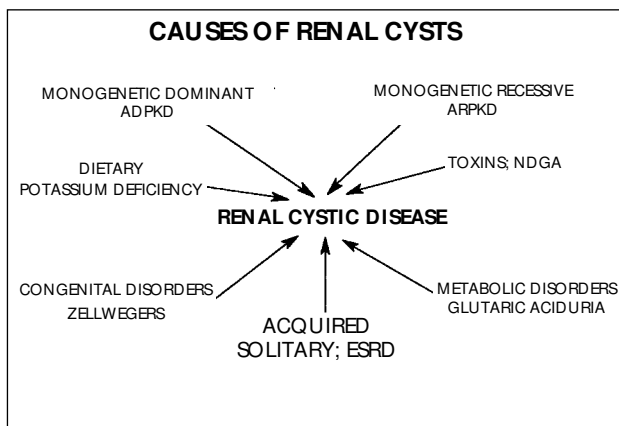


Fig. 1.—The causes of polycystic kidney disorders.

Expression of inherited genetic mutation

The cause of inherited polycystic kidney diseases is mutated DNA. In the autosomal type of PKD the gene penetrates completely in the clinical spectrum. The genetic material may be relatively unstable because the mutation rate is unusually high. There are at least two genotypes: PKD1 is on chromosome 16 and accounts for 85 % of the cases. PKD2 is on chromosome 4 and accounts for 15 %. These two genotypes are clinically indistinguishable. A European consortium has cloned the gene for PKD1 and has sequenced about one-third of the 14 kb transcript ⁴.

This is a very large gene with duplicated regions nearby. Several small deletions have been found in some of the families, but up to this point there is no sequence homology to other genes and proteins with known functions. The gene is expressed in kidney cyst epithelium and several organs. The weight of current evidence seems to favor a loss of function event, rather than a gain of function, but that is not certain.

Abnormal proliferation of renal tubule epithelial cells

All cysts simply have too many cells in the wall. The proliferation may even appear hyperplastic in some of the cysts. One may think of a cyst as a peculiar type of tumor, a neoplastic condition, not malignant of course, but a tumor none-the-less, in which the greater tumor bulk is comprised of liquid rather than cells.

Why do these cells divide endlessly? Calvet and colleagues at the University of Kansas⁵ suggest that the cyst cells behave as juvenile delinquents, in other words the cells appear to be trapped in a state of permanent immaturity and growth. The immature cells grow at a faster rate than normal and take on some aberrant functions.

Abnormal accumulation of liquid within the cyst cavity

The proliferating epithelial cells generate the expanding surface area of a cyst. Without the fluid, of course, the end result would be a tumor mass, considerably smaller than if the cavity was inflated with liquid. In an early hypothesis, the fluid was thought to derive from the glomerular filtrate because hyperplastic polyps blocked the outflow of urine in those segments of tubule in which the cysts formed. An exhaustive study of human polycystic kidneys failed to confirm the obstruction hypothesis; 73 % of the cysts had no connections to tubules at all⁶. In the remainder, at least one tubule connection could be found. Thus, most of the macroscopic cysts that we see in gross specimens of polycystic kidneys have become detached from the original tubule. Consequently, the only way fluid can get into these isolated cysts is by transepithelial secretion.

In contrast to normal tubular epithelium in which NaCl and water are absorbed, salt and water are secreted into the cyst lumen under the control of the adenylate cyclase signal transduction system. The motive force for this secretion is the sodium pump or

Na⁺, K, ATPase. Wilson and colleagues⁷ at Johns Hopkins Medical School have suggested that this pump may be mislocated on the apical surface of the cells. By contrast, others have found the functioning sodium pump was positioned along the basolateral membrane of cyst epithelial cells^{8,9}. Recent studies indicate that chloride, rather than sodium, may be primarily transported into the cysts cavities¹⁰. Moreover, the cystic fibrosis conductance regulator (CFTR) protein, the chloride channel that is defective in cystic fibrosis, has been localized to the apical membranes of cyst epithelial cells¹¹.

Fluid secretion in cysts may be viewed as a process in which adenylate cyclase agonists stimulate the formation of cyclic AMP, which in turn activates the apical chloride channels. Chloride enters the cells through a basolateral cotransport mechanism that utilizes the potential energy generated by the basolateral sodium pump. The chloride ion enters the lumen through the chloride channel and hyperpolarizes the transepithelial electrical potential difference. This, in turn, causes the passive movement of sodium into the lumen. The net addition of NaCl to the lumen causes the inflow of water by osmosis thereby completing the process of net fluid secretion.

Cystic fibrosis may be contrasted to polycystic kidney disease. In cystic fibrosis too little fluid is secreted; in PKD there is too much secreted fluid.

Abnormal synthesis and degradation of tubule basement membrane and interstitial matrix proteins

In human renal cysts there is pronounced duplication of tubule basement membrane material and a host of matrix proteins are expressed in increased amounts. These changes also occur in a rat model of autosomal dominant PKD^{11,12}. The alterations in extracellular matrix appear to be linked to the simplification of the cellular phenotype of cystic epithelium. This suggests that cell-matrix interactions are disturbed in polycystic kidney disease and may be the basis for the abnormal growth of the cysts.

Interstitial inflammation and fibrosis

Inflammatory cells, principally monocytes and lymphocytes, are commonly seen in the interstitium adjacent to the cysts. PKD patients, especially women, have a relatively high rate of urinary tract infection and pyelonephritis. But even in those with no history of infection, such as newborn infants, one can find monocytes in the interstitium adjacent to cysts. The role of interstitial monocytes in the pathogenesis

of PKD is a chapter that has just been opened, but one in which we can expect some exciting findings in the years ahead.

Destruction of renal function

The interstitial inflammation ultimately leads to fibrosis and this appears to be connected to the observation that renal function is severely compromised in about one-half of those who have the PKD1 gene. A recent study shows that methylprednisolone, an anti-inflammatory and antifibrotic agent, decreased the size of the kidneys relative to body weight, and decreased the amount of inflammation and fibrosis in rats and mice with slowly progressive hereditary types of polycystic kidney disease¹³. Renal function was also better in those animals that had been given methylprednisolone at a dose of 1 mg/kg/d. There was better preservation of the noncystic tubules in the steroid-treated animals, and this probably accounts for the better function in these animals. Methylprednisolone is a not cure for PKD in a definitive sense, but these experiments indicate that the collateral damage caused by cysts can possibly be controlled pharmacologically.

In summary, the pathogenesis of PKD is understood well enough that it should be possible to correlate the information from the genetic discoveries to the aberrant cell be possible to physiology in the not too distant future.

Acknowledgements

I wish to thank Dr. Lawrence Sullivan, Dr. Roberto Mangoo-Karim, Darren Wallace, Dr. James Calvet, Dr. Carolyn Rankin, Dr. Vincent Gattone and Dr. Benjamin Cowley for their essential contributions to this body of work.

References

1. Gabow PA: Autosomal dominant polycystic kidney disease. *New Eng JMed* 329:332-342, 1993.
2. Gardner Jr KD: Composition of fluid in twelve cysts of a polycystic kidney. *N Eng JMed* 281:985-988, 1969.
3. Grantham JJ: Polycystic kidney disease: A predominance of giant nephrons. *Am JPhysiol* 23:526-529, 1983.
4. European polycystic kidney disease consortium: The polycystic kidney disease 1 gene encodes a 14 kb transcript and lies within a duplicated region on chromosome 16. *Cell* 77:881-894, 1994.
5. Rankin CA, Grantham JJ, Calvet JP: C-fos expression is hypersensitive to serum-stimulation in cultured cystic kidney cells from the C57Bl/6J-cpk mouse. *JCell Physiol* 152:578-586, 1992.
6. Grantham JJ, Geiser JL, Evan AP: Cyst formation and growth in autosomal dominant polycystic kidney disease. *Kidney Int* 31:1145-1152, 1987.
7. Wilson PD, Sherwood AC, Palla K, Du J, Watson R, Norman JT: Reversed polarity of Na⁺, K, ATPase: Mislocation to apical plasma membranes in polycystic kidney disease epithelia. *Am JPhysiol* 260:F420-F430, 1991.
8. Carone FA, Nakamura S, Caputo M, Bacallao R, Nelson WJ, Kanwar YS: Cell polarity in human renal cystic disease. *Lab Invest* (in press).
9. Grantham JJ, Ye M, Gattone VH, Sullivan LP: In vitro fluid secretion by epithelium from polycystic kidneys. *JClin Investigation* (in press).
10. Grantham JJ: Fluid secretion, cellular proliferation, and the pathogenesis of renal epithelial cysts. *JAm Soc Neph* 3:1843-1857, 1993.
11. Ross KE, Ye M, Grantham JJ, Caplan MJ: Immunolocalization of ion transport proteins in human polycystic kidney epithelium. *JAm Soc Nephrol* 5:634, 1994.
12. Cowley BD Jr, Gudapaty S, Kraybill AL, Barash BD, Harding MA, Calvet JP, Gattone VH II: Autosomal-dominant polycystic kidney disease in the rat. *Kid Intern* 43:522-534, 1993.
13. Schafer K, Gretz N, Bader M, Oberdaumer I, Eckardt K-U, Kriz W, Bachman S: Characterization of the Han:SPRD rat model for hereditary polycystic kidney disease. *Kid Intern* 46:134-152, 1994.