

## ORIGINALES

# *Minimal change disease and idiopathic membranous glomerulonephritis in adults. A quantitative study*

**M. Danilewicz and M. Wagrowska-Danilewicz**

Department of Pathology (Morphometry Division), Medical University of Łódź, Poland.

### SUMMARY

*Fifteen renal biopsy specimens from adult patients with minimal change disease (MCD) and twelve with early stages of idiopathic membranous glomerulonephritis (MGN) for whom light, electron and immunofluorescence microscopy and full clinical data were available were examined quantitatively. As controls 6 biopsy and 9 autopsy specimens of the normal kidneys were used. Morphometric investigations were performed by means of a computer image analysis system to evaluate whether morphometric analysis is helpful in differential diagnosis of MCD and early MGN in adults and to study whether changes in quantitatively analyzed glomeruli correlated with the clinical data. The mean values of total glomerular area, total glomerular cells per total glomerular area, total glomerular cells per unit of glomerular area, mesangium (% of total glomerular area) and relative interstitial volume in both MCD and MGN were increased in comparison with normal controls, most of them significantly. In MGN the mean values of total glomerular area, total glomerular cells per total glomerular area and relative interstitial volume were significantly greater than those of the minimal change group. In MGN but not in MCD there was a significant positive correlation between interstitial volume and serum creatinine. Correlations between proteinuria and total glomerular cells per unit of glomerular area, were weak and not significant in both MCD and MGN groups.*

*Although our results give clear evidence that quantitative analysis can not be used instead of light microscopy, electron microscopy and immunohistochemistry, it may be helpful in differential diagnosis of MCD and early stages of MGN in adults, particularly when electron microscopy is not available. In particular, precise evaluation of the interstitial lesions seems to be extremely useful in these cases.*

**Key words:** *Minimal change disease. Membranous glomerulonephritis. Morphometry.*

Recibido: 28-X-97.

En versión definitiva: 12-I-98.

Aceptado: 17-I-98.

Correspondencia: Dr. Marian Danilewicz M.D., Ph.D.  
ul. Zamenhofa 5 m. 4. 90-431 Łódź, Poland.

**ENFERMEDAD DE CAMBIOS MÍNIMOS Y GLOMERULONEFRITIS  
MEMBRANOSA IDIOPÁTICA EN ADULTOS. UN ESTUDIO CUANTITATIVO**

**RESUMEN**

*Se estudiaron cuantitativamente 15 biopsias renales de enfermos adultos con enfermedad de cambios mínimos (ECM) y 12 casos de estadios iniciales de nefropatía membranosa idiopática (NMI) de los que se disponía de estudios de microscopía óptica, electrónica, inmunofluorescencia e historia clínica detallada. Como control se emplearon seis biopsias y nueve muestras de autopsias procedentes de riñones normales. Los estudios morfométricos se llevaron a cabo mediante un sistema de análisis de imagen computarizada con el fin de valorar si el análisis morfométrico puede resultar de utilidad en el diagnóstico morfológico diferencial de ECM y estadios iniciales de NMI en adultos, así como para valorar si las alteraciones en los glomérulos analizados cuantitativamente se pueden correlacionar con los datos clínicos. Las comparaciones morfométricas de los glomérulos y del tejido renal intersticial en enfermos con ECM, NMI y controles, mostraron que los valores medios del área glomerular total, células glomerulares totales por área glomerular total, células glomerulares totales por unidades de área glomerular, mesangio (porcentaje del área glomerular total) y volumen intersticial relativo, estaban aumentadas tanto en enfermos con ECM, como con NMI, en relación con los controles normales, la mayoría de ellos de forma significativa. Además, en la NMI, pero no en la ECM, se apreció una correlación positiva significativa entre el volumen intersticial y la creatinina sérica. Las correlaciones entre la proteinuria y las células glomerulares totales por unidad de área glomerular fueron muy pequeñas y no significativas, tanto para las ECM como para las NMI.*

*Aunque nuestros resultados ponen de manifiesto que el análisis cuantitativo no puede utilizarse en lugar de la microscopía óptica electrónica o la inmunohistoquímica, es de resaltar la existencia de diferencias claras entre ECM y los primeros estadios de NMI. Es de destacar la existencia de diferencias claras en cuanto a las lesiones intersticiales en ambas entidades.*

**Palabras clave:** *Enfermedad de cambios mínimos. Nefropatía membranosa. Morfometría.*

**INTRODUCTION**

Although minimal change disease (MCD) is primarily a disease of childhood, this glomerulopathy accounts for around 20-25% of adult nephrotics with well known progressive decline in incidence with age<sup>1</sup>. Moreover, adults show an increased incidence of atypical clinical features such as hypertension, renal function impairment, non-selective proteinuria and microscopic hematuria<sup>2,3</sup>. These cases of MCD (fig. 1) may be clinically similar to those with membranous glomerulonephritis (MGN) (fig. 2). By light microscopy the characteristic finding in MGN is thickening of the capillary walls in the glomeruli<sup>4</sup>. However, in the early stages this thickening is slight, and distinction from MCD may be difficult<sup>5</sup>.

In view of the above, this paper was undertaken to evaluate whether morphometric analysis could re-

veal differences between MCD and early cases of MGN in adults as well as to study whether changes in quantitatively analyzed glomeruli could correlate with the clinical data.

**MATERIAL AND METHODS****Patients**

Fifteen adult patients with MCD and twelve with idiopathic MGN were examined by percutaneous renal biopsy. In each case morphological diagnosis of these glomerulopathies was established independently by two experienced nephropathologists and based on light microscopy, immunofluorescence and electron microscopy. For the present study only relatively early cases of MGN (stage I and stage I/II

according to the scheme proposed by Churg's group<sup>5</sup>) were selected. As a control 6 biopsy and 9 autopsy specimens of the kidney were used. All biopsy specimens consisted of the kidneys removed because of trauma. The causes of death of the 9 persons from whom tissue samples had been taken post mortem were as follows:

- cardiac infarct: 2
- cerebral lesions: 4
- ventricular fibrillation: 2
- pneumonia: 1

Tissue specimens obtained from autopsy patients were applied to the fixation medium (10% buffered formalin) within 15 hours post mortem (the biopsy specimens were fixed in the same manner). None of the persons from whom renal tissue originated were known to have had previous or actual renal disease. Before the quantitative examination was carried out, all control specimens were histologically examined by an experienced nephropathologist and found to be normal renal tissue.

### Light microscopy

Tissue specimens were embedded in paraffin, sections cut precisely at 4  $\mu$ , and stained by hematoxylin and eosin, periodic acid-Schiff (PAS)-alcian blue, trichrome light green (Masson), and by silver impregnation (Jones). Thickness of each section was controlled according to the method described by Weibel<sup>6</sup>. For this study biopsies containing less than 10 nonsclerotic glomeruli were neglected.

### Immunofluorescence microscopy

Tissue was snap frozen, sectioned at 5  $\mu$  and fixed in 95% alcohol for 10 min. Sections incubated with FITC-antisera (Hoechst) to human IgG, IgA, IgM and complement (C3) were viewed on Carl Zeiss (Jena) NU-2 microscope, using an HBO 200 lamp and proper filters.

### Electron microscopy

Tissue was fixed in glutaraldehyde, post-fixed in 1% osmium tetroxide, embedded in epon and sectioned on a LKB ultratome. Sections were stained by lead citrate and uranyl acetate, and viewed in a JEM 100B electron microscope.

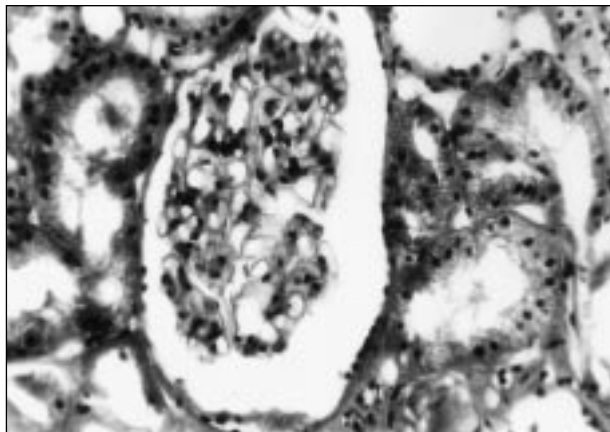


Fig. 1.—Minimal change disease. Thickness of the glomerular capillary walls within normal limits. Hematoxylin and eosin, magn. 400x.

### Morphometry

Only non-sclerotic glomeruli were examined. Histological morphometry was performed by means of image analysis system consisting of a Pentium IBM-compatible computer equipped with an optical mouse, AVer 2000 card (frame grabber, true-color, real-time), produced by ADDA Technologies (Taiwan), and color TV camera Panasonic (Japan), linked to a microscope Jenaval-Carl Zeiss (Germany). This system was programmed (program MultiScan, produced by CSS-Poland) to calculate:

- the surface area of a structure whose perimeter was traced
- the number of objects (automatic function with manual correction)
- the surface area of a structure using stereological net (with regulated number of points).

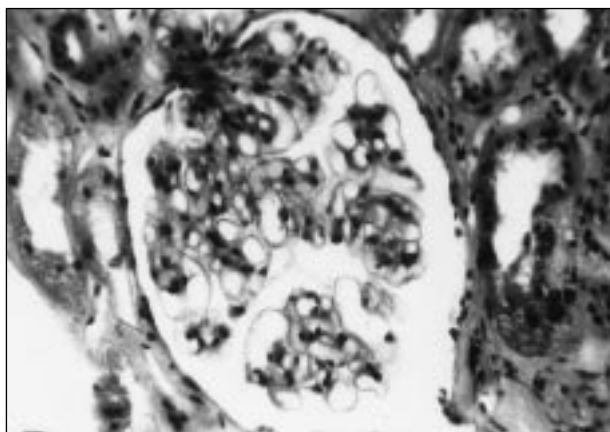


Fig. 2.—Membranous glomerulonephritis stage I/II. Thickness of the glomerular capillary walls seemingly within normal limits. Hematoxylin and eosin, magn. 400x.

All glomeruli in PAS-alcian blue and hematoxylin-eosin stained sections, except those that were sclerotic or evidently tangentially cut were measured. As a tangentially section was defined one in which the apparent diameter was < 50% of the maximum diameter. The exclusion of tangentially cut glomeruli reduces the yield for analysis by < 15%<sup>7</sup>. The coloured microscopic images were saved serially in the memory of a computer, and then quantitative examinations had been carried out. The quantitative examination included the following glomerular parameters:

- total glomerular nuclei per total glomerular area: mesangial, endothelial and visceral epithelial nuclei (these objects were automatically counted and followed out with manual correction, as needed)
- total glomerular nuclei per 1000 sq.  $\mu$  of total glomerular area
- mesangial area per cent of total area. This parameter was measured using point counting method which is an adaptation of the principles of Weibel<sup>6</sup>. The point spacing being 16  $\mu$ . Total number of the points of a net was 169, and total area was 36864 sq.  $\mu$ . The percentage of me-

sangial area was an expression of the number of points overlying glomerular mesangium as a percentage of the total points counted.

The same method was used to estimate interstitial volume in sections stained with Masson trichrome. Under the net described above, seven fields of the renal cortex were investigated. Glomeruli and large blood vessels were neglected. The percentage interstitial volume was an expression of the number of points overlying renal cortical interstitium as a percentage of the total points counted.

**Statistical methods**

Differences between groups were tested using One-Way ANOVA preceded by evaluation of normality and Levene's test. The Mann-Whitney U test was used where appropriate. The clinico-morphological correlations were based on detailed case sheet data analysis with particular reference to serum creatinine and proteinuria. Correlation coefficients were calculated using Spearman's method. Results were deemed statistically significant if P < 0.05.

**Table I.** Clinical findings at the time of biopsy in cases with MCD and MGN.

Number of cases	Sex M : F	Microhematuria	Gross hematuria	Proteinuria			Nephrotic syndrome	Renal function impairment <sup>1</sup>	Hypertension (>90/160)
				< 1 g/24 h	1-2 g/24 h	2-3 g/24 h			
MCD (n = 15)	11 : 4	2	-	-	-	-	15	-	3
MGN (n = 12)	7 : 5	4	5	2	2	3	5	2	5

Values in the table are number of cases.  
<sup>1</sup> Serum creatinine > 1.5 mg%.

**Table II.** A morphometric comparison of glomeruli and renal interstitial tissue in cases with MCD, MGN and controls.

	Controls (n = 15)	MCD (n = 15)	MGN (n = 12)	P value
Total glomerular area (sq. $\mu$ )	22196.2 $\pm$ 3180.9	23734.5 $\pm$ 3027.4	26716.2 $\pm$ 2234.6	<sup>1</sup> P - NS <sup>2</sup> P < 0.001 <sup>3</sup> P < 0.01
Total glomerular cells per toatall glomerular area	102.9 $\pm$ 18.1	114.3 $\pm$ 19.7	134.4 $\pm$ 14.7	<sup>1</sup> P - NS <sup>2</sup> P < 0.001 <sup>3</sup> P < 0.01
Total glomerular cells/1000 sq. $\mu$ of total glomerular area	4.6 $\pm$ 0.5	4.8 $\pm$ 0.3	5.1 $\pm$ 0.6	<sup>1</sup> P - NS <sup>2</sup> P < 0.05 <sup>3</sup> P - NS
Mesangium (% of total glomerular area)	8.6 $\pm$ 1.2	9.9 $\pm$ 1.7	9.7 $\pm$ 1.6	<sup>1</sup> P < 0.02 <sup>2</sup> P < 0.05 <sup>3</sup> P - NS
Relative interstitial volume (V%)	11.1 $\pm$ 1.2	12.1 $\pm$ 1.7	18.2 $\pm$ 3.6	<sup>1</sup> P - NS <sup>2</sup> P < 0.005 <sup>3</sup> P < 0.001

All values are expressed as mean  $\pm$  standard deviation.  
<sup>1</sup> - MCD versus controls, <sup>2</sup> - MGN versus controls, <sup>3</sup> - MCD versus MGN.

**RESULTS**

Clinical features of the patients with MCD and MGN at the time of biopsy are given in table I. Most of our MCD and MGN patients were young adults and the mean age was respectively 32.2 and 31.5 years. Male predominance was conspicuous. At the time of renal biopsy all patients in both MCD and MGN groups showed nephrotic syndrome or proteinuria. Two MCD patients had microhematuria and another 3 elevated blood pressure. In MGN group microhematuria was noted in 4 patients, gross hematuria in 5, renal function impairment (serum creatinine greater than 1.5 mg/100 ml) in 2. Five MGN patients had elevated blood pressure.

The morphometric comparisons of the glomeruli and renal interstitial tissue in patients with MCD, MGN and controls appear from table II. The mean values of total glomerular area, total glomerular cells per total glomerular area, total glomerular cells per unit of glomerular area, mesangium (% of total glomerular area) and relative interstitial volume were in both MCD and MGN patients increased in comparison with normal controls, in MGN group all of them significantly. In MCD patients only mesangial widening has reached statistical significance. Furthermore, in MGN the mean values of total glomerular area, total glomerular cells per total glomerular area and relative interstitial volume were significantly greater than those of the minimal lesion group.

In MCD group the relationship between interstitial volume and serum creatinine as well as between total glomerular cells per unit of glomerular area and proteinuria were weak and not significant ( $P > 0.05$ ). In MGN there was significant positive correlation between interstitial volume and serum creatinine ( $r = 0.65, P < 0.02$ ) (fig. 3). Although in this group the re-

lationship between total glomerular cells per unit of glomerular area and proteinuria tended to be positive, it has not reach statistical significance ( $r = 0.50, P-NS$ ).

**DISCUSSION**

As against children, there are very few reported studies on adult MCD<sup>1,8,9</sup>. Although, as was mentioned in introduction, distinction early cases of MGN from MCD may be difficult by light microscopy, to our knowledge, none date have documented morphometric comparison of the glomerular parameters in these glomerulopathies in adults.

Our morphometric investigations revealed, that in MGN the glomerular area was significantly greater than in MCD patients and in controls. These observations agree with those of Rosen et al.<sup>4</sup> and Gartner et al.<sup>10</sup>, who showed that the kidney with MGN is characterized by having the glomeruli usually moderately enlarged. The mechanism of the development of glomerular enlargement is poorly understood. The investigators suggested that true loss of nephrons, not simple hyperfiltration or increased intraglomerular pressure, is the major cause of this process<sup>11,12</sup>.

Although it has been widely believed that both MCD and MGN are «nonproliferative» glomerular disease<sup>4,13-15</sup>, the present study showed that in MGN total glomerular cells per total glomerular area as well as total glomerular cells/100 sq.µ of total glomerular area were increased (the first parameter significantly) in comparison with MCD. These observations correspond with the findings of Wehner<sup>16</sup> and Gartner et al.<sup>10</sup> and support the point of view that MGN is a proliferative glomerular disease, even if the proliferation is small and can easily be overlooked. Moreover, while the mesangial areas are known to be usually unaffected in both MCD and MGN<sup>4,17,18</sup>, we found in agreement with the other authors<sup>10,16,19,20</sup> that mesangial areas in adult patients with these glomerulopathies were significantly larger than in the normal kidneys. Interestingly, differences in mesangial areas between MCD and MGN groups were small and not significant.

Moreover, our study showed that in patients with MGN relative interstitial volume was significantly increased in comparison with MCD and control group. These observations correspond with the findings of Riemenschneider et al.<sup>21</sup>. It is noteworthy, that in the paper of Riemenschneider et al., mean value of the relative interstitial volume was in MGN higher than established by us, however, for the present study we have selected only relatively early cases of this glomerulopathy. It is important to note that in MCD pa-

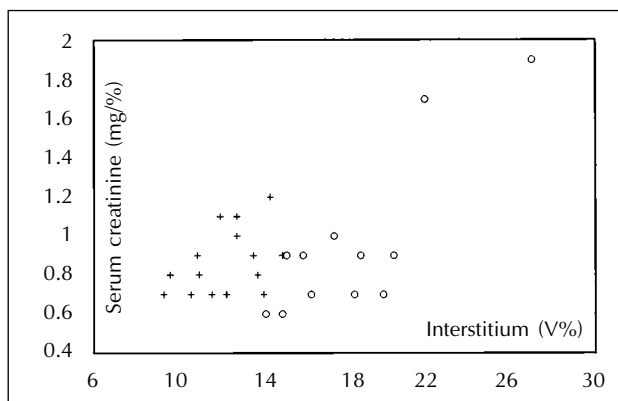


Fig. 3.—Correlation between serum creatinine and relative interstitial volume. MCD [+]:  $n = 15, r = 0.41, P - NS$ ; MGN [o]  $n = 12, r = 0.67, P < 0.02$ .

tients and controls mean values of relative interstitial volume were similar. Unfortunately, the cause of interstitial increase is not clear<sup>22-24</sup>. Bohle et al.<sup>22</sup> have postulated that the interstitial changes may cause the functional deterioration in glomerular filtration by increasing resistance in the postglomerular capillary network. The passage of basement membrane material from the glomerular capillaries into primary urine may play a critical role in this process, since this material can be reabsorbed by the tubules and is probably presented as an autoantigen to intraepithelial T lymphocytes. The presentation of these autoantigens leads in genetically predisposed individuals to an autoimmune response with a consequent increased production of extracellular matrix by fibroblasts/fibrocytes.

Irrrespective of the nature of interstitial fibrosis our clinico-morphologic correlations confirmed the observations of Riemenschneider et al.<sup>21</sup> and Lee et al.<sup>20</sup>, who found that in MGN significant positive correlation existed between width of the cortical interstitium and serum creatinine level. These observations support the opinions of a number of investigators<sup>21,25-27</sup> who have suggested that interstitial fibrosis in MGN is an accurate morphological parameter for predicting the subsequent course of the disease. Furthermore, we were not puzzled by the fact that in MCD patients this correlation was weak and not significant, because both interstitial fibrosis and serum creatinine in this group did not exceed normal values. It is also worth pointing out that in both MCD and MGN groups the relationship between total glomerular cells per unit of glomerular area and proteinuria tended to be positive, but they have not reach statistical significance.

Finally, although our results give evidence that quantitative analysis cannot be used instead of light microscopy, electron microscopy and immunohistochemistry, it is noteworthy that quantitative differences between MCD and early stages of MGN are clear. Especially, doubtless are differences of the interstitial lesions in these cases.

## BIBLIOGRAFIA

- Allen MJ, Thomas AC, Eastwood JB: Minimal change glomerulonephritis in the elderly-the role of renal biopsy. *Clin Nephrol* 28: 99-101, 1987.
- Cameron JS: The nephrotic syndrome in adults with minimal change glomerular lesions. *Quart J Med* 43: 461-488, 1974.
- Nolasco F: Adult-onset minimal change nephrotic syndrome: A long term follow-up. *Kidney Int* 29: 1215-1223, 1986.
- Rosen S, Tornroth T, Bernard BD: Membranous glomerulonephritis. In: Tisher CC, Brenner BM: *Renal Pathology*, vol. 1. JB Lippincott Company, 196-227, Philadelphia, 1989.
- Churg J, Bernstein J, Glasscock RJ (eds): *Renal disease: Classification and atlas of glomerular diseases*. Igaku-Shoin 45-49, New York, Tokyo, 1995.
- Weibel ER: *Stereological Methods*. Vol. 1. Practical methods for biological morphometry. Academic Press, 100-161, London, New York, Toronto, Sydney, San Francisco, 1979.
- Yoshiara S, White RHR, Raafat F, Smith NC, Shah KJ: Glomerular morphometry in reflux nephropathy: functional and radiological correlations. *Pediatr Nephrol* 7: 15-22, 1993.
- Wehner H, Oswald A: Vergleichende histometrische Untersuchungen bei der minimal proliferierenden intercapillaren Glomerulonephritis mit (minimal changes) und ohne nephrotischem Syndrom. *Klin Wschr* 56: 1155-1161, 1978.
- Danilewicz M, Wagrowska-Danilewicz M: Idiopathic focal segmental glomerulosclerosis in adults: a quantitative study. *Med Sci Monit* 2: 447-452, 1996.
- Gartner HV, Fischbach H, Wehner H, Bohle A, Edel HH, Kluthe R, Scheler F, Schmulling RM: Comparison of clinical and morphological features of peri- (epi- extra) membranous glomerulonephritis. *Nephron* 13: 288-301, 1974.
- Fogo A, Ichikawa I: Evidence of central role of glomerular growth promoters in the development of sclerosis. *Semin Nephrol* 9: 329-342, 1989.
- Yoshida Y, Fogo A, Ichikawa I: Glomerular hemodynamic changes vs hypertrophy in experimental glomerular sclerosis. *Kidney Int* 35: 654-660, 1989.
- Churg J: Pathology of glomerulonephritis. *Bull New York Acad Med* 46: 761-768, 1970.
- Habib R: Classification anatomique des nephropathies glomerulaires. *Pad Fortbildungskurse* 28: 3-47, 1970.
- Rosen S: Membranous glomerulonephritis: Current status. *Hum Pathol* 2: 209-231, 1971.
- Wehner H: *Quantitative Patomorphologie des Glomerulum der menschlichen Niere*. Gustav Fischer Verlag, Stuttgart, 1974.
- Pollak VE, Rosen S, Pirani CL, Muehrcke RC, Kark RM: Natural history of lipoid nephrosis and of membranous glomerulonephritis. *Ann Intern Med* 69: 1171-1196, 1968.
- Shemesh O, Ross JC, Deen W, Grant GW, Myers BD: Nature of the glomerular capillary injury in humans membranous glomerulopathy. *J Clin Invest* 77: 868-877, 1986.
- Ludwigsen E, Sorensen H, Olsen S: A quantitative study of glomeruli in idiopathic nephrosis with minimal or no glomerular lesions. *Acta Path Microbiol Scand Section A* 85: 911-916, 1977.
- Lee HS, Koh HI: Nature of progressive glomerulosclerosis in human membranous nephropathy. *Clin Nephrol* 39: 7-16, 1993.
- Riemenschneider T, Mackensen-Haen S, Christ H, Eiselle R, Bohle A: Correlation between endogenous creatinine clearance and relative interstitial volume of the renal cortex in patients with diffuse membranous glomerulonephritis having a normal serum creatinine concentration. *Lab Invest* 43: 145-149, 1980.
- Bohel A, Wehrman M, Mackensen-Haen S, von Gise H, Mickeler E, Xsiao TC, Muller C, Muller GA: Pathogenesis of chronic renal failure in primary glomerulopathies. *Nephrol Dial Transplant Suppl* 3: 4-12, 1994.
- Couser WG, Johnson RJ: Mechanisms of progressive renal disease in glomerulonephritis. *Am J Kidney Dis* 23: 193-198, 1994.
- Ong ACM, Fine LG: Tubular-derived growth factors and cytokines in the pathogenesis of tubulointerstitial fibrosis: Implications for human renal disease progression. *Am J Kidney Dis* 23: 205-209, 1994.
- Ponticelli C: Prognosis and treatment of membranous nephropathy. *Kidney Int* 29: 927-940, 1986.
- Ramzy MH, Cameron JS, Turner DE, Neild GH, Ogg CS, Hicks J: The long-term outcome of idiopathic membranous nephropathy. *Clin Nephrol* 16: 13-19, 1981.
- Wehrmann M, Bohle A, Bogenschutz O, Eissele R, Freislederer A, Ohlschlegel C, Schumm G, Batz C, Gartner HV: Long-term prognosis of chronic idiopathic membranous glomerulonephritis. An analysis of 334 cases with particular regard to tubulo-interstitial changes. *Clin Nephrol* 31: 67-76, 1989.