

Renal infarction and acute renal failure due to cocaine use

K. Furaz, C. Bernis Carro, A. Cirugeda García, A. Pérez de José and J. A. Sánchez Tomero

Servicio de Nefrología. Hospital Universitario de La Princesa. Madrid.

Nefrología 2008; 28 (3) 347-349

SUMMARY

We describe the case of a 36 year old man, habitual consumer of cocaine, who after the inhaled cocaine consumption develops acute renal failure secondary to massive left and segmental right renal infarction. Although the most frequent complications associated to cocaine consumption are of cardiovascular and neurological nature, the kidney can be frequently affected.

Key words: Cocaine. Renal infarction. Cocaine intoxication.

RESUMEN

Describimos el caso de un varón de 36 años, consumidor habitual de cocaína, que desarrolla un cuadro de insuficiencia renal aguda, secundario a infarto isquémico masivo en riñón izquierdo y segmentario en el riñón derecho. Las complicaciones más frecuentemente asociadas al uso de cocaína son de índole cardiovascular y neurológica, sin embargo, la afectación renal es frecuente.

Palabras clave: Cocaína. Infarto renal. Intoxicación por cocaína.

INTRODUCTION

Cocaine has been associated to multiple complications, the most common of which are cardiovascular and neurological. Pulmonary, ocular, intestinal, haematological, and urogenital complications have also been reported.¹ The most common renal complications are secondary to rhabdomyolysis² or HBP difficult to control with drugs.³⁻⁵ Acute renal failure, interstitial nephritis, anti-MBG glomerulonephritis, thrombotic microangiopathy,⁶ or renal infarction⁷⁻¹¹ less frequently occur.

CASE REPORT

A 36-year old male attended the emergency room for pain in the flank and left lumbar fossa. The patient reported a history of bilateral saphenectomy for varicose veins at the age of 32 and smoking (20 cigarettes daily) and habitual cocaine use (the last dose had been taken on the night before admission). Physical examination revealed high anxiety, sweating, skin

pallor and dry mucosal membranes, dyspnoea, tachypnoea, rhythmic and regular heart sounds, tachycardia at 110 beats per minute, and no murmurs. Pulmonary auscultation showed preserved vesicular murmur with no added sounds. The abdomen was soft and amenable to pressure, with left lumbar pain and negative renal fist percussion on both sides. BP: 165/110 mmHg, and temperature: 37°C.

The following findings were made on admission: Laboratory tests: Creatinine, 2.1 mg/dL; sodium, 142 mEq/L; potassium, 4.4 mEq/L; CK, 66 U/L; LDH, 4371 U/L; total bilirubin, 1.5 mg/dL; GOT, 143 U/L; GPT, 148 U/L; haemoglobin, 17.2 g/dL haematocrit, 49.3%; platelets, 272,000/mm³; white blood cells, 24,040/mm³ (94% segmented). Urine analysis: Protein > 400 mg/dL. Red blood cells: > 300/L. No other changes. Urinary sediment: Abundant white blood cells and red blood cells, a moderate number of granular hyaline casts. Urine chemistry: Urea, 759 mg/dL; creatinine, 159 mg/dL; Na, 82 mmol/L; potassium, 99 mmol/L. Chest X-rays showed no changes. An electrocardiogram revealed sinus rhythm at 100 beats per minute, QRS axis at 60° with no repolarisation disorders. Abdominal and renal ultrasonography: Both kidneys were of normal size, with good corticomedullary differentiation and no dilation of the collecting system. A 14-mm right cortical renal cyst was seen. The bladder could not be assessed due to gas interposition. A hyperechogenic, well defined lesion 1.5 cm in diameter, consistent with a hepatic angioma, was seen in the liver.

SUPPLEMENTAL TESTS

Cocaine and opiates were found in urine (opiates had been administered at the emergency room for severe pain). 24-hour urine: Protein, 4 g. Creatinine clearance, 77 mL/min. Immunological study (ANA, ANTI DNA, ENA, ANCA) was negative. Serological tests for HBV, HCV, and HIV were negative.

IMAGING TESTS

An abdominal CT scan with oral and intravenous contrast showed no changes in liver, spleen, pancreas, gallbladder, adrenals, bowel, and urinary bladder. Almost the whole left kidney was hypodense, with some parenchymal area enhanced as compared to spared parenchyma, showing no uptake in the

Correspondencia: José A. Sánchez Tomero
jsanchez.hlpr@salud.madrid.org

case reports

late phase. The left kidney showed triangular hypodense areas. These findings were considered to be consistent with renal infarctions.

Selective arteriography with contrast showed multiple filling defects in the left renal artery due to thrombosis. Right renal artery was patent, with minimum peripheral defects.

COURSE

Based on diagnosis of acute renal failure secondary to renal infarction, anticoagulant therapy was started consisting of heparin sodium and subsequently acenocoumarol. Kidney function showed little improvement despite an increased urine output. Creatinine levels remained stable at approximately 2 mg/dL. Abdominal pain disappeared. During his hospital stay, the patient experienced a self-limiting episode of generalised weakness, paresis in the left upper limb, and sensorial impairment. A CT scan of the head showed no ischaemic foci. Patient was discharged on anticoagulation with dicoumarin drugs. He returned at one month to the outpatient clinic with no symptoms and BP values of 120/80 mm Hg, but a persistent kidney function impairment, with creatinine levels of 2 mg/dL, creatinine clearance of 71 mL/min, a 24-hour urine output of 2000 mL, and proteinuria of 402 mg/24 hours. Anticoagulant therapy was maintained for 6 months.

DISCUSSION

The Spanish national drug plan (March 2007 report) shows that 7% of the Spanish population aged 15-65 years have used cocaine at least once during their lives. Cocaine is the most commonly used drug after cannabis. At Hospital Clinic in Barcelona, cocaine use was the second leading cause of emergencies from abuse drugs during 2002.² In the United States, cocaine use causes annual hospitalisation costs of 80 million dollars.¹² Cocaine-induced renal infarction has been associated to cocaine use by both the intravenous and inhaled routes.⁹

Cocaine use induces both acute and chronic changes in the kidney. Chronic cocaine use triggers haemodynamic and structural changes mediated by an increased oxidative stress and stimulation of RAS that lead to mesangial matrix enlargement and increased tubulointerstitial fibrosis and atherogenesis. Cocaine has a potent vasoconstricting effect upon the vascular smooth muscle. The intimate mechanism is not exactly known, but it is known that calcium entry into the vascular smooth muscle cell, endothelin synthesis, and catecholamine production by the adrenal medulla are increased, with a simultaneous decrease in catecholamine uptake at the synapse. Cocaine may acutely induce renal ischaemic infarction through its potent vasoconstricting effect and by changes in platelet aggregation and an increased synthesis of thromboxan A₂.¹²⁻¹⁴

The reported case again shows that cocaine may cause serious renal disorders, and though the most common causes of renal damage are rhabdomyolysis and difficult to control high blood pressure, complications secondary to renal ischaemia may also occur. The spectrum of severe complications

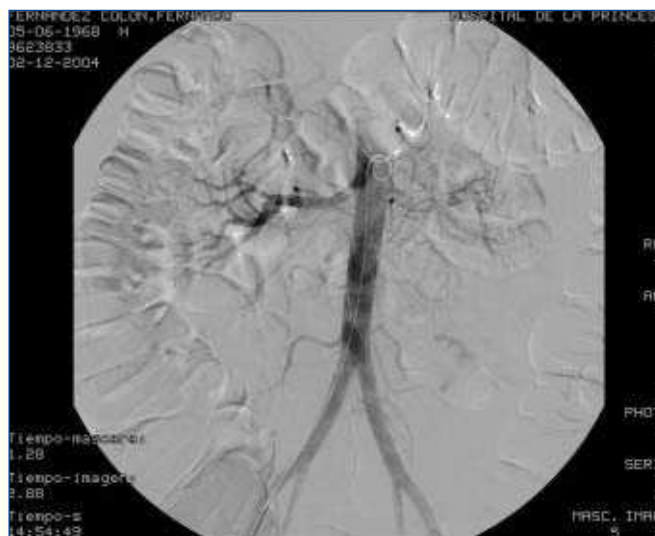


Figure 1. Abdominal scan. Infarction of almost the whole left kidney, and triangular ischaemic areas in the right kidney.

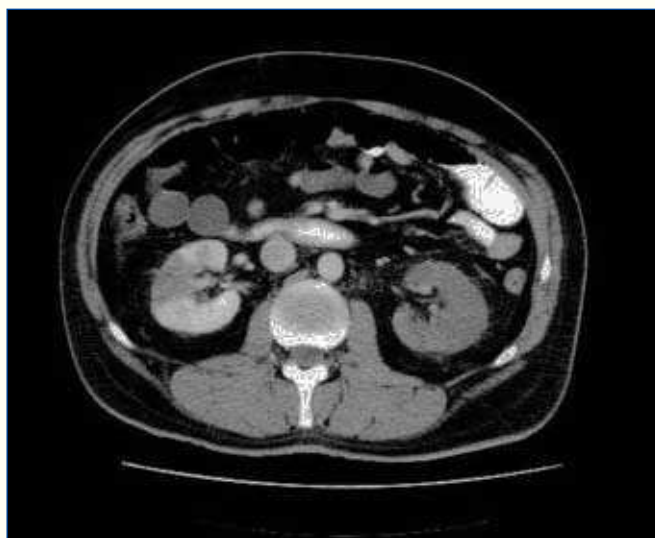

Figure 2. Selective renal arteriography. Multiple filling defects in the left renal artery due to thrombosis. Right renal artery is patent, with minimum peripheral defects.

associated to cocaine use is increasing, and we should remember that the kidney is one of the target organs affected. Studies should be conducted to elucidate the mechanisms of renal damage. The possibility of renal damage associated to cocaine should be suspected when faced with kidney disease of uncertain etiology in a patient with difficult to control HBP, renal infarction without other risk factors, or rhabdomyolysis from an unknown cause. This patient had elevated LDH and liver enzymes, but CPK levels remained at all times within the normal range, thus ruling out the presence of rhabdomyolysis. It should not be forgotten that cocaine addicts require multisystemic vigilance and that no specific cocaine antidote is currently available, so that the only effective tool is prevention.

REFERENCES

1. Nzerue CM, Hewan-Lowe K, Riley LJ Jr. Cocaine and the kidney: a synthesis of pathophysiologic and clinical perspectives. *Am J Kidney Dis* 2000; 35 (5): 783-95.
2. El-Hayek BM, Nogué S, Alonso D y Poch E. Rhabdomyolysis, compartment syndrome and acute kidney failure related to cocaine consume. *Nefrología* 2003; 23 (5) 469-70.
3. Marron B, Tuñón J, Santana H, Sanchís A, Albalade M, Ortiz A, Barat A, Casado S, Caramelo C. Crisis vascular por cocaína: recuperación del fracaso renal tras el abandono de la droga y control de la presión arterial. *Nefrología* 1999; Vol. 29. Número 2 190-193.
4. Rodríguez Jornet A, Andreu FJ, Mendoza D, Carvajal A, Sala M, Cervantes M, García M. Malignant arterial hypertension and acute renal failure caused by cocaine use. *Nefrología* 2000; 20 (6): 501-509.
5. Mendoza Asensi D, Rodríguez A, Carvajal A, Andreu FJ, Sala M, Cervantes M. Acute renal insufficiency associated to cocaine consumption. *Rev Clin Esp* 2004; 204 (4): 206-211.
6. Volcy J, Nzerue CM, Oderinde A, Hewan- lowe K. Cocaine-induced acute renal failure, hemolysis, and thrombocytopenia mimicking thrombotic thrombocytopenic purpura. *Am J Kidney Dis* 2000; 35 (1): E3.
7. Goodman PE, Rennie WP. Renal infarction secondary to nasal insufflation of cocaine. *Am J Emerg Med* 1995; 13 (4): 421-423.
8. Kramer RK, Turner RC. Renal infarction associated with cocaine use and latent protein C deficiency. *South Med J* 1993; 86 (12): 1436-1438.
9. Saleem TM, Singh M, Murtaza M, Singh A, Kasubhai M, Gnanasekaran I. Renal infarction: a rare complication of cocaine abuse. *Am J Emerg Med* 2001; 19 (6): 528-529.
10. Sharff JA. Renal infarction associated with intravenous cocaine use. *Ann Emerg Med* 1984; 13 (12): 1145-1147.
11. Huang CC, Kao WF, Yen DH, Huang HH, Huang CI, Lee CH. Renal infarction without hematuria: two case reports. *J Emerg Med* 2006; 30 (1): 57-61.
12. Mochizuki Y, Zhang M, Golestaneh L, Thananart S, Coco M. Acute aortic thrombosis and renal infarction in acute cocaine intoxication: a case report and review of literature. *Clin Nephrol* 2003; 60 (2): 130-133.
13. Bemanian S, Motallebi M, Nosrati SM. Cocaine-induced renal infarction: report of a case and review of the literature. *BMC Nephrol* 2005; 22: 6-10.
14. Gitman MD, Singhal PC. Cocaine-induced renal disease. *Expert Opin Drug Saf* 2004; 3 (5): 441-8.