

patients are still alive, with a follow-up between 2 and 6 years in haemodialysis, and one patient has undergone transplantation.

We conclude that patients with an apparent diagnosis of sepsis associated with primary peritonitis in PD, abdominal signs without remission and negative cultures, must have FSP considered as a diagnosis and early initiation of steroid treatment evaluated. This may save the life of a patient.

1. Junor B, Mc Millan M. Immunosuppression in sclerosing peritonitis. *Adv Perit Dial* 1993;9:187-9.
2. Rigby R, Hawley C. Sclerosing peritonitis: the experience in Australia. *Nephrol Dial Transplant* 1998;13:154-9.
3. Kawaguchi Y, Kawanishi H, Mujais S, Topley N, Oreopoulos NG. Encapsulating peritoneal sclerosis: definition, etiology, diagnosis, and treatment. *International Society for Peritoneal Dialysis Ad Hoc Committee on Ultrafiltration Management in Peritoneal Dialysis. Perit Dial Int* 2000;20(Suppl 4):43-55.
4. Nakayama M, Yamamoto H, Ikeda M, Hasegawa T, Kato N, Takahashi N, et al. Risk factors and preventive measures for encapsulating peritoneal sclerosis. *Jikei Experience* 2002. *Adv Perit Dial* 2002;18:144-8.
5. Selgas R, Bajo M, Cirugeda A, Del Peso G, Aguilera A, Gil F, et al. Diagnóstico precoz, prevención y tratamiento de los síndromes esclerosantes peritoneales. *Nefrología* 2003;23(Suppl 3):38-43.
6. Courtney A, Doherty C. Fulminant sclerosing peritonitis immediately following acute bacterial peritonitis. *Nephrol Dial Transplant* 2006;21:532-4.

I. Hendel, S. Mastrapasqua, C. Martínez, F. Martínez, O. Escobar

Nephrology Department. Neuquén Provincial Hospital, Argentina.

Correspondence: Sonia Mastrapasqua

Servicio de Nefrología. Hospital Provincial Neuquén. Argentina.

smastrapasqua@gmail.com

Aortic coarctation as a rare cause of hypertension in the elderly

Nefrología 2010;30(1):136-7

Dear Editor,

Hypertension in the elderly is mainly essential with coarctation of the aorta a secondary cause.¹ The median survival of patients with coarctation of the aorta is low: only 25% live past 50 years of age.^{2,3} Most cases are women, due to a lower tendency to develop atherosclerosis and hypertension.⁴

Below is the case of a male patient aged 83 who was admitted for surgery of the left paranasal squamous cell carcinoma, which appeared as a complication in a compressive cervical haematoma that required urgent tracheotomy. His background revealed longstanding refractory hypertension. A physical examination revealed a normal cardiopulmonary auscultation with distal pulses present on the upper limbs and diminished in the lower. Blood pressure in the upper right extremity was 182/81mmHg, significantly higher than the left side, where it was 130/75mmHg. The latter was similar to those of the lower extremities. Analytically, the data showed no renal secondary hypertension, thyroid or kidney disease. The echocardiogram revealed a significant hypertrophy of the left ventricle in septal location. A slight cardiomegaly and the inverted E sign (Figure 1) were observed on the radiograph which, together with the difference in blood pressure in both upper extremities, directed us towards a diagnosis of probable aortic coarctation.

Therefore, a chest CT was performed with contrast. This revealed, in the aortic arch, distal to the supra-aortic trunks, a poststenotic dilatation of a maximum of 3.7cm in diameter, compatible with aortic coarctation (Figure 2).

After assessing the clinical status, the tumour staging (T2, N2b, M0) and the high comorbidity of surgery, conservative treatment was chosen.

In conclusion, the diagnosis of aortic coarctation should always be discarded for any patient with refractory hypertension. A proper physical examination with palpation of distal pulses and measurement of blood pressure control between extremities is a good guide towards diagnosis.

1. Convens C, Vermeersch P, Paelinck B, Van den Heuvel P, Van den Branden F. Aortic coarctation: A rare unsuspected cause of secondary arterial hypertension in the elderly. *Catheterization and Cardiovascular Diagnosis* 1996;39:71-4.
2. Miro O, Jiménez S, González J, et al. Highly effective compensatory mechanisms in a 76-year-old man with a coarctation of the aorta. *Cardiology* 1999;92:284-6.

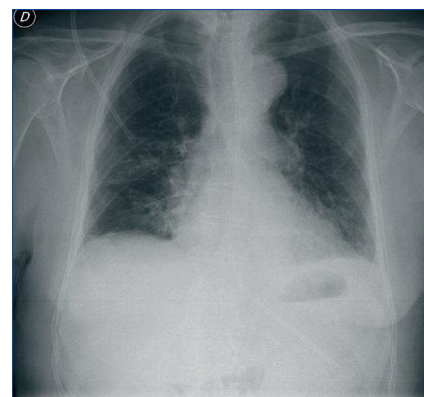


Figure 1. Chest Radiograph.

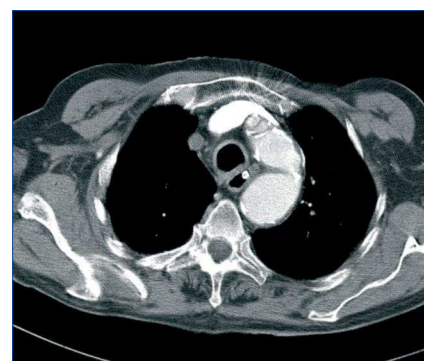


Figure 2. Thoracic CT.

3. Therrien J, Gatzoulis M, Graham T, et al. Canadian Cardiovascular Society Consensus Conference 2001 up date: recommendations for the management of adults with congenital heart disease: part II. *Can J Cardiol* 2001;17:1029-50.
4. Perloff JK. Coarctation of the aorta. Philadelphia: WB. Saunders, 1987;125-60.

S. Álvarez Tundidor, C. Ruiz-Zorrilla López, B. Gómez Giralda, A. Molina

Nephrology Department, Río Hortega University Hospital, Valladolid, Spain.

Correspondence:

Carlos Ruiz-Zorrilla López

Servicio de Nefrología. Hospital Universitario Río Hortega. Valladolid. Spain.
carlosruizzorrilla@hotmail.com

Partial recovery of obstructive kidney disease after 16 months on haemodialysis

Nefrología 2010;30(1):137-8

Dear Editor,

Urinary tract obstruction can cause a greater or lesser degree of kidney disease depending on its duration and severity. There is a lot of literature on the effects of kidney obstruction from an experimental point of view.^{1,3} However, there is less experience in humans, although the published works agree that the progressive deterioration of kidney function after removing the blockage is unusual in most patients, especially during the first year.

We present the case of a patient with kidney disease secondary to obstructive prostate adenoma who required regular haemodialysis treatment. After 16 months, he showed partial kidney function recovery, which was sufficient to allow dialysis treatment to be stopped.

A 50 year-old man with a history of prostate syndrome was admitted into emergency due to progressive deterioration of his general condition.

Physical examination revealed pale skin and mucous membranes and suprapubic dullness. The most relevant laboratory data showed Hb 5.9g/dL, urea/creatinine 425/19mg% and severe metabolic acidosis. The later immunological study (ANA, addition, etc) was normal or negative, proteinuria/24 hours 1.2g, and sediment with haematuria and pyuria with negative culture. An ultrasound showed a severe bilateral hydronephrosis with enlarged prostate, a bladder balloon with significant signs of postvoid residual bladder control. The patient brought an analytical examination performed 5 months earlier in which the only remarkable value was a creatinine of 1.6mg%.

The catheter was inserted and initial humoral regulation measurements were taken. Postobstructive polyuria was observed without improvement of kidney function. 2 packed red blood cell units were transfused and haemodialysis started. At 2 months the patient showed a marked clinical improvement with daily urine output of 1.5-2 litres, but with no evident improvement in the analytical results. A kidney biopsy was performed which showed the presence of 17 glomeruli of normal appearance with minor interstitial lymphocyte inflammatory accumulations, oedema of the tubular epithelium and isolated intratubular hyaline casts with a negative immunofluorescence study, all compatible with chronic moderate interstitial nephritis. Subsequently, retropubic prostate adenectomy was performed with a histological study of fibroadenoma nodular hyperplasia. A new kidney ultrasound was perfectly normal. After 16 months, residual clearances of 18ml per minute were observed in the analytical tests, so it was decided to stop dialysis. These values were stable 9 months after abandoning dialysis.

Obstructive nephropathy is a common cause of chronic kidney disease with a bimodal presentation affecting paediatric and elderly patients.⁴ There are few studies on the development of

obstructive nephropathy in humans, making it difficult to extrapolate experimental effects in clinical practice. In addition, the obstruction in humans is often incomplete and of a subacute or chronic course, and in most occasions it is very difficult to assess from the beginning. Generally the recovery of kidney function is observed between 7 and 10 days after the liberalisation of the urinary tract, although long recovery periods for kidney function have also been found.⁵ There are few studies relating to the prognosis of obstructive kidney disease that requires dialysis treatment.^{6,7} Ravanan et al⁸ has the largest number of patients, with analysis of the behaviour of kidney function after unblocking in an initial group of 104 adult patients with severe and chronic obstruction. 28 of them required treatment with haemodialysis despite the unblocking. After the third year, only 9 patients needed replacement therapy and another patient underwent a transplant. Kidney function improved during the first 3 months, and remained stable in most patients after 3 years. A small number of them observed no improvement after the unblocking treatment and were more likely to require long term haemodialysis.

Thus, despite the fact that obstructive nephropathy can be accompanied by the emergence of an apparent terminal chronic kidney disease, partial improvement in kidney function may be achieved after long periods, even when the patient requires replacement therapy.

1. Lewis HY, Pierce JM. Return of renal function after relief of complete ureteral obstruction of 69 day's duration. *J Urol* 1962;88:377-9.
2. Harris KP, Klahr S, Schreiner GF. Obstructive nephropathy: from mechanical disturbance to immune activation? *Exp Nephrol* 1993;1:198-204.
3. Schreiner GF, Harris KP, Purkerson ML, Klahr S. Immunological aspects of acute ureteral obstruction: immune cell infiltrate in the kidney. *Kidney Int* 1988;34:487-93.