

zoledronic acid, but the latter is not recommended when creatinine levels are above 3mg/dl. Some studies recommend using ibandronate for patients with renal failure, as it is less nephrotoxic, and some authors have even used ibandronate for patients with myeloma and renal failure caused by hypercalcaemia or nephrocalcinosis, recovering renal function and calcium levels. Haemodialysis must be started for oliguric renal failure cases. In our case, we started treatment with calcitonin and daily haemodialysis, but the patient's condition progressed rapidly, with multiple organ failure and respiratory distress due to tumoural calcinosis. In conclusion, we must highlight the need to closely monitor calcium levels in patients with multiple myeloma and start therapeutic measures early. For cases of malignant hypercalcaemia, we recommend bisphosphonates as be the most effective therapy, and for renal failure the least nephrotoxic drugs at an adjusted dosage.

1. Dimopoulos MA, Kastritis E, Rosnol L, Blade J, Ludwig H. Pathogenesis and treatment of renal failure in multiple myeloma. *Leukemia* 2008;22:1485-93.
2. Weber CK, Prummer O, Frickhofen N, Friedrich JM, Hoffmeister A, Merkle E, et al. Reversible metastatic pulmonary calcification in a patient with multiple myeloma. *Ann Hematol* 1996;72:329-32.
3. García-Sanz R, Mateos MV, San Miguel JF. Mieloma múltiple. *Med Clin (Barc)* 2007;129(3):104-15.
4. Triner WR, Birdwell MD. Severe Hypercalcemia presenting with multisystem organ failure. *Am J Emerg Med* 13(6):673-6.
5. Weide R, Koppler H, Antras L, Smith M, Chang E, Green J, et al. Renal toxicity in patients with multiple myeloma receiving zoledronic acid vs ibandronate: A retrospective medical records review. *J Can Res Ther* 2010;6:31-5.
6. Henrich D, Hoffmann M, Uppenkamp M, Bergner R. Ibandronate for the Treatment of Hypercalcemia or Nephrocalcinosis in Patients with Multiple Myeloma and Acute Renal Failure: Case Reports. *Acta Haematol* 2006;116:165-72.

J.G. Martínez Mateu, G.P. Losada González, M.A. Munar Vila, M. Uriol Rivera, G. Gómez Marqués, A.C. Tugores

Nephrology Department. Son Dureta Hospital. Palma de Mallorca, Balearic Islands, Spain

Correspondence: J.G. Martínez Mateu
Departamento de Nefrología. Hospital Son Dureta. Palma de Mallorca, Islas Baleares.
josefag.martinez@ssib.es

Rapidly progressive renal failure as the onset of an IgA nephropathy in an elderly patient

Nefrologia 2011;31(2):234-6

doi:10.3265/Nefrologia.pre2010.Nov.10661

To the Editor,

IgA nephropathy is the most frequent primary glomerulopathy in the world.^{1,2} It is often presented as macroscopic haematuria (generally preceded by a respiratory infection in the upper airways, especially in children), and persistent microhaematuria with mild proteinuria. Nephrotic syndrome and acute renal failure are the least common manifestations. We describe the case of an elderly patient that was diagnosed with IgA nephropathy, as a result of rapidly progressive renal failure (RPRF).

The patient was a 78-year-old man with a history of prostate carcinoma, treated with brachytherapy and radiotherapy check-ups every 6 months; carpal tunnel syndrome; right hip operation; and no known drug allergies.

His doctor had referred him to the emergency department due to tiredness and pain in his lower limbs. The patient's medical records indicated that he had suffered from nocturia on two occasions. The physical examination performed upon admission indicated that the patient's general condition was fair. He was conscious and aware of his surroundings. He did not have jugular

ingurgitation. Blood pressure was 135/85mm Hg, heart rate was 82 beats/min and SatO₂: 92%. The heart auscultation was rhythmic and pulmonary auscultation presented hypoventilation with isolated wheezing. The rest of the examination was normal.

The blood analysis (emergency department) was: creatinine: 2.9mg/dl (previous creatinine: 1.2mg/dl); potassium: 5.3mEq/l; haemoglobin: 11.5g/dl; haematocrit: 34.7%; remaining analyses, including venous gasometry and the coagulation test, were normal.

Systematic urine analysis showed: protein +++, blood ++. The sediment test showed haematuria, with isolated hyaline casts.

Chest X-ray and abdominal ultrasound did not show any pathological findings, the kidneys were of normal size, and the excretory tract was not dilated.

The subsequent blood analysis (common) showed: creatinine: 3.9mg/dl; urea: 181mg/dl; albumin: 2.7g/dl; total protein: 5g/dl; calcium: 6.9mg/dl; phosphorus: 8.1mg/dl; uric acid: 8.3mg/dl; sodium: 132mEq/l. 24-hour urine test found microalbuminuria, which was 620µg/min (normal range: 0-15µg/min). Other supplementary tests performed were normal (including viral serology, blood culture, tumour markers and thyroid hormones). The immunological test only showed a decrease in IgG of 574mg/dl (normal value: 751-1560) and an increase in C-reactive protein to 8.7mg/dl. No monoclonal peak was detected on the electropherogram.

The patient had been admitted to the internal medicine department, where progressive deterioration of the renal failure and oligoanuria were confirmed. Renal replacement therapy with haemodialysis was started. Given the rapidly progressive acute renal failure, a kidney biopsy was performed, finding the following: 12 glomeruli per cross-section, none of which was sclerotic.

We observed an expansion of the mesangial matrix with cellular proliferation in all of the glomeruli examined. On occasions, they affected the whole glomerulus, with pseudo-lobe images of the vascular tuft. There were fibrinoid necrosis foci in three glomeruli. The immunofluorescence showed intense positivity for IgA and C3, being negative for IgG and IgM. All the alterations found pointed to mild acute tubular necrosis with mixed inflammatory infiltration. The final diagnosis was IgA nephropathy with diffuse proliferation and fibrinoid necrosis foci (Figures 1 and 2).

As well as the support therapy with furosemide, enalapril was administered at 40mg/day, irbesartan 150mg/day and doxazosin 8mg/day. The biopsy findings lead to administration of three pulses i.v. of 1g of 6-methylprednisolone followed by prednisone at a dose of 1mg/kg/day. Diuresis was recovered with these measures, and kidney function gradually improved without the need for dialysis (creatinine reduced from 5.4mg/dl to 2mg/dl upon hospital discharge). Table 1 shows the follow-up and progress following hospital discharge.

There are mild forms of IgA nephropathy that can go unnoticed. In fact, in some autopsy and biopsy studies conducted to assess renal grafts, IgA nephropathy can be found in around 1.5% of the normal population.³ We describe the case of an elderly patient, who had no previous nephrology problems, who was diagnosed with IgA nephropathy following a kidney biopsy to confirm the cause of RPRF.

IgA nephropathy can appear at any age, but most frequently during the second and third decades of the life.⁴ It is possible that the prevalence in the elderly population is higher than has been described in the literature, possibly due to kidney biopsy indication. Persistent urinary alterations may attribute to other concomitant disorders (prostatitis, infections, etc.) and if a kidney biopsy is not performed, IgA

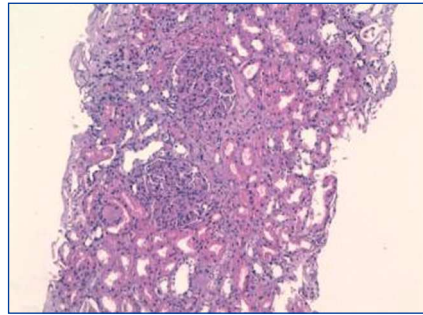


Figure 1. Haematoxylin and eosin (20x) with two glomeruli with intense diffuse proliferation of the capillaries.

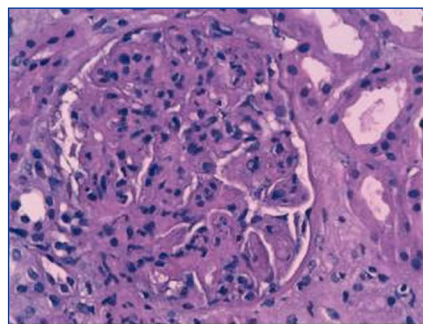


Figure 2. Haematoxylin and eosin (40x) with one glomerulus with intense diffuse proliferation and fibrinoid necrosis foci.

nephropathy may be underdiagnosed.⁵ Given our patient's history of prostate carcinoma, this nephropathy could have gone unnoticed if it had not been for obvious manifestations of acute renal failure.

Although this nephropathy is the most frequent one, an optimum treatment has not been well-established.⁶ Based on a review of 20 years experience, a third of these patients can develop end-stage chronic kidney disease (ECKD).⁷ Two studies have recently been published which have shown the benefits of co-administering corticoids (short-term) and angiotensin-converting enzymes (ACE) to treat IgA nephropathy with moderated histological lesions, with proteinuria above 1g/day.^{8,9} Combined immunosuppressant therapy is indicated in patients with rapidly progressive active severe disease and with histological evidence of active severe inflammation (crescents).¹⁰ In our case, we treated a patient with a history of rapidly progressive prostate cancer, with diffuse proliferation and fibrinoid necrosis foci and with no chronicity data. We decided to treat the patient with i.v. pulsed steroids followed by oral steroids with ACE and angiotensin II receptor antagonists. The patient progressed satisfactorily.

In summary, we have reported one more IgA case in an elderly patient, which probably would have gone unnoticed if the aggressive clinical symptoms had not started.

Table 1. 12-month clinical follow-up following hospital discharge

	10 days	2 months	3 months	6 months	1 year
Cr plasma (mg/dl)	2	1.6	1.7	1.5	1.4
P (O) (g/24 h)	5.7	1.67	0.71	(-)	(-)
Basic urine test		>40RBC/HPF	>35RBC/HPF	4-6RBC/HPF	1-3RBC/HPF
Blood pressure (mmHg)		130/70	124/72	123/67	110/70
Enalapril	40 mg/day	40 mg/day	20 mg/day	-	-
Telmisartan	80 mg/day	80 mg/day	80 mg/day	40 mg/day	-
Prednisona	80 mg/day	80 mg/day	70 mg/day	20 mg/day	2.5 mg/day

CR plasma: serum creatinine; P (O): proteinuria

1. Galla JH. IgA nephropathy. *Kidney Int* 1995;47(2):377-87.
2. Donadio JV, Grande JP. IgA nephropathy. *N Engl J Med* 2002;347(10):738-48.
3. Suzuki K, Honda K, Tanabe K, Nihei H, Yamaguchi Y. Incidence of latent mesangial IgA deposition in renal allograft donors in Japan. *Kidney Int* 2003;63:2286-94.
4. Clarkson AR, Woodroffe AJ, Bannister KM, Lomax-Smith JD, Aarons I. The syndrome of IgA nephropathy. *Clin Nephrol* 1984;21:7-14.
5. Heras M, Saiz A, Sánchez R, Fernández-Reyes MJ, Molina A, Rodríguez MA, et al. La biopsia renal en pacientes de 65 o más años: ¿existen diferencias en la indicación y en la histopatología respecto al resto de pacientes? *Rev Esp Geriatr Gerontol* 2010;45(6):316-9.
6. Appel GB, Waldman M. The IgA nephropathy treatment dilemma. *Kidney Int* 2006;69(11):1939-44.
7. D'Amico G. Natural history of idiopathic IgA nephropathy: role of clinical and histological prognostic factors. *Am J Kidney Dis* 2000;36:227-37.
8. Manno C, Torres DD, Rossini M, Pesce F, Schena FP. Randomized controlled clinical trial of corticosteroids plus ACE-inhibitors with long-term follow-up in proteinuric IgA nephropathy. *Nephrol Dial Transpl* 2009;24:3694-701.
9. Lu J, Zhang H, Chen Y, Li G, Jiang L, Singh AK, Wang H. Combination therapy of prednisone and ACE inhibitors versus ACE-inhibitors alone in patients with IgA nephropathy: a randomized controlled trial. *Am J Kidney Dis* 2009;53(1):26-32.
10. Ballardie FW, Roberts IS. Controlled prospective trial of prednisolone and cytotoxics in progressive IgA nephropathy. *JASN* 2002;13(1):142-8.

**M. Heras¹, A. Saiz², J. Pardo³,
M.J. Fernández-Reyes¹, R. Sánchez¹,
F. Álvarez-Ude¹**

¹ Nephrology Department. General Hospital. Segovia, Spain.

² Anatomical Pathology Department. Ramón y Cajal Hospital. Madrid, Spain.
Internal Medicine Department. General Hospital. Segovia, Spain.

Correspondence: M. Heras

Servicio de Nefrología. Hospital General. Ctra. de Ávila. 40002 Segovia. manuhebe@hotmail.com mherasb@saludcastillayleon.es

Cytomegalovirus-associated haemophagocytic syndrome in a kidney transplant patient

Nefrologia 2011;31(2):236-8

doi:10.3265/Nefrologia.pre2010.Nov.10639

To the Editor,

Haemophagocytic syndrome is a rare clinical condition characterised by a generalised, benign proliferation of histiocytes with significant haemophagocytic activity.¹⁻³ The aetiology of these symptoms can be separated into two groups: primary or genetically determined, or secondary: virus, bacteria, fungus, parasites, neoplasia, collagen, immunodeficiency or drugs.¹⁻⁷ Clinical symptoms include fever, hepatosplenomegaly, lymphadenomegaly, neurological symptoms, oedema and rashes.^{1,2,8,9} The most important laboratory findings are: pancytopenia, hypertriglyceridaemia, hypofibrinogenaemia, hyponatraemia, hypoproteinaemia, increased levels of hepatic enzymes, increased amount of LDH and ferritin, pleocytosis in LCR and defective activity of natural killer (NK) cells.¹⁰ The histological analysis found haemophagocytosis in the bone marrow, spleen and lymph nodes. There were no malignant findings and diagnosis was possible with 2% of haemophagocytic cells.¹⁻³ Haemophagocytic syndrome has a poor prognosis despite treatment, with an average survival of 2 weeks after the onset of the clinical symptoms. Survival can reach 60% at 5 years if there is an adequate response to treatment.^{11,12} Agents that interrupt histiocyte function and macrophage activation are therapeutic alternatives, such as etoposide, steroids, high-dose i.v. Ig, cyclosporine A, anti-thymocyte globulin, anti-TNF antibodies, and in some cases, bone marrow transplant.^{13,14}

We present the case of a 53-year-old man, subjected to kidney transplant, who came to the emergency department with fever, temperature

38.5°C over a 24-hour period, with shivers, mild diffuse abdominal pain, asthenia, anorexia, and a decrease in diuresis volume. The physical examination was normal and no important pathology was found from the tests performed at the emergency department: normal X-ray; normal blood and urine tests; negative blood and urine cultures; negative cytomegalovirus (CMV) early-antigen (at that time, CMV polymerase chain reaction (PCR) assays were not available in our hospital). The symptoms worsened, abdominal pain increased, and on the CT scan we observed dilated small bowel loops due possibly to ischaemia or infection. Given the findings and the worsening clinical symptoms, we performed an exploratory laparotomy, without observing anomalies. A coagulase-negative staphylococcus grew in the peritoneal fluid, which was treated with meropenem at 500mg every 12 hours. Following the intervention, the clinical symptoms improved despite having developed a post-operative paralytic ileus, which improved spontaneously. After a few days, the patient presented with fever again, and diarrhoea. There were initially no traces of blood, but he then presented with melaena, associated with neurological deterioration, hepatosplenomegaly and hepatic function alterations, anaemia and thrombocytopenia. New tests were requested: positive CMV early-antigen; CMV PCR assay above 100 000 copies/ml. Eso-Gastro-Duodenoscopy (EGD): infected oesophagus. Analytical tests showed: GOT/GPT: 135/156IU/l; LDH: 558IU/l; sodium: 130mEq/l, fibrinogen:133mg/dl, haemoglobin: 9.2 g/dl; and haematocrit: 26.8%; platelets: 48 000/ μ l with normal leukocytes (normal formula: 5500/ μ l), significant increase in triglycerides (738mg/dl), progressive deterioration of kidney function (creatinine around 4-5mg/dl). Normal haptoglobin, negative indirect Coombs test. Peripheral blood smear: few schistocytes with no reticulocyte. Bone marrow aspiration: compatible with haemophagocytic syndrome (Figure 1).