

**A) COMMENTS ON PUBLISHED ARTICLES**

**Correlation versus agreement; protein/creatinine ratio in spot urine and 24-hour urine protein**

*Nefrologia* 2013;33(1):134

doi:10.3265/Nefrologia.pre2012.Sep.11649

**To the Editor:**

I read with interest the article by Montero et al.<sup>1</sup> in *Nefrologia* 2012;32(4):494-50. This was an interesting study assessing the correlation between protein/creatinine ratio and 24-hour urine protein excretion. The authors assessed the strength of correlation by measuring the intra-class correlation coefficient (ICC) and the Spearman correlation coefficient (SCC).

I would argue that although the authors did construct a Bland Altman Plot, they did not address the agreement between protein/creatinine ratio and 24 hour urine protein excretion exhaustively. Montero et al. report the 95% limits of agreement graphically in the Bland-Altman plot but not numerically. The authors focus on the use of intra-class correlation coefficient which is often used to assess measurement error and reliability. However this measure is influenced by the amount of variation between subjects.<sup>2</sup>

When measuring urinary protein excretion, all methods are extremely likely to be correlated because they will all be attempting to measure the same construct i.e. the amount of protein in the urine, and so assessing whether the two measurements are correlated is not necessarily very informative. What we are more interested in as clinicians is whether or not we can use the two methods interchangeably or the agreement.

The standard deviation of the differences between measurements made by urine protein/creatinine ratio and 24 hour urine protein excretion provides a good index of the comparability of the two methods.<sup>2</sup> This leads to the 95% limits of agreement between the two measurements. Although

Montero et al. do report the 95% limits on the Bland-Altman plot, perhaps the authors could have reported the 95% limits of agreement for a specific number of thresholds of proteinuria for example <300mg, <3.5 grams or >3.5 grams individually which would be useful for clinicians trying to interpret spot urine protein/creatinine ratio. I worry that readers of this excellent study may be left focusing too much on correlations rather than agreement or concordance.

**Conflict of interest**

The authors declare that there is no conflict of interest associated with this manuscript.

1. Montero N, Soler MJ, Pascual MJ, Barrios C, Márquez E, Rodríguez E, et al. Correlation between the protein/creatinine ratio in spot urine and 24-hour urine protein. *Nefrologia* 2012;32(4):494-501.
2. Bland M, ed. *An Introduction to Medical Statistics*. Third Edition. London: Oxford Press; 2009.

**Donal Sexton**

Department of Nephrology. Clinical Research Facility. Cork (Ireland).

**Correspondence: Donal Sexton**

Department of Nephrology. Clinical Research Facility, Wilton, Cork, Ireland. donalsexton0@hotmail.com

**Response: Protein/creatinine ratio in spot urine versus**

**24-hour urine protein**

*Nefrologia* 2013;33(1):134-5

doi:10.3265/Nefrologia.pre2012.Oct.11764

**To the Editor:**

We want to thank Dr. Donal his very useful comments.<sup>1</sup> With great

interest we have reflected on them. He is absolutely right when he claims about the lack of comments from us about relevant data such as the numerical 95% limits of agreement in the Bland-Altman plot. The results for all the samples and for the specific thresholds are shown in the table. Of note that the limits of agreement are wide, reflecting the great variation of the differences.

Dr. Donal expressed certain misgivings regarding the use of intra-class correlation coefficient (ICC) and Spearman correlation coefficient (SCC) because, from his point of view, they assess the correlation rather than measuring the agreement. We agree that a strong correlation does not mean that the two methods agree. Regarding his remarks, first of all, a clarification of the basic concept of intraclass correlation coefficient seems worth mentioning. The ICC is viewed as a type of correlation, it assess the consistency or reproducibility of quantitative measurements made by different observers/methods measuring the same quantity or agreement between two numerical variables.<sup>2,3</sup> We think that in our study, it seems appropriate to show also the ICC results in addition to the Bland and Altman plot, as it has been done in previous publications. As the results are in agreement with the Bland and Altman plot, we surmise that this approach brings more information. However, as suggested we now added the 95% limits of agreement for clarifying the results.

**Conflict of interest**

The authors declare that there is no conflict of interest associated with this manuscript.

1. Sexton D. Correlation versus agreement; protein/creatinine ratio in spot urine and 24-hour urine protein. *Nefrologia* 2013;33(1):134.

**Table 1.** 95% limits of agreement in the Bland-Altman plot

24-h urine total protein excretion	All	<300	300-3499	>3500
<b>n</b>	159	60	77	22
<b>Mean difference</b>	252.7	- 10.9	- 85.8	2156
<b>Standard desviation (SD)</b>	1508	117	808	3208
<b>95% limits of agreement (mean difference ± 2 SD)</b>	(-2763, 3269)	(-245, 223)	(-1702, 1530)	(-4260, 8572)

- Müller R, Büttner P. A critical discussion of intraclass correlation coefficients. *Stat Med* 1994;13:2465-76.
- Shrout PE, Fleiss JL. Intraclass correlations: uses in assessing rater reliability. *Psychol Bull* 1979;86(2):420-8.

**Nuria Montero<sup>1</sup>, Sergio Mojal<sup>2</sup>, Julio Pascual<sup>1</sup>, María José Soler<sup>1</sup>**

<sup>1</sup> Servicio de Nefrología. Hospital del Mar. Barcelona. (Spain).

<sup>2</sup> Institut del Mar d'Investigacions Mèdiques. Barcelona. (Spain).

**Correspondence:** María José Soler

Servicio de Nefrología.  
Hospital del Mar. Passeig Marítim, 25-29.  
08003 Barcelona. (Spain).  
Msoler@parcdesalutmar.cat  
Msoler1@imim.es

**Comment on  
"Membranous  
glomerulonephritis  
associated with  
mieloperoxidase  
antineutrophil  
cytoplasmic antibody-  
associated  
glomerulonephritis"**

*Nefrologia* 2013;33(1):135-6

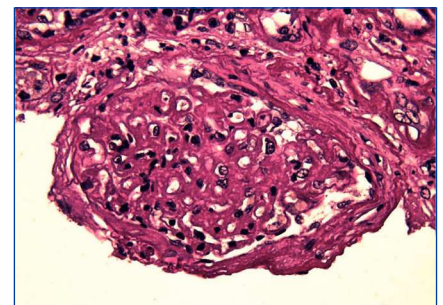
doi:10.3265/Nefrologia.pre2012.Sep.11692

**To the Editor:**

We read with interest the report of Dr. Guang-Yu Zhou, about a case of Mem-

branous Glomerulonephritis with crescentic transformation.<sup>1</sup> Acute crescentic transformation is a rare but well described event in patients with membranous glomerulonephritis.<sup>2</sup> The concomitant occurrence of a vasculitic glomerulonephritis and membranous nephropathy in the same patient is unusual.<sup>3</sup> We report herein our similar experience. A caucasian 66-year-old man presented for rapid declining of renal function. For nearly 10 years he was suffering from hypertension and for 4 years he is having paresthesias, muscle aches in the legs and significant reduction in muscle strength with an ataxic walking. This condition was interpreted as a mixed sensori-motor polyneuropathy. He performed therapy with prednisone and azathioprine, suspended for 1 year; six months before, laboratory tests showed a serum creatinine concentration 220µmol/L and a 24-h protein excretion 0,75g/d. On admission, the physical examination showed edema and severe hypertension; we detected a 24-h protein excretion 1.1g/d, Hb: 9.1g/dl, serum creatinine concentration 550.8µmol/L, the urinalysis 2 + urine protein and 1 + urine blood. ANCA determined in serum screening test by indirect immunofluorescence and other immunological tests, including anti-nuclear antibodies (ANAs), anti-Sm antibody, anti-dsDNA antibody, anti-cyclic citrullinated peptide (CCP) antibody, and anti-glomerular basement membrane (GBM) antibody were negative; serum complement and immunoglobulin levels were normal. Liver function tests and other routine parameters were within the normal range. There was no evidence of systemic lupus

erythematosus (SLE), infection, malignancy. For the clinical suspicion of a vasculitis leading to renal and neurological involvement, we performed a kidney biopsy. In the light microscopic visualization of renal tissue, 11 out of 17 glomeruli were globally sclerotic; the remaining glomeruli showed: diffuse, global and marked thickening of capillary wall (Figure 1), focal and diffuse sub-epithelial vacuolation; global and segmental sub epithelial deposits with sub-epithelial spikes, formation of 11 crescents (n° 3 cellular crescents, n° 1 fibrocellular crescent and n° 7 fibrotic crescents (Figure 2). Immunofluorescence examination displayed granular deposition of IgG, kappa and lambda light chains and a strong, diffuse and global granular staining along the glomerular capillary (subepithelial) walls. Therefore renal histology and laboratory examinations supported diagnosis of membranous GN with crescentic overlap. We diagnosed a vasculitis ANCA-negative and the patient was treated initially with methylprednisolone pulse 125mg/d for 3 days followed by prednisone 50mg/d, and i.v. cyclophosphamide 0.25g once every 21 days. Because of no sign of improvement shown 2 months later, we stopped the cyclophosphamide therapy and the patient started chronic haemodialysis treatment. Several authors have reported acute crescentic transformation in patients with primary membranous glomerulonephritis. Vasculitic or crescentic glomerulonephritis is rarely seen in membranous



**Figure 1.** PAS stain shows global and prominent thickening of the glomerular basement membranes, in the absence of evidence of cellular proliferation (PAS, x 400).